

SARCOIDOSIS AND COLON CANCER: A POSSIBLE ASSOCIATION

Anna Agnese Stanziola¹, Giovanna Caccavo¹, Nicolina De Rosa², Maria D'Amato¹, Rajeev Saggari³, Giuseppe Spadaro⁴, Antonio Ponticello¹

¹ Univ Naples Federico II, Dept Clin Med & Surg, Sect Resp Dis, Naples, Italy; ²Hosp Monaldi, AO dei Colli, Pathol Unit, Naples, Italy; ³Advanced Lung Disease Institute Banner University Medical Center-Phoenix, Univ. of Arizona, Phoenix; ⁴Department of Translational Medical Sciences and Center for Basic and Clinical Immunology Research (CISI), University of Naples Federico II, Naples, Italy

ABSTRACT. Sarcoidosis is a multisystem inflammatory disease characterized by non-caseating granulomas which mainly affect the pulmonary lymphatic system and lungs; although any organs can be interested. The association between sarcoidosis and cancer is still controversial, but many studies demonstrated an increased risk of cancer in patients with sarcoidosis, whereas few cases of sarcoidosis occurring after cancer have been reported. This report outlines and describes clinical, biologic and radiologic features of 3 patients with a history of surgical treatment and adjuvant chemotherapy for colon cancer, followed by a diagnosis of sarcoidosis some years later. The history of cancer and the lymph nodes positivity found through PET scan induced us to hypothesize a relapsing cancer disease. However, this hypothesis was not confirmed by the lymph nodes biopsy, which is the core method of diagnosis of sarcoidosis. (*Sarcoidosis Vasc Diffuse Lung Dis* 2018; 35: 376-380)

KEY WORDS: sarcoidosis, cancer, colon cancer

INTRODUCTION

Sarcoidosis is a multisystem chronic disease characterized by non-caseating persistent granulomatous inflammation, the cause of which remains largely unknown. This condition mainly affects the intrathoracic lymph nodes and the lungs, although any organ can be involved (1). Sarcoidosis is diagnosed after that other granulomatous disorders have been ruled out, as established by the American Thoracic Society (ATS), European Respiratory Society (ERS) and by the World Association of Sarcoidosis and Other Granulomatous Disorders (WASOG) (2).

A significant association between sarcoidosis and cancer is very recurrent in literature (3,4). In par-

ticular, sarcoidosis has been considered a condition at increased risk of lymphoproliferative disorder. In 1972 Brincker was the first one to provide documentary evidence on the relationship between sarcoid reactions and/or sarcoidosis and lymphoproliferative disorders (5). Therefore, the existence of a sarcoidosis-lymphoma syndrome was hypothesized (6). Similar to other autoimmune diseases in which the risk of lymphoma is increased, sarcoidosis local and systemic chronic inflammation may lead to malignancy just through an immunosuppressive status (3).

If the increased risk of cancer in patients with sarcoidosis is well established, few cases of sarcoidosis in patients with previous malignancy have been described in literature. Furthermore, a difference between systemic sarcoidosis and sarcoid reaction needs to be explained (7,8).

Sarcoid tissue reaction is an immunologic disorder related to cancer, resulting in the formation of epithelioid-cell granulomas. Such sarcoid reactions may occur in lymph-nodes draining areas housing a malignant tumor, in the tumor itself and in non-

Received: 19 March 2018

Accepted after revision: 24 September 2018

Correspondence: Giovanna Caccavo
University of Naples Federico II,
Dept Clin Med and Surg, Sect Resp Dis,
Via S. Pansini 5, 80131 Naples, Italy
E-mail: giov.caccavo@gmail.com

regional tissue too (9). It has been described in 4.4% of malignant carcinomas, in 7.3% of cases of non-Hodgkin lymphomas and in 13.8% of patients with Hodgkin disease. Anyway, the difference between idiopathic systemic sarcoidosis and sarcoid reactions is still controversial.

The aim of this study is to describe clinical, radiologic and biologic features of three patients who received a diagnosis of sarcoidosis after being affected from colon cancer.

CASE REPORT

The first case concerns a 64 years old woman who received a diagnosis of sigmoid adenocarcinoma (T3N1Mx; stage C2) when she was 50 years old. She underwent surgical treatment of proctosigmoidectomy followed by adjuvant chemotherapy with 5-fluorouracil and folinic acid (FUFA). Chemotherapy was withdrawn for its toxicity related to patient DPD (dihydropyrimidinase deficiency), an enzyme involved in 5FU catabolism. Consequently, as a second step, a therapy with Raltitrexed started. After 4 years of follow-up, a CT chest scan was performed and 2 lung lesions were detected: the first one, nodular (30x30 mm), involved the lower lobe of the right lung; the second one (10 mm) the lower lobe of the left lung, both suggestive for secondary lesions. As a consequence, chemotherapy with Raltitrexed and Oxaliplatin combined with Stereotactic Frame Radiotherapy was conducted for 6 months. A successive CT scan detected a volume reduction of the lesion of the right lung (27x20 mm) while the lesion of the left lung disappeared completely. Eight years of follow-up with PET/TC showed a variable uptake of right pulmonary lesion (SUV from 0 to 2.3), while in 2016 a PET/TC control showed an increased uptake of the right pulmonary lesion (SUV 20.1) with increased volume (41x22 mm), and the presence of two new nodular areas in the middle lobe (Figure 1).

To confirm the nature of the lesion, a biopsy of the right lung was performed and an "inflammatory non-necrotizing granuloma" was detected (Figure 2).

When the patient came to our observation, she was afebrile, her chest physical examination was normal and inflammatory markers (CRP and ESR) were low; serum and urinary calcium were normal, autoantibodies were negative and slight vitamin D

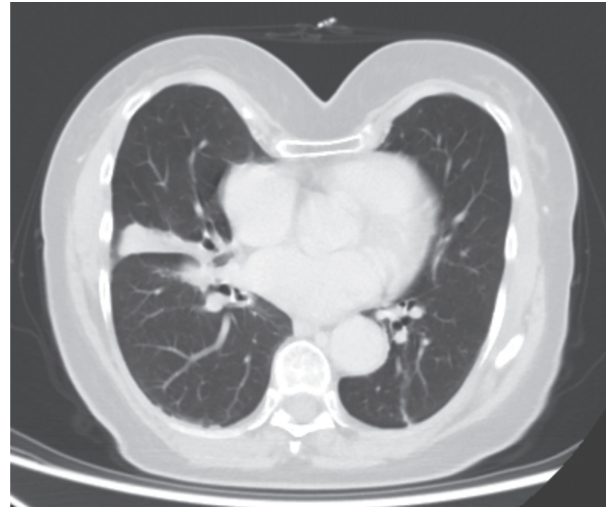

Fig. 1. First case: PET/TC showing the right pulmonary lesion

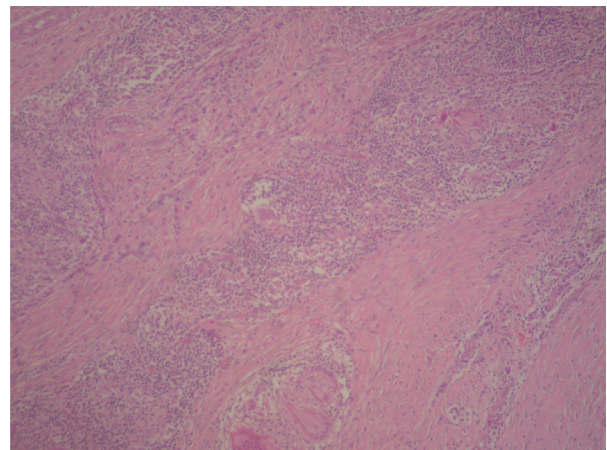


Fig. 2. First case: non-necrotizing coalescing granulomas of epithelioid cells with central multinucleated giant cells, peripheral lymphocytes and collagen

deficiency was found. Pulmonary function tests were normal (FEV1 95%th, FVC 99%th, FEV1 / FVC 80, DLCO 81%, DLCO / VA 90%), Echocardiography and ophthalmic examination were still in the normal range. The patient underwent a therapy with prednisone 25 mg daily, with a gradual dose reduction; after 4 months a PET scan had shown the SUV reduction (5.17) of the lesion of middle lobe.

The second case concerns a 70 years old woman, non-smoker, who underwent a surgical treatment of colosigmoidectomy for sigmoid colon adenocarcinoma, with a moderate grade of differentiation (G2)

associated to peritoneal carcinomatosis, in November 2012. Surgical treatment was followed by CHT (12 cycles) with Cetuximab (Erbix), a monoclonal antibody directed against Epidermal growth factor (EGFR), and with FOLFIRI (FOL - Folinic Acid, Fflourouracile, IRI - irinotecan), and then a maintenance therapy with Erbitux. In January 2015, a total body CT scan revealed an increased volume of hilar and mediastinal lymph nodes with elevated uptake at PET scan (SUV 22), indicative for disease progression (Figure 3).

Thus, the patient underwent first fibrobronchoscopy and then video thoracoscopy with lymphadenectomy (station 4R). Histology suggested non-caseating chronic granulomatous inflammatory process (simil sarcoidosis) (Figure 4).

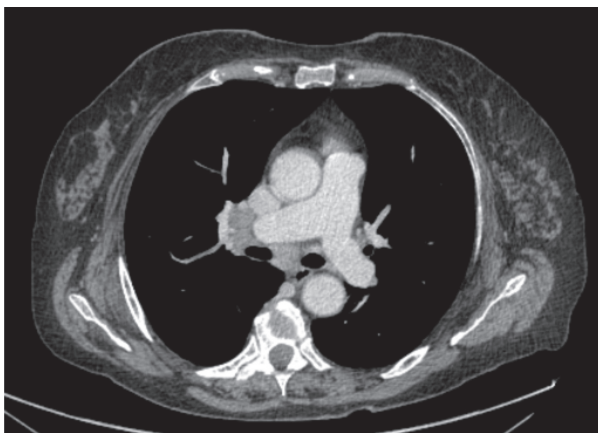

Fig. 3. Second case: total body CT showing the increased volume of hilar and mediastinal lymph nodes

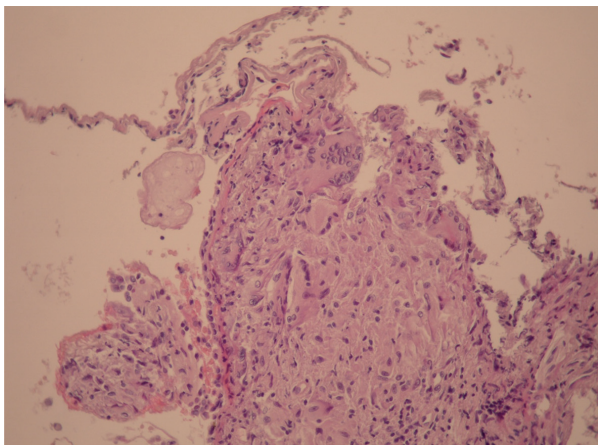


Fig. 4. Second case: endobronchial biopsy showing epithelioid granulomas with giant cells in the lamina propria

A few weeks later, the patient suffered from vertebral fractures (D6, D7, D10 e L2), and was admitted in a hospital where she remained for several months; one year after the diagnosis of sarcoidosis she came to our observation; physical chest examination and functional pulmonary tests resulted in the normal range (FEV1 107% th, FVC 105% th, FEV1/FVC 83, DLC0 84% th, DLCO/VA 95% th); urinary and plasma calcium levels were normal too. Another PET/CT scan was performed and a reduction in mediastinal lymph nodes uptake (SUV <5) was observed. Therefore, as clinical presentation was asymptomatic and CT/PET scan showed a reduction in lymph nodes uptake, we opted for a follow up of the disease ("wait-and-see" protocol).

The third case concerns a 58 years old woman, ex-smoker, who was diagnosed with sigmoid-colon carcinoma and underwent surgical treatment of sigmoidectomy in 2006. Five years later, during the follow-up in September 2011, a total body PET/CT scan detected some small pulmonary parenchymal nodules (5 mm) indicative for metastasis, enlarged mediastinal lymph nodes (max 15 mm) and multiple nodular lesions in the spleen (25 mm, SUV max 7.1), in absence of other sites of uptake (Figure 5).

Thus, a splenic EUS-FNA was performed and a non-necrotizing granulomatous giant cells process suggestive for sarcoidosis was detected (Figure 6).

The patient came to our observation with a normal physical examination, negative autoantibodies, normal pulmonary function tests (FVC 138%th, FEV1 131%th, FEV1/FVC 82), walking test, arterial gas analysis (pO₂ 89 mmHg; pCO₂ 39 mmHg,

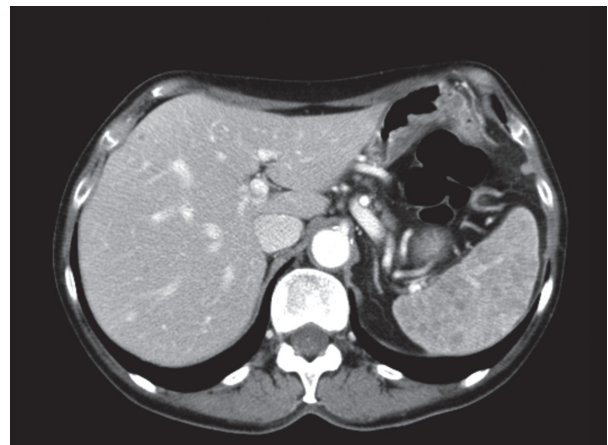


Fig. 5. Third case: PET/CT showing multiple nodular lesions in the spleen

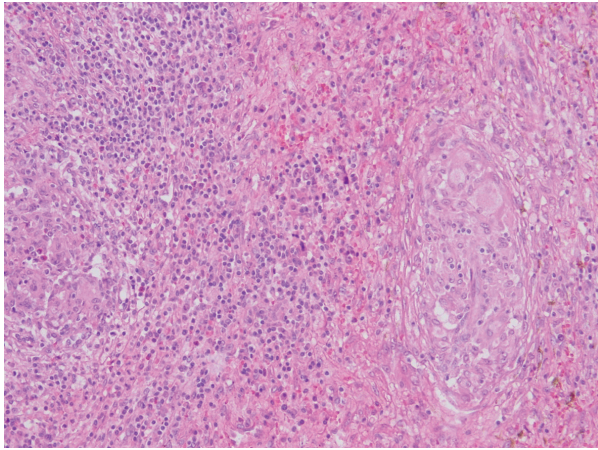


Fig. 6. Third case: non-necrotizing granulomatous giant cells in the spleen

pH 7.43), serum and urinary calcium and vitamin D levels and underwent a fibrobronchoscopy with BAL, which showed a moderate increase of neutrophil granulocytes and of CD4/CD8 rates. The patient was assigned therapy with Prednisone 37.5 mg/daily for two months with progressive dose reduction up to 1 year. Following PET/TC scans performed during the follow-up didn't show any uptake.

The 3 patients are now regularly followed in our "Pulmonary Rare Diseases" Ambulatory, where they undergo pulmonary function tests every 4 months, imaging tests yearly, and periodic oncologic screenings.

DISCUSSION AND CONCLUSIONS

In literature there are a few reports which describe an association between sarcoid-like reactions and colon cancer.

Fiorelli et al. (10) described a case report in which a sarcoid-like reaction of mediastinal and hilar lymph nodes was found 5 years after surgical treatment of ileocecal resection plus adjuvant chemotherapy for colon adenocarcinoma. During oncologic follow-up, a CT/PET chest scan showed multiple lymph nodes with elevated FDG uptake indicative for cancer relapse.

Shima et al. (11) described a case report in which there was a sarcoid-like reaction in the spleen 1 year and a half after sigmoid colon cancer resection and adjuvant chemotherapy.

Sarcoid-like reactions were detected during ileocecal resection for colon adenocarcinoma in regional lymph nodes without metastasis (12,13,14) or in stroma surrounding cancer (15,16). Pathogenesis of cancer associated with sarcoid-like granulomas is still unknown. It may develop as a reaction against tumoral cells, as a tissutal reaction against neoplastic embolism of lymphatic or vascular system, and as an immunologic reaction caused by substances released from tumoral cells.

Systemic sarcoidosis following diagnosis of cancer is less common in literature.

In a retrospective study, Grados et al. (17) identified 12 patients who developed sarcoidosis after suffering from solid neoplasms from 2009 to 2014, particularly after breast and colon-rectal cancer. Sarcoidosis was detected after about 34 months cancer had been diagnosed, and in all cases diagnosis was histologically confirmed (lymph nodes, skin and bone biopsy) to exclude cancer relapse. About one half of patients did not receive any treatment while the other 50% received steroidal treatment.

In a French retrospective study, London et al. (18) studied 14 patients with sarcoidosis occurring after a history of lymphoma and 25 patients were identified with a review of literature. Diagnosis of sarcoidosis was histologically confirmed about 18 months after the diagnosis of lymphoma. Forty-one percent of patients had received a first line treatment with oral steroids and hydroxychloroquine, and only 2 patients received a second line treatment, one with cyclophosphamide and methotrexate for neurologic involvement, another one with azathioprine for cardiac involvement.

The difference between idiopathic systemic sarcoidosis and sarcoid reactions is still a clinic and histopathologic dilemma (19).

Pulmonary granulomas may develop after the administration of interferon gamma (20,21), anti-TNFalfa in autoimmune diseases (22), vaccination with BCG (23) and immunotherapy (24-26).

We can not exclude a relationship between sarcoid granuloma and chemotherapy (therapy with monoclonal antibodies). Therefore, in literature only one case of sarcoidosis associated with chemotherapy for colorectal cancer is found (FOLFOX protocol), and it healed after steroid therapy. However, this lacks histological confirmation (27).

Differential diagnosis between metastasis and sarcoid reactions is not easy using CT or PET scan

alone (28,29). Actually, PET scan is crucial in the follow-up of sarcoidosis, as it evaluates the activity of the disease and directs therapeutic choices, but it can not be considered the most important procedure for the diagnosis of the disease. During the oncological follow-up, a PET scan detecting an increased uptake of mediastinal lymph nodes requires bioptic procedures as lymph nodes TBNA to confirm the diagnosis (30).

As we experienced during oncologic follow-up, the presence of pulmonary nodules suggestive for metastasis always requires a histologic confirmation, because sarcoidosis is considered a “great mime”, a pathology which may affect every organ by simulating the disease affecting that organ, above all cancer.

We described cases affecting only women, with a pulmonary or lymph-nodal presence in the first two cases, and splenic presence in the other case, but we cannot give importance to adjuvant chemotherapy because different protocols were employed.

The three cases are not significant for a statistical analysis but, these are the only three cases of sarcoidosis occurring after colon cancer observed over the last 6 years in Naples, in our center. As patients who suffered from sarcoidosis often undergo a “wait and see” protocol, it may be useful to create a national and international register which helps identify cases of sarcoidosis occurring after colon cancer, especially in Northern European countries, where the prevalence of the disease is higher. Could sarcoidosis and colon cancer be associated? We do not know, but sarcoidosis remains a strange disease either for clinical presentation, or for its evolution and therapy response.

REFERENCES

- Iannuzzi MC, Rybicki BA, Teirstein AS. Sarcoidosis. *New England Journal of Medicine* 2007; 357(21): 2153-2165.
- Hunninghake GW, et al. Statement on sarcoidosis. *American Journal of Respiratory and Critical Care Medicine* 1999; 160(2): 736-755.
- Tana C, et al. Immunopathogenesis of Sarcoidosis and Risk of Malignancy: A Lost Truth? *International Journal of Immunopathology and Pharmacology* 2013; 26(2): 305-313.
- Bonifazi M, et al. Sarcoidosis and Cancer Risk Systematic Review and Meta-analysis of Observational Studies. *Chest* 2015; 147(3): 778-791.
- Brincker H. Sarcoid reactions and sarcoidosis in Hodgkin's disease and other malignant lymphomata. *Br J Cancer* 1972; 26(2): 120-3.
- Brincker H. The sarcoidosis-lymphoma syndrome. *Br J Cancer* 1986; 54(3): 467-73.
- Arish N, et al. Characteristics of Sarcoidosis in Patients with Previous Malignancy: Causality or Coincidence? *Respiration* 2017; 93(4): 247-252.
- Kiess AP, et al. Sarcoid in Cancer Patients: Clinical Characteristics and Associated Disease Status. *Sarcoidosis Vasculitis and Diffuse Lung Diseases* 2015; 32(3): 200-207.
- Brincker H. Sarcoid Reactions in Malignant-Tumors. *Cancer Treatment Reviews* 1986; 13(3): 147-156.
- Fiorelli A, et al. Mediastinal sarcoid-like reaction after colon adenocarcinoma resection. *Asian Cardiovascular and Thoracic Annals* 2015; 23(1): 82-84.
- Shima T, et al. Sarcoid reaction in the spleen after sigmoid colon cancer resection: a case report. *Surgical Case Reports* 2016; 2.
- Fujii T, et al. Adenocarcinoma of Ascending Colon Associated with Sarcoid Reaction in Regional Lymph Nodes. *Case Reports in Gastroenterology* 2010; 4(1): 118-123.
- Nozoe T, Matsumata T, Sugimachi K. Carcinoma in villous adenoma of ascending colon associated with sarcoid reaction in the regional lymph nodes. *Journal of Clinical Gastroenterology* 1999; 28(4): 377-379.
- Mohamadnejad M, et al. Adenocarcinoma of the colon associated with sarcoidosis. *MedGenMed: Medscape general medicine* 2003; 5(1): 6-6.
- del Arco CD, Acenero MJF. Sarcoid reaction: a rare occurrence associated to colon adenocarcinoma (case report and literature review). *Journal of Gastrointestinal Oncology* 2016; 7(4): E72-E76.
- Coyne JD. Colonic carcinoma with granulomatous (sarcoid) reaction. *Journal of Clinical Pathology* 2002; 55(9): 708-709.
- Grados A, et al. Sarcoidosis Occurring After Solid Cancer: A Nonfortuitous Association Report of 12 Cases and Review of the Literature. *Medicine* 2015; 94(28).
- London J, et al. Sarcoidosis occurring after lymphoma: report of 14 patients and review of the literature. *Medicine (Baltimore)* 2014; 93(21): e121.
- Tchernev G, et al. Sarcoidosis exclusion criteria: the “simple truth” for a “complicated diagnosis”. *J Biol Regul Homeost Agents* 2015; 29 (1 Suppl): 5-9.
- Teh A, et al. Bone marrow sarcoidosis associated with long-term interferon- treatment for multiple sclerosis. *Clinical Case Reports* 2016; 4(11): 1038-1040.
- Waltschew A. Cutaneous sarcoidosis after treatment with interferon for hepatitis C. A not entirely rare but often overlooked reaction. *Pathologie* 2016; 37(2): 184-186.
- Ishiguro T, et al. Development of sarcoidosis during etanercept therapy. *Internal Medicine* 2008; 47(11): 1021-1025.
- Osborne GEN, Mallon E, Mayou SC. Juvenile sarcoidosis after BCG vaccination. *Journal of the American Academy of Dermatology* 2003; 48(5): S99-S102.
- Cotliar J, et al. Pembrolizumab-associated sarcoidosis. *JAAD Case Reports* 2016; 2(4): 290-293.
- Reuss JE, et al. Sarcoidosis in the setting of combination ipilimumab and nivolumab immunotherapy: a case report & review of the literature. *Journal for Immunotherapy of Cancer* 2016; 4.
- Danlos FX, et al. Nivolumab-Induced Sarcoid-Like Granulomatous Reaction in a Patient With Advanced Melanoma. *Chest* 2016; 149(5): E133-E136.
- Choi JH, et al. Sarcoidosis associated with oxaliplatin-based chemotherapy for colorectal cancer. *Case reports in oncological medicine* 2014; 2014.
- Koo HJ, et al. Evaluation of Mediastinal Lymph Nodes in Sarcoidosis, Sarcoid Reaction, and Malignant Lymph Nodes Using CT and FDG-PET/CT. *Medicine* 2015; 94(27).
- Chowdhury FU, et al. Sarcoid-like reaction to malignancy on whole-body integrated F-18-FDG PET/CT: prevalence and disease pattern. *Clinical Radiology* 2009; 64(7): 675-681.
- Lequoy M, et al. Sarcoidosis Lung Nodules in Colorectal Cancer Follow-Up: Sarcoidosis or Not? *American Journal of Medicine* 2013; 126(7): 642-645.