

SARCOIDOSIS WITH ANKYLOSING SPONDYLITIS: CHANGING THERAPEUTIC LANDSCAPE

Chinnabbathini Deva Rahul, Rahul Kumar Sharma, Deepak Talwar

Metro Centre for Respiratory Diseases, Metro Multispecialty Hospital, Noida, UP, India

ABSTRACT. Sarcoidosis is an inflammatory multisystem disease which rarely may coexist in patients with other autoimmune disease like ankylosing spondylitis (AS). The presence of such as association causes diagnostic and management dilemmas as sarcoidosis has been reported to develop in patients of AS treated with tumour necrosis factor alpha (TNF- α) inhibitors. We describe a 49-year-old male with ankylosing spondylitis and histologically proven sarcoidosis who was treated with infliximab and improved. (*Sarcoidosis Vasc Diffuse Lung Dis* 2018; 35: 285-288)

KEY WORDS: sarcoidosis, ankylosing spondylitis, TNF- α inhibitor, infliximab

INTRODUCTION

Development of sarcoidosis in patients with ankylosing spondylitis (AS) has been rarely reported in literature. This association is believed to be either coincidental or the result of underlying immune dysregulation, predisposing an individual to develop both diseases over a variable period of time (1). Patients treated with tumour necrosis factor alpha (TNF- α) inhibitors for AS have also been shown to develop sarcoidosis (2). We here report a case suffering from AS for 35 years, and consequently diagnosed with thoracic sarcoidosis, which led to change in his therapeutic management and use of infliximab as primary agent for both the disease.

CASE REPORT

A 49-year-old non-smoker male, known case of AS (HLA B27+ve) since past 35 years, treated

previously with hydroxychloroquine, sulfasalazine, methotrexate and non-steroidal anti-inflammatory drugs (NSAIDs), presented with dry cough and progressive exertional dyspnea since last 18-20 months. There was history of low-grade fever on and off. He was evaluated at some other center by chest x-ray and CT chest (Figure 1a, b&c) and given antitubercular (ATT) treatment on radiological basis. There was no clinical or radiological improvement with repeat CT chest after 2months showing insignificant change in parenchymal shadows and increase in size of mediastinal lymph nodes (Figure 1d), for which he was referred to our centre.

On examination, he had stable vitals with no respiratory distress. General physical examination revealed stooping posture due to kyphosis with marked reduction in spinal movements as well as chest expansion (2 cm). AS activity was assessed by Bath ankylosing spondylitis disease activity scale (BASDAI) and found to be suboptimally controlled (BASDAI score 6). The predominant symptoms included pain in axial joints (neck, back and hips), morning stiffness and generalized fatigue. Rest of systemic and respiratory examination was normal. Routine laboratory tests including complete blood counts, kidney and liver functions were normal. Autoimmune profile including Rheumatoid Factor (RF), antinuclear

Received: 4 August 2017

Accepted after revision: 19 August 2018

Correspondence: Dr. Rahul Kumar Sharma

Metro Centre for Respiratory Diseases,

Metro Multispecialty Hospital, Sector 11, Noida, UP, India

Tel. 9810743877

E-mail: dr.rahulksharma@gmail.com

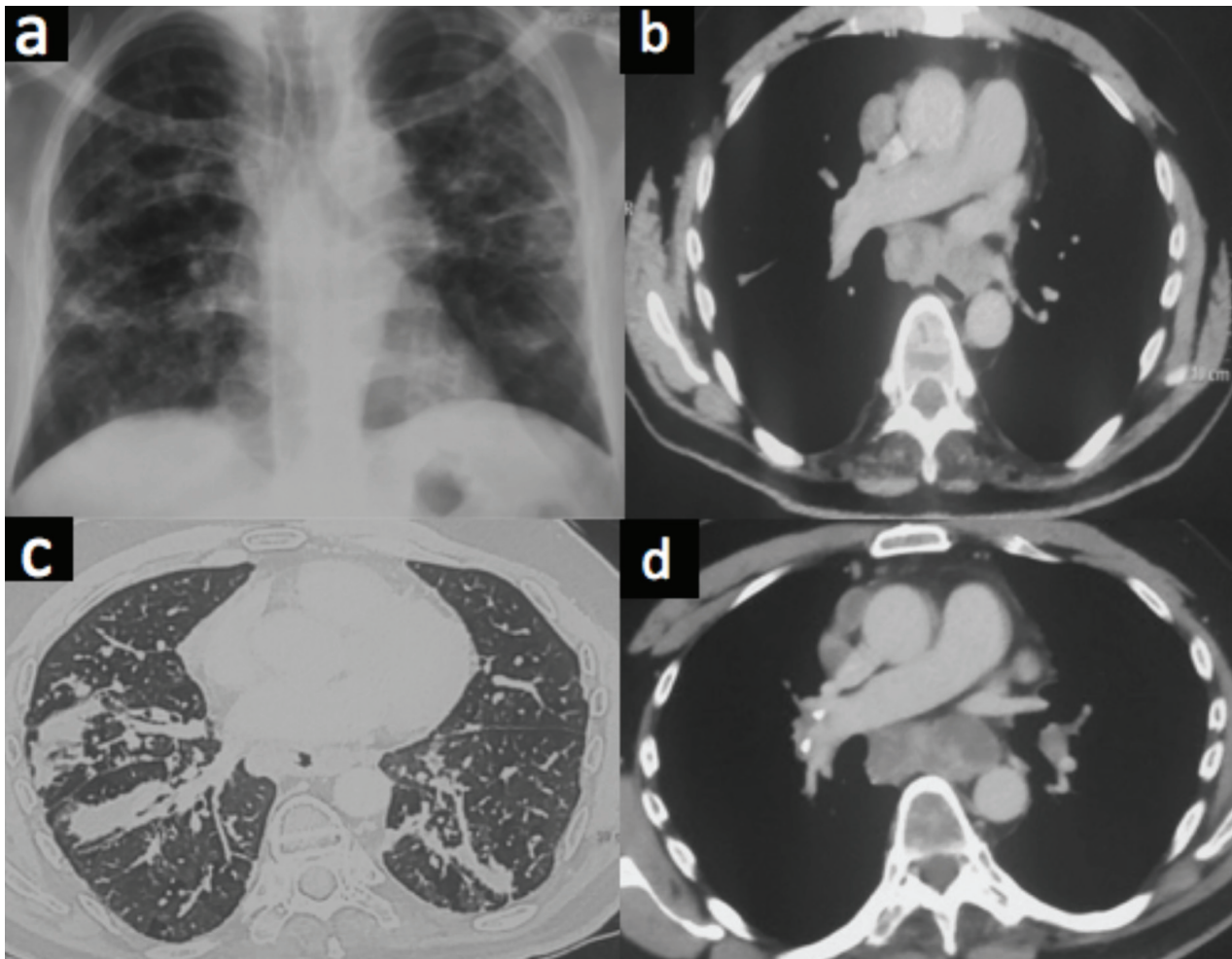


Fig. 1. X-ray chest showing bilateral reticulonodular opacities with mediastinal widening. b) CT chest showing enlarged subcarinal lymphadenopathy. c) High resolution CT showing bilateral reticulonodularity in bronchovascular distribution with septal nodularity. d) Repeat CT showing increase in the size of subcarinal lymph nodes as compared to Figure 2b

antibodies (ANA) and extractable nuclear antigens (ENA) were negative. Mantoux and TB gold tests were negative. His serum angiotensin converting enzyme (ACE) levels were raised (84 U/L, normal up to 51 U/L). Lung function tests revealed moderate restrictive ventilation defect with forced vital capacity (FVC) 1.47 L. He was administered depot preparation of methylprednisolone (80 mg every 4 weeks for 3 months) along with NSAIDs with marginal relief only. In view of persistent symptoms, PET CT scan was planned, which revealed FDG avid multiple large mediastinal lymph nodes and bilateral pulmonary nodules (Figure 2 a&b). Subsequently he underwent endobronchial and transbronchial node biopsy using EBUS. Histopathology revealed

non-caseating granulomas in lymph nodes as well as endobronchial mucosal biopsy. Workup for tuberculosis (AFB smear, GenXpert and TB cultures) and lymphoma (immunohistochemistry) was negative confirming diagnosis of sarcoidosis.

As part of therapeutic management for both AS and sarcoidosis, patient was started on infliximab (200 mg every four weeks). At 3 months, there was a significant improvement in AS symptoms of morning stiffness, back pain and tiredness with associated decrease in BASDAI score (2.6). There was a marked improvement in respiratory symptoms also along with regression in size of mediastinal lymph nodes and parenchymal lesion on CT Chest (Figure 2c & d) and improvement in PFT parameters

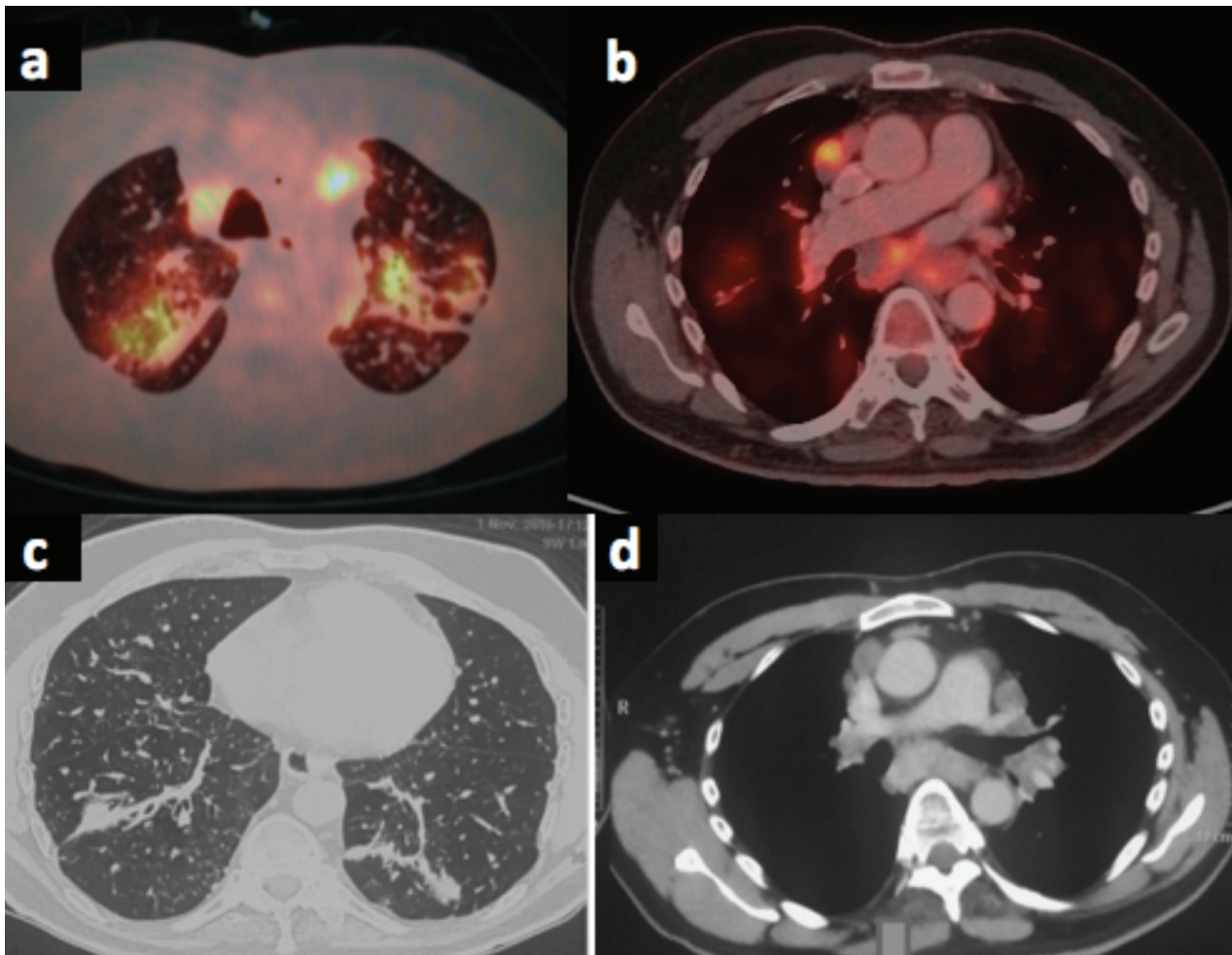


Fig. 2. a) PET showing FDG avid multiple bilateral pulmonary nodules in bronchovascular distribution. b) PET showing multiple FDG avid mediastinal lymph nodes. c) & d) High resolution CT showing improvement in lung lesions as compared to Figure 1c and regression in the size of lymph nodes as compared to Figure 1d

(FVC 1.69L). On further follow-up, he continues to be asymptomatic on infliximab therapy.

DISCUSSION

Ankylosing spondylitis and sarcoidosis coexistence has been rarely reported in literature, with no clear consensus whether it occurs as coincidence or co-occurrence (3). Coincidence of two diseases which are prevalent in community is a possibility; but both AS and sarcoidosis are uncommon in India, hence co-occurrence of these two diseases appears more likely. This has been postulated due to a common mechanism underlying immunopathogenesis

with both diseases being linked to Th1 CD4+ lymphocytes; and overlapping clinical presentation like sacroiliitis. In an individual, AS with sarcoidosis may present as either sarcoidosis developing in a known patient of AS, or patient of sarcoidosis developing AS, or patients of AS given anti-TNF- α therapy, developing sarcoidosis like reaction (SLRs) (4).

Our patient developed sarcoidosis after more than 30 years of being diagnosed and treated for HLA B27 positive AS but not with TNF- α inhibitor. Nearly 2 dozen similar cases have been previously reported in literature. Most of these cases were males with median age of about 41 years similar to our patient. However in all such cases, HLA B27 positive AS patients developed sarcoid related sac-

roilitis followed by pulmonary sarcoidosis, while our case developed thoracic sarcoidosis with mediastinal and parenchymal involvement with no evidence of sacroilitis (5).

Steroids are the drug of choice in progressive sarcoidosis with TNF- α inhibitors being the second line of management in refractory cases. TNF- α is pro-inflammatory mediator contributing significantly in pathogenesis of auto-immune disorders. TNF- α inhibitors are also recommended in treatment of AS not responding to NSAIDs. Recent guidelines strongly discourage the use of long-term steroids for these patients. Slow acting drugs(SADs) e.g. sulfasalazine is recommended as second line agent in patients with AS who either refuse or are unsuitable for TNF- α inhibitors. Etanercept has been used in the past to treat AS but sarcoid like reactions have been reported with it. Thirty seven cases of sarcoid granulomatous reactions(SLR's) developing in patients on anti TNF- α drugs are cited in literature (6).

In this case, both the diseases were progressive and active requiring therapeutic interventions. Therapeutic implications in this case are complex due to varied management strategies and drug interactions. Though AS management warranted use of TNF- α inhibitors, their propensity to cause SLR may preclude its use in this patient with known sarcoidosis. Similarly steroids are not advocated in treatment of AS though being the first line for sarcoidosis (7). Moreover, pulmonologists are not well versed with use of biologicals for sarcoidosis, though newer evidence is clearing confusion about their use, particularly with infliximab. In a prospective open labelled study on 56 patients of refractory sarcoidosis, Vorsellers et al demonstrated efficacy of infliximab therapy with beneficial response in 79% patients, partial response in 17% and no response in only 4% of patients (8). Saleh et al similarly found infliximab to be effective in management of 12 patients with sarcoidosis (9). Case report of successful treatment of both diseases coexistent in a single patient by infliximab are promising (10). Both infliximab and adalimumab have been shown to be effective in management of AS as well as progressive sarcoidosis, suggesting class effect (10). Keeping in consideration the promising role of infliximab in both diseases on literature review, TNF- α therapy was initiated in our patient.

An important prerequisite for use of infliximab is to rule out latent or active tuberculosis, which becomes difficult in Indian scenario. Our case was also treated empirically with ATT initially. Evaluation with FOB EBUS showing negative mycobacterial cultures and negative IGRA TB test allowed us to rule out TB before using TNF- α inhibitor (infliximab). The clinical and radiological improvement along with a decrease in activity of AS, on infliximab, in our patient shows a promising future for use of these biological in such complicated scenarios.

CONCLUSION

This case highlights the importance of changing therapeutic landscapes in management of autoimmune related lung diseases with ways to use newer biological agents, which have entered into the management armamentarium of pulmonologists. Further it strengthens the platform for possible use of such agents for effective management of sarcoidosis coexisting with other diseases as in this case.

REFERENCES

1. Abouzahir A, El Maghraoui A, Tabache F et al. Sarcoidosis and ankylosing spondylitis. A case report and review of the literature. *Ann Med Interne* 2002;153:407-10.
2. Farah RE, Shay MD. Pulmonary sarcoidosis associated with etanercept therapy. *Pharmacotherapy* 2007; 27: 1446-8.
3. Stucki G, Von Felten A, Speich R, Michel BA. Ankylosing spondylitis and sarcoidosis-coincidence or association? Case report and review of the literature. *Clin Rheumatol* 1992;11:436-9
4. Kremer P, Gallinet E, Benmansour A, Despau J, Toussiro E, Wendling D. Sarcoidosis and spondyloarthropathy - Three case reports. *Rev Rheum* 1996;63:405-11.
5. Smith G, Brownell I, Sanchez M, Prystowsky S. Advances in the genetics of sarcoidosis. *Clin Genet*, 2008 ;73: 401- 412,
6. Tong D, Manolios N, Howe G, Spencer D. New onset sarcoid - like granulomatosis developing during anti-TNF therapy: an under-recognized complication. *Int Med J* 2012;89-94.
7. Liu Y, Cortinovic D, Stone MA. Recent advances in the treatment of the spondyloarthropathies. *Curr Opin Rheumatol* 2004; 16: 357-65
8. Saleh S, Ghodsian S, Yakimova V, Henderson H, Sharma OP. Effectiveness of infliximab in treating selected patients with sarcoidosis. *Respir Med* 2006; 100(11): 2053-2059
9. Vorselaars AD, Crommelin HA, Deneer VH, et al. , Effectiveness of infliximab in refractory FDG PET-positive sarcoidosis. *Eur Respir J* 2015; 46: 175-185
10. Almodovar R, Izquierdo M, Zarco P, Javier Quiros F, Mazzucchelli R, Steen B. Pulmonary sarcoidosis in a patient with ankylosing spondylitis treated with infliximab. *Clin Exp Rheumatol* 2007;25:99-101.