

## SARCOIDOSIS OF THE EXTERNAL NOSE: THE ROLE OF PHARMACOLOGIC RHINOPLASTY IN DIAGNOSIS AND TREATMENT

Yan Ho Lee<sup>1</sup>, Eunice Park<sup>2</sup>, Jonathan Lee<sup>3</sup>, William Lawson<sup>4</sup>

<sup>1</sup> Department of General Surgery, Section of Otolaryngology, Yale School of Medicine, New Haven, Connecticut, USA; <sup>2</sup> Department of Otolaryngology, Head and Neck Surgery, North Shore/Long Island Jewish Medical Center, New Hyde Park, New York, USA; <sup>3</sup> Department of Plastic and Reconstructive Surgery, University of Massachusetts-Baystate, Springfield, Massachusetts; <sup>4</sup> Department of Otolaryngology-Head and Neck Surgery, The Icahn School of Medicine at Mt Sinai, New York, New York, USA;

**ABSTRACT.** Subcutaneous sarcoidosis is a rare manifestation of a systemic disease. Sarcoidosis most often affects the pulmonary system but can also affect sinonasal tissues including the cutaneous and subcutaneous layers. It can be suspected in patients who may or may not have a prior diagnosis of sarcoidosis but who develop nodules or lesions over the nasal dorsum after trauma or rhinoplasty. The onset may also be spontaneous with diffuse enlargement of the nose. The diagnosis can be confirmed with tissue biopsy. Management is primarily medical with topical, intralesional, or systemic steroids. When medical management has failed, surgical options can be considered. We present a total of four patients with subcutaneous nasal sarcoidosis. Two patients had diffuse subcutaneous sarcoidosis that improved significantly with medical therapy. Two other patients with post-traumatic nodule formation were managed with intralesional steroids and surgery. (*Sarcoidosis Vasc Diffuse Lung Dis* 2018; 35: 69-73)

**KEY WORDS:** sarcoidosis, rhinoplasty, lupus pernio, sinonasal sarcoid

### INTRODUCTION

Sarcoidosis is a systemic disease of unknown etiology that is characterized by the presence of non-caseating granulomas in various organs. Pulmonary disease is the most common manifestation, with cutaneous involvement seen in approximately 25% of cases. Approximately 10% of patients with sarcoidosis exhibit otolaryngologic manifestations, with about 4% involving the sinonasal complex. Other systems that may be affected include cardiovascular, reticuloendothelial, musculoskeletal, endocrine, or

central nervous system. There are many diagnostic clues that can be suggestive of the disease including serologic testing, imaging studies, and biopsies. Once non-caseating granulomas are found on biopsy, the patient is suspected of having sarcoidosis, but the diagnosis is one of exclusion, particularly from diseases of mycobacterial and fungal origin.

This paper will subdivide the clinical presentations of sarcoidosis of the external nose into 3 groups based on the site of involvement, and summarize their management for correction of cosmetic deformities. Many patients may not have an established diagnosis of sarcoidosis as nasal changes often are the presenting symptoms of the disease. Consequently, it is crucial to be able to recognize the disease clinically or have a high index of suspicion.

Changes in the soft tissues of the nose secondary to sarcoidosis may involve the skin, subcutaneous tissue, or the mucosa. These often cause cosmetic deformity for which patients seek surgical correction.

Received: 8 March 2017

Accepted after revision: 9 March 2017

Correspondence: Yan Ho, MD,

Department of Otolaryngology-Head and Neck Surgery,

The Icahn School of Medicine at Mt Sinai,

One Gustave Levy Place, Box 1189, New York, NY 10029

Tel. 9178854546 - Fax 212-831-3700

E-mail: yan.ho@mountsinai.org

The literature reporting the correction of these deformities is limited, and each type will be addressed separately.

It is essential to recognize that the mainstay of management of sarcoidosis is primarily medical with steroids; however, they are often used adjunctively with immunomodulating drugs such as methotrexate, hydroxychloroquine, or azathioprine. This is especially true with sinonasal disease when only a few patients are candidates for surgery.

Sinonasal sarcoidosis has many diverse presentations which have been recently classified into 4 groups clinically as an aid to diagnose and treatment (1). In the hypertrophic group, the patient may present as chronic rhinosinusitis with nasal congestion, polyp formation, or the appearance of a large granulomatous mass or scattered septal and turbinate submucosal nodules. The atrophic form presents with mucosal erosion, crusting, and often epistaxis. In the destructive form, perforation of the cartilaginous septum may extend to the bony septum and lateral nasal walls resulting in a saddle nose deformity or palatal fistula. Lastly, the enlargement type presents with a diffuse enlargement in the size of the external nose or the spontaneous development of dorsal nodules.

The saddle nose deformity is the most widely recognized cosmetic complication of sarcoidosis for which patients seek reconstruction. Two papers specifically address repair of saddle nose deformity in sarcoidosis patients. Scott et al, in 1992, replaced a failed cartilage graft with a silastic implant which was successful for 2 years (2). Gurkov and Berghaus, in 2009, repaired the saddle nose deformity with dorsal skin involvement initially with a porous polyethylene graft, then in a second procedure with a paramedian forehead flap (3).

The cutaneous form may present in 3 distinctive fashions: rhinophyma-like changes in the nasal tip, thickening and discoloration of the nasal dorsal skin, and lupus pernio. Rhinophyma-like change in cutaneous sarcoidosis present as a bulbous enlargement of the nasal tip. O'Brien, in 1970, reported 4 cases of massive cutaneous involvement of the nasal tip and columella by sarcoidosis (4). Two cases underwent shave excision. One patient was allowed to heal by secondary intention with a normal appearance at 4 months. The other patient was covered by a full-thickness skin graft and showed evidence of

recurrence at 2 years. Golden et al, in 1983, described treating 2 patients also with shave excision followed by a full thickness skin graft. Both patients appeared normal at 1 and 3 years (5). Preminger et al, 2007, also performed shave excision and full thickness skin grafting on 1 patient who was recurrence-free at 2 years (6).

Dorsal skin thickening and discoloration generally involve the upper two-thirds of the nose. Complete removal requires coverage of the defect with a skin graft or local flap. As mentioned previously, in the patient reported by Gurkov and Berghaus, the extensive skin removal required the use of a paramedian forehead flap for resurfacing.

Lupus pernio presents as a purple mass of papules, nodules, and plaques which has a predilection for the nose, adjacent lips, and cheek. It is associated with concurrent systemic and sinonasal disease and is not generally responsive to medical therapy. However, infliximab has been shown to be effective in causing its regression. Total skin excision is necessary to correct the deformity but is infrequently employed because of its extensive involvement of the face. In 2010, Lesavoy et al reported a case of a black female patient who developed a growth on her lower third of the nose involving the nasal tip and columella. Although she experienced partial regression with oral immunomodulators, ultimately she required surgical excision with primary closure to reconstruct the nasal deformity (7). Smith et al, in 2009, reported excision and resurfacing with a forehead flap of a massive ulcerative nasal lesion. However, massive telangiectasia was seen at 22 months follow-up (8).

The difficulty in evaluating these case reports is that while surgery is performed when the disease is inactive, its natural history is that of quiescent periods followed by reactivation. The reports are limited by short follow-up and even then with local recurrence. Often, aggressive medical management is required for control of the disease.

In the subcutaneous form, a diffuse enlargement of the nose or of focal areas develop spontaneously, following nasal trauma, or after rhinoplasty. The inflammatory process occurs subcutaneously without the violaceous cutaneous changes seen in lupus pernio. The intranasal volume of the tissue is not increased, with atrophic and even destructive changes. Also, unlike lupus pernio, which is often refractory to medical management, subcutaneous enlargement

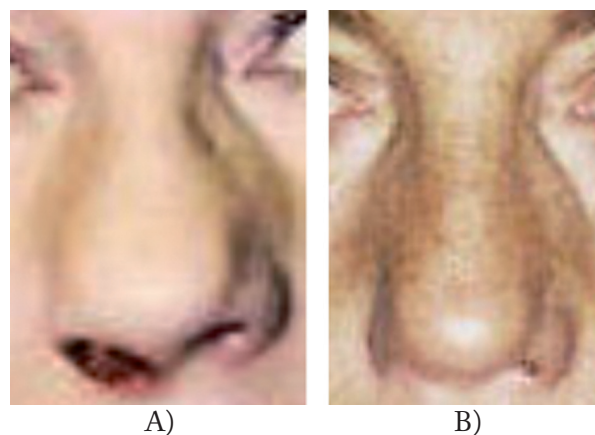
dramatically responds to oral steroids with return of the nasal structure to its original size and shape. Relapses are not uncommon but also respond well to steroids. The reported cases of subcutaneous nasal sarcoidosis are summarised in table 1. The earliest report was by Curtis, in 1964, who described 2 cases of women with swelling over the nasal bridge involving the nasal bones (9). Both of these cases were re-reported by Munro Black in 1966 (10). He also commented that 2 additional cases of nasal deformity had initially failed to respond to tuberculosis treatment but the lesions later were identified as nasal sarcoidosis. In 1990, Milford et al reported 2 additional patients presenting with soft tissue swelling over the nasal bones and upper lateral cartilages, one having an established diagnosis of sarcoidosis (11). The nasal enlargement in these patients was progressive over 3 to 4 years. They observed critically that treatment of the sarcoidosis with systemic steroids resulted in resolution of the deformity.

These case reports of the management of subcutaneous sarcoidosis also suffer from lack of long-term follow-up. In the present series, follow-up ranged from 6 months to 12 years.

## PATIENT SERIES

### Case 1

A 46-year-old female presented with nasal pain, swelling, anosmia and discolored secretions. She had a history of five sinus procedures over a 3 to 4 year period for intractable disease. On physical examination, there was diffuse enlargement of the external nose with granulomatous lesions surrounding the right nostril (Figure 1A). Endoscopy revealed diffuse extensive erosion of the nasal mucosa bilaterally. CT



**Fig. 1.** A) Patient presented with diffuse nasal enlargement and granular mass involving right nostril. B) Patient 2 months after oral steroid therapy

scan showed pansinusitis along with postoperative changes. Nasal culture grew *Staphylococcus aureus*. She was treated with Ceftin and a tapering dose of prednisone 30 mg, and within two weeks the nose returned to its normal size. The diagnosis of sarcoidosis was established with the Kveim test. Serologic studies also revealed an elevated ACE level. She experienced recurrent episodes of nasal ulceration eventually leading to septal perforation and required maintenance levels of prednisone 5 to 15 mg daily to keep her sinonasal disease under control (Figure 1B).

### Case 2

A 63-year-old female had a several years history of chronic sinusitis and atrophic rhinitis. Sinonasal sarcoidosis was diagnosed after endoscopic sinus surgery. She had known bilateral hilar lymphadenopathy, but was asymptomatic and on no medication for systemic disease. She experienced several episodes of diffuse soft tissue enlargement of the external nose,

**Table 1.** Cases of diffuse and nodular enlargement from sarcoidosis

Author	Year	Gender/Age	Type	Onset	Nasal mucosa	Treatment (period of regression)
Curtis/Black	1964/1966	F/32	Diffuse	Spontaneous	Enlargement	-
Curtis/Black	1964/1966	F/65	Diffuse	Trauma	Enlargement	-
Milford et al	1990	F/38	Diffuse	Trauma		Oral steroids, Chloroquine (3 months)
Milford et al	1990	F/39	Diffuse	Spontaneous		Oral steroids (4 months)
Lawson	Case 1	F/46	Diffuse	Spontaneous	Destructive	Oral steroids (2 months)
Lawson	Case 2	F/63	Diffuse	Spontaneous	Atrophic	Oral steroids (1 month)
Lawson	Case 3	M/72	Nodular	Trauma	Normal	Surgery
Lawson	Case 4	F/26	Nodular	Rhinoplasty	Normal	Oral, Intralesional steroids (2 months)

which responded completely to tapering doses of prednisone 20 mg over a period of several weeks. Her atrophic rhinitis was controlled with steroid nasal sprays.

### Case 3

A 72-year-old male was seen following extensive trauma to his face in an automobile accident. Within several days after admission, he developed a rapidly enlarging mass on the mid dorsum of the nose. CT scan revealed a midline lobular soft tissue mass eroding the nasal bones. FNA of the mass was non-diagnostic. The rapid growth and destructive nature of the lesion led to surgical exploration and resection. Pathologic study of the specimen was consistent with sarcoidosis. The patient had no prior history of sarcoidosis or symptoms of the disease (Figures 2A-C).

### Case 4

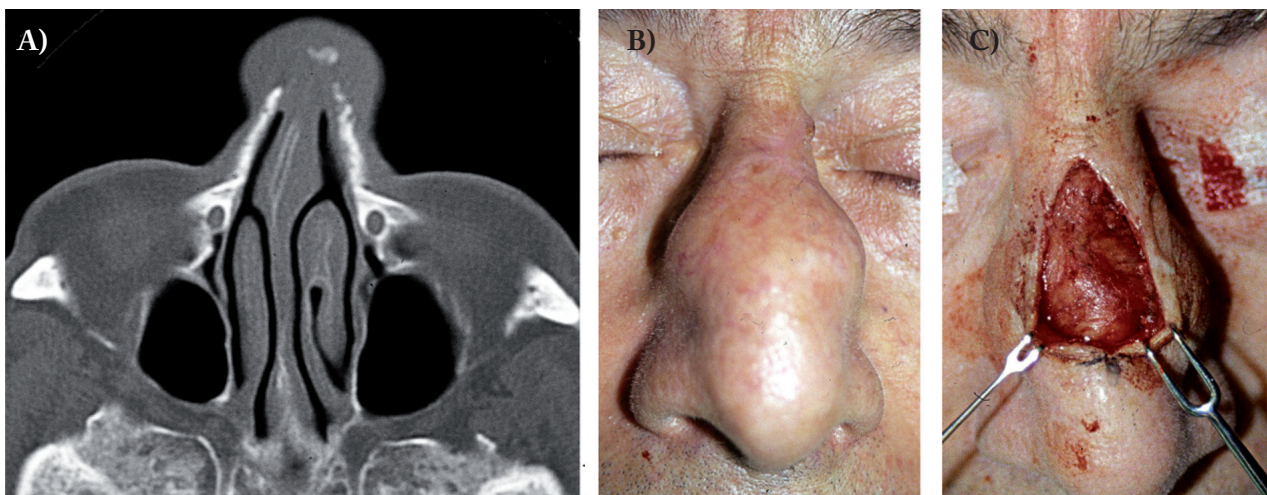
A 26-year-old female slowly developed a subcutaneous mass over the left nasal bone over a period of two months. She had undergone a routine septorhinoplasty six months previously. FNA revealed noncaseating granulomas consistent with sarcoidosis. She was treated with intralesional steroid injections and a tapering dose of prednisone 20 mg which resulted in complete resolution of the lesion in one month. The patient had no prior history of sarcoidosis or any symptoms of the disease.

## TREATMENT

The mainstay of treatment of sinonasal mucosal disease is medical with only a fraction of patients requiring surgery because of infection, obstruction, or cosmetic deformity. Dorsal nasal collapse is the commonest cosmetic complication of the disease which leads patients to seek correction. Studies have shown the ability of non-caseating granulomas to form in grafted skin and cartilage, leading some surgeons to implant alloplastic materials. However, in patients treated with immunosuppressants for local and systemic control of sarcoidosis, having an alloplastic implant is a situation prone to infection with extrusion.

Involvement of the skin in sarcoidosis causes patients to seek cosmetic improvement. Resection of the involved skin and resurfacing of the defect with free grafts and pedicled flaps are also compromised by extension of the disease into the new tissue leading to continued deformity. Of note, sarcoidosis patients should be operated upon only when the disease is quiescent, because nasal reconstructive surgery can be compromised by the activation of inflammatory process.

Subcutaneous diffuse or nodular nasal involvement is the exception where systemic and intralesional steroids eliminate the deformity nonsurgically. Hence, the term pharmacologic rhinoplasty. Table 2 describes possible involvement of the external nose by sarcoidosis and the corresponding management options.



**Fig. 2.** A) Axial CT Scan shows nodular mass overlying nasal dorsum with destruction of nasal bones. B) Rapidly growing dorsal nasal mass destroying nasal bones. C) Irregular nodular mass overlying nasal bones

**Table 2.** Involvement of the external nose by sarcoidosis and management

Layer	Type	Management
Mucosal	Dorsal saddle deformity	Onlay grafting (cartilage or bone)
Cutaneous	Rhinophyma-like	Shave excision
Cutaneous	Dorsal thickening and discoloration	Full thickness excision, graft, flap, resurfacing
Cutaneous	Lupus Pernio	Full thickness excision, graft, flap, resurfacing
Subcutaneous	Diffuse	Oral steroids
Subcutaneous	Nodular	Oral, intralesional steroids

## CONCLUSIONS

Sarcoidosis of the nose may involve the cutaneous, subcutaneous, and mucosal elements. The mucosal form is subdivided by its clinical presentation as hypertrophic, atrophic, and destructive changes. The cutaneous form presents as rhinophyma-like changes, dorsal skin enlargement and discoloration, and lupus pernio. The management of the cutaneous form is surgical with adjunctive medical treatment for systemic control. However, treatment of the subcutaneous form is primarily non-surgical. Dramatic and rapid response to oral steroids and a history of prior surgery or trauma is virtually diagnostic for sarcoidosis. Essentially, resolution of the deformity with steroids alone may be considered “chemical rhinoplasty”.

## ACKNOWLEDGEMENTS

The authors would like to acknowledge the contributions of Mr. Constancio Bernardo in the care of the patients described in this paper.

## REFERENCES

1. Lawson W, Jiang N, Cheng J. Sinonasal sarcoidosis: A new system of classification acting as a guide to diagnosis and treatment. *American Journal of Rhinology and Allergy* 2014; 28: 317-322.
2. Scott PM, Morphopoulos G, Bleach N. Augmentation rhinoplasty in nasal sarcoidosis. *The Journal of Laryngology and Otology* 1992; 106: 544-546.
3. Gurkov R, Berghous A. Nasal reconstruction in advanced sinonasal sarcoidosis. *Rhinology* 2009; 47: 327-329.
4. O'Brien P. Sarcoidosis of the nose. *British Journal of Plastic Surgery* 23: 242.
5. Goldin JH, Reid AP. Cutaneous nasal sarcoidosis – treatment by excision and split-skin grafting. *The Journal of Laryngology and Otology* 1983; 1053-1056.
6. Preminger BA, et al. An operative approach to the treatment of refractory cutaneous nasal sarcoid: a case report and review of the literature. *Annals of Plastic Surgery* 2009; 63(6): 685-7.
7. Lesavoy MA, Shirvanian VN, Grimes P. Surgical reconstruction of nasal sarcoidosis: a case report. *Annals of Plastic Surgery* 2010; 64(6): 800-2.
8. Smith R, Haeney J, Gulraiz Rauf KH. Improving cosmesis of lupus pernio by excision and forehead flap reconstruction. *Clinical and Experimental Dermatology* 2009; 34(5): e25-7.
9. Curtis GT. Sarcoidosis of the nasal bones. *British Journal of Radiology*. 1964; 37(433).
10. Munro Black JI. Sarcoidosis of the Nose. *The Journal of Laryngology & Otology* 1996; 80(10): 1065-1068.
11. Milford CA, Mugliston T, Lund VJ. ‘Medical rhinoplasty’ in nasal sarcoidosis. *Rhinology* 1990; 28: 137-139.