

INTRASCROTAL AND OSSEOUS SARCOIDOSIS MIMICKING INTRASCROTAL ORGAN CANCER AND BONY METASTASIS

Shin-ichi Nureki¹, Eishi Miyazaki², Mari Yamasue¹, Ryuichi Takenaka¹, Masaru Ando¹, Jun-ichi Kadota¹

¹Department of Respiratory Medicine and Infectious Diseases and ²Center for Community Medicine, Oita University Faculty of Medicine, 1-1 Idaigaoka, Hasama-machi, Yufu, Oita 879-5593, Japan

ABSTRACT. We report a case of sarcoidosis with concomitant epididymis, testes, and phalanges involvement mimicking intrascrotal organ cancer and metastatic bony disease. A 23-year-old man developed blurred vision and hyperemia of the left eye, and was diagnosed as having left iritis. A chest computed tomography scan detected bilateral hilar lymphadenopathy and lung nodular shadows. A transbronchial lung biopsy revealed a non-caseating granuloma and he was diagnosed with sarcoidosis. One year after the onset of his eye symptoms, he noticed enlargement of his right scrotum. Magnetic resonance imaging detected lesions of the right epididymis, bilateral testes, and bilateral phalanges. A technetium-99m scintigram revealed a high accumulation in the bilateral bones of extremities. These radiological findings mimicked intrascrotal organ cancer and metastatic bony disease. Pathologic evaluation following the right epididymectomy revealed non-caseating granulomas compatible with sarcoidosis. Three and half years after the appearance of intrascrotal and bony lesions, they improved spontaneously. (*Sarcoidosis Vasc Diffuse Lung Dis* 2017; 34: 373-376)

KEY WORDS: cancer, intrascrotal organ, osseous, sarcoidosis, spontaneous remission

INTRODUCTION

Sarcoidosis is a multisystem inflammatory disease of unknown etiology. Intrascrotal and osseous involvements are less common manifestations of sarcoidosis (1-3). To diagnose intrascrotal sarcoidosis, it is important to exclude the possibility of intrascrotal organ cancer (4-8). In addition, even if the pathological findings of sarcoidosis was observed in other than intrascrotal organs from patients with an intrascrotal mass, clinicians need to exclude the possibility

of sarcoid-reaction associated with intrascrotal organ cancer (9-12). Here, we report a case of sarcoidosis involving epididymis, testes, and phalanges lesions; those radiographic findings resembled intrascrotal organ cancer and metastatic bony disease. The intrascrotal and bone lesions went into spontaneous remission after a three and a half year observation.

CASE REPORT

In March 2007, a 23-year-old man developed blurred vision and hyperemia of the left eye and visited a nearby clinic. He was diagnosed with left iritis and referred to another hospital. A chest X-ray and computed tomography (CT) scan detected bilateral hilar lymphadenopathy and lung nodular shadows. Thereafter, he was admitted to our hospital for close investigation in August, 2007. The patient had a his-

Received: 13 June 2016

Accepted after revision: 29 June 2017

Correspondence: Shin-ichi Nureki,

Department of Respiratory Medicine and Infectious Diseases,

Oita University Faculty of Medicine, 1-1 Idaigaoka,

Hasama-machi, Yufu, Oita 879-5593, Japan

Tel. +81-97-586-5804

Fax +81-97-549-4245

E-mail: nureki@oita-u.ac.jp

tory of bronchial asthma and atopic dermatitis, but was otherwise healthy. On admission, the patient's temperature was 36.9°C, pulse rate 86 beats/min, and respiratory rate 22 breaths/min. No crackles were heard over the lung fields. Laboratory data demonstrated elevated serum levels of angiotensin converting enzyme (26.5 IU/L [baseline 8.3-21.4 IU/L]) and lysozyme (27.4 mg/mL [baseline 5.0-10.2 mg/mL]). The PPD skin test was negative. Pulmonary function results were within the normal range. Bronchoalveolar lavage fluid showed an increased total cell concentration ($3.98 \times 10^5/\text{mL}$), increased lymphocyte ratio (23.7%), and an increased CD4/CD8 ratio (3.85). A chest X-ray film and CT scans showed bilateral lymphadenopathy, thickening of the bronchovascular bundles, and nodular shadows in the lung. A gallium-67 scintigram showed increased uptake in the bilateral parotid glands; bilateral hilar, mediastinal, and supraclavicular lymph nodes; and bilateral lungs (Figure 1-a). Histopathologic examination of

the transbronchial lung biopsy revealed non-caseating epithelioid granulomas with giant cells. The patient was thus diagnosed with sarcoidosis. Before discharge, he complained of low-grade fever and dry mouth. In November 2007, erythema of the trunk and extremities appeared. Both lip and skin biopsies also revealed non-caseating epithelioid granuloma consistent with sarcoidosis.

In March 2008, he noticed a painless right scrotal swelling. A gallium-67 scintigram revealed newly increased uptake in the bilateral scrotum and extremities, in addition to the sites of increased uptake noted on the first examination (Figure 1-b). A technetium-99m scintigram revealed a high accumulation in the bilateral bones of the extremities consistent with the gallium-67 scintigram (Figure 1-c). Magnetic resonance imaging (MRI) revealed lesions in the right epididymis, bilateral testes (Figure 2-a, b), and bilateral phalanges (Figure 3-a, b, e, f). He had no pain or swelling in the extremities. Histologic evaluation following a right epididymectomy revealed non-caseating epithelioid cell granulomas with giant cells that were identical to sarcoidosis (Figure 4). Periodic MRI examinations every three months revealed no changes in these lesions for one year. Two and half years after the previous MRI examination, these lesions disappeared without therapy (Figure 2-c, d; Figure 3-c, d, g, h).

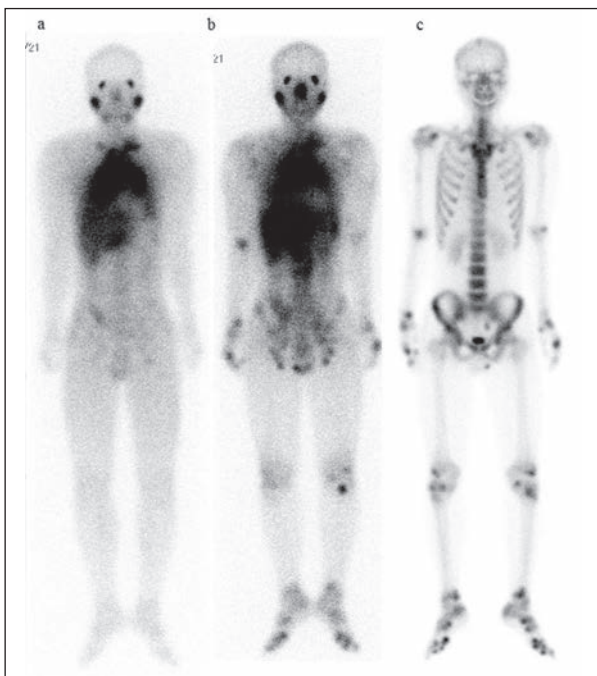


Fig. 1. Gallium-67 scintigram on first admission showed increased uptake in the bilateral parotid glands, bilateral hilar, mediastinal, and bilateral supraclavicular lymph nodes, and bilateral lung (a). Ten months after the first examination, Gallium-67 scintigram showed newly increased uptake in the bilateral scrotum and extremities in addition to the sites which were also observed at the first examination (b). Technetium-99m scintigram on second admission detected high accumulation in the bilateral bones of extremities consistent with the gallium-67 scintigram (b)

DISCUSSION

Sarcoidosis is a multiple organ disease characterized by granuloma formation and inflammatory cell infiltration. More than 90% of patients with sarcoidosis have lung involvement, while in contrast, intrascrotal and osseous involvement are less common manifestations of sarcoidosis. Intrascrotal sarcoidosis is reported in less than 5% in postmortem examination and in 0.5% of patients clinically (1-3). Bone involvement is reported to be 1-13% of sarcoidosis (13). Three cases of coexisted intrascrotal and osseous sarcoidosis have been reported in the literature (14-16) (Table 1). Including our case, the average onset age of intrascrotal lesions was 31.5 years (range: 24-44 years). Every patient developed intrascrotal and osseous lesions one year or more after the initial symptoms of sarcoidosis. All patients complained of painless swelling of the scro-

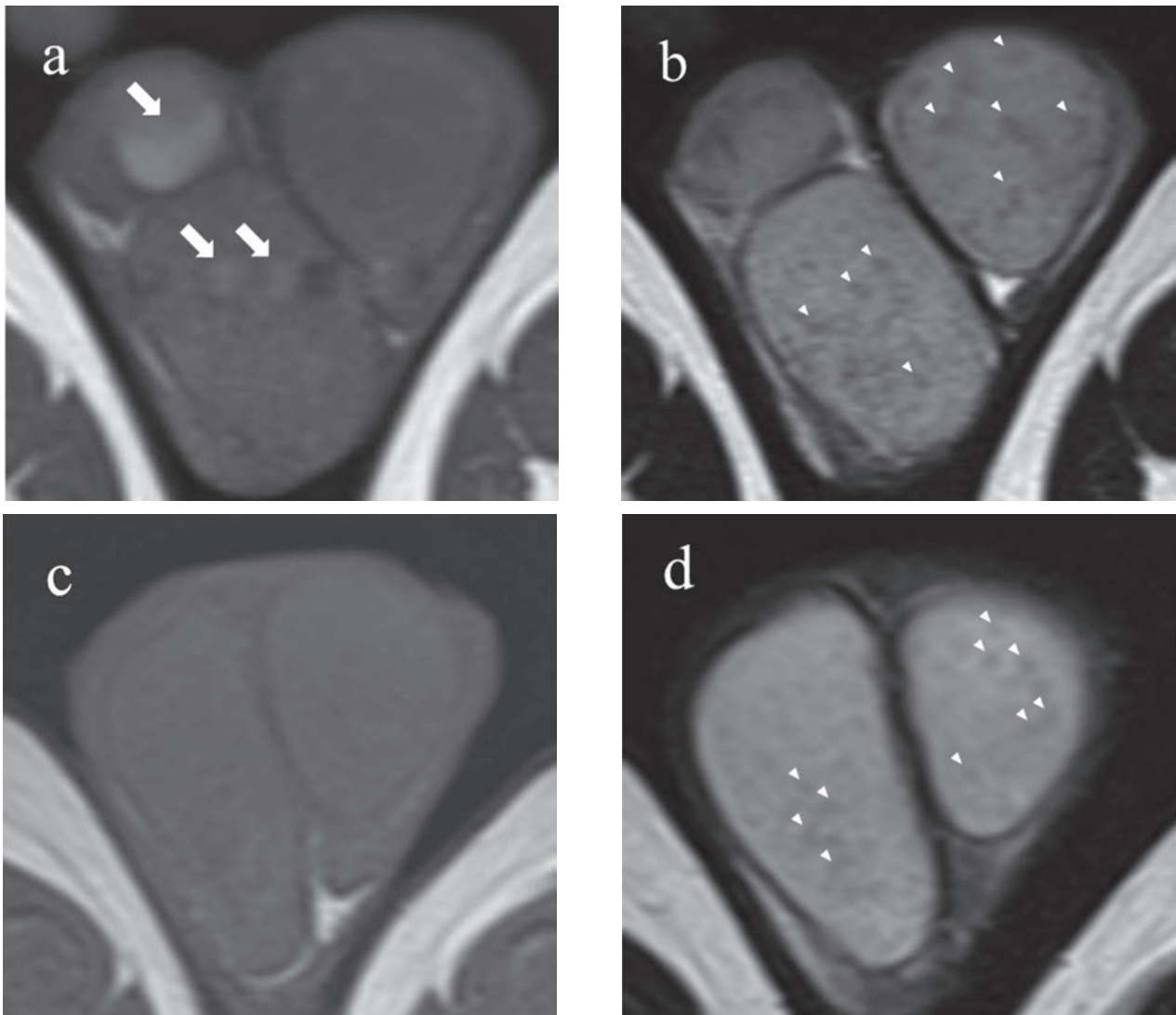


Fig. 2. Magnetic resonance imaging (MRI) on second admission (a, T1- weighted image [WI]; b, T2-WI) showed T1-WI high (a, arrow), T2-WI intermediate intensity nodules in the right epididymis and testis, and T1-WI intermediate, T2-WI low intensity nodules (b; arrow head) in bilateral testes. After three and half years from the first MRI examination (c: T1-WI, d: T2-WI), T1-WI high, T2-WI intermediate intensity nodules had disappeared and the sizes of T1-WI intermediate, T2-WI low nodules (d, arrow head) were reduced spontaneously

tum. Every coexisted case was associated with skin or subcutaneous lesions. Coexisting intrascrotal and osseous lesions might occur as an exacerbation of the disease in young to middle-aged male patients with chronic systemic sarcoidosis. All of these cases were administered pathological examinations of testis or epididymis for the diagnosis, to exclude the possibility of intrascrotal cancer, even though they had been diagnosed with sarcoidosis before the symptoms of scrotal swelling appeared.

Radiographic findings are helpful for the diagnosis of intrascrotal sarcoidosis. Gallium-67 scintigram can detect the intrascrotal lesion (17-19). The sonographic finding in intrascrotal sarcoidosis is a hyperechoic mass or a coarsened testicular echotexture in the testis or epididymis (20, 21). MRI findings of intrascrotal sarcoidosis are not fully understood because only five case reports exist on the MRI findings of intrascrotal sarcoidosis (17, 18, 22-24) (Table 2). T1-WI (weighted image) postcontrast

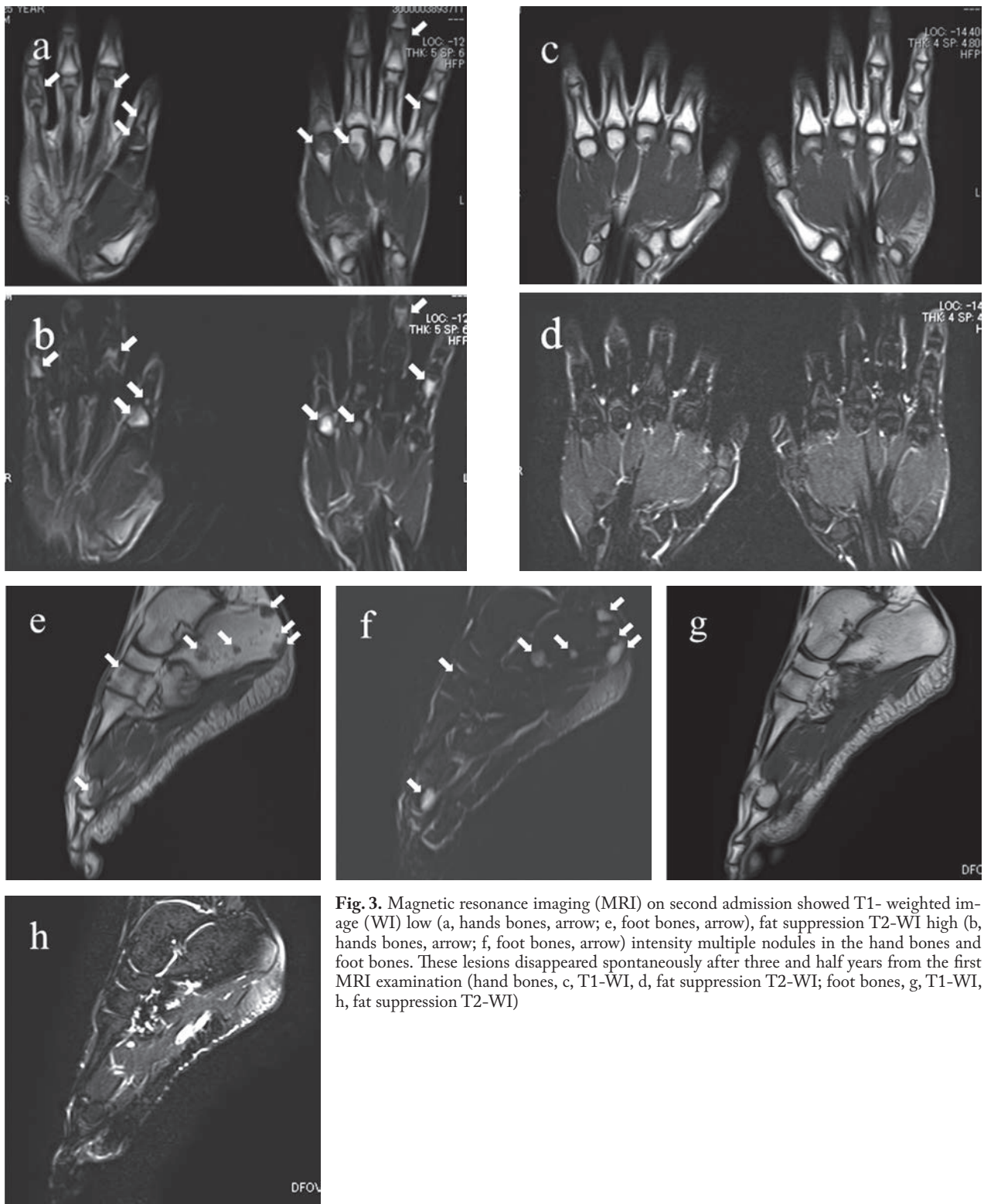


Fig. 3. Magnetic resonance imaging (MRI) on second admission showed T1- weighted image (WI) low (a, hands bones, arrow; e, foot bones, arrow), fat suppression T2-WI high (b, hands bones, arrow; f, foot bones, arrow) intensity multiple nodules in the hand bones and foot bones. These lesions disappeared spontaneously after three and half years from the first MRI examination (hand bones, c, T1-WI, d, fat suppression T2-WI; foot bones, g, T1-WI, h, fat suppression T2-WI)

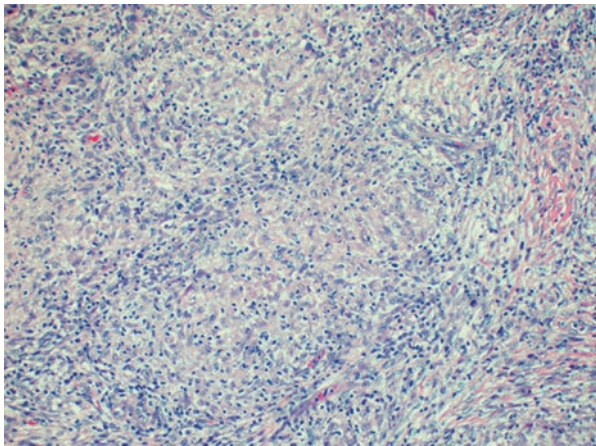


Fig. 4. Pathological evaluation following right epididymectomy revealed non-caseating epithelioid cell granulomas with giant cells (Haematoxylin and eosin stain, x100)

enhanced, diffuse enlarged epididymis, and T2-WI low intensity lesions in testis might be some of the common findings of intrascrotal sarcoidosis. We

could discover diversity in these findings. Kodama et al. reported T1-WI intermediate, and T2-WI slightly high intensity nodules in slightly enlarged epididymises in epididymal sarcoidosis (18). Our case showed T1-WI high intensity and T2-WI intermediate intensity nodules in the epididymis and testis, in addition to T1-WI intermediate intensity and T2-WI low intensity nodules in the testes.

Radiographic findings might not be able to distinguish osseous sarcoidosis from metastatic bony diseases. Osseous sarcoidosis masquerading as metastatic diseases have been reported (25, 26). Osseous sarcoidosis lesions cannot be reliably distinguished as sarcoidosis from metastatic lesions on routine MRI studies by readers not experienced in evaluating these lesions (27). Technetium-99m scintigram findings of osseous sarcoidosis resemble those of osseous metastases (28). 18F-fluorodeoxyglucose positron emission tomography/CT is useful for detecting osseous lesions in sarcoidosis; however, it will not be

Table 1. Clinical characteristics of patients with coexisted intrascrotal and osseous sarcoidosis

Reference number	Age at the onset of intrascrotal lesion	Duration from the onset of sarcoidosis to the appearance of intrascrotal lesion	Testicular lesion	Epididymal lesion	Osseous lesion	Other diseased organ	Diagnostic procedure	Treatment	Outcome
14	44	3 yr 2 mo	No	Yes	Cysts in on distal phalanx of left 5th finger	Mediastinal lymph nodes, subcutaneous nodules on the left arms and both thighs, spermatic cord	Right orchiectomy	Not done	Not stated
15	24	2 yr 7 mo	Yes	Not stated	Phalanxes of right hands	Mediastinal lymph nodes, lung, skin	Biopsy against left testis	Oral prednisone (30 mg/day)	Remission
16	34	7 yr 7 mo	Yes	Yes	Cystic bone lesions in hands, nasal bone	Mediastinal lymph nodes, lung, skin, parotid glands	Left orchiectomy	Not stated	Not stated
Our case	24	1 yr	Yes	Yes	Phalanxes of hands and feet	Mediastinal lymph nodes, lung, skin, parotid glands, eye	Right epididymectomy	Not done	Remission

y=year or years, mo=months

Table 2. Magnetic resonance imaging findings of patients with intrascrotal sarcoidosis

Reference number	MRI findings of epididymis	MRI findings of testis
17	Enlargement of epididymises	T2-WI low intensity nodules
18	T1-WI intermediate, T2-WI slightly high intensity nodules in slightly enlarged epididymises	Not stated
22	T2-WI low and T1-WI postcontrast enhanced lesions	T2-WI low and T1-WI postcontrast enhanced lesions
23	T1-WI postcontrast enhanced, diffuse enlarged epididymises	Not stated
24	T1-WI postcontrast enhanced, enlarged epididymises	Not stated
Our case	T1-WI high, T2-WI intermediate intensity, nodules in enlarged epididymis	T1-WI high, T2-WI intermediate intensity nodules, and T1-WI intermediate, T2-WI low intensity nodules

MRI; magnetic resonance imaging, WI; weighted images

able to discriminate sarcoidosis from metastatic bony disease (29).

In diagnosing sarcoidosis, it is very important to exclude sarcoid-reaction associated with malignant disease (30). Several studies found an increased incidence of malignancy preceding or following the diagnosis of granulomatous disease (11, 31, 32). Granulomas could have been found surrounding the primary tumor (3 to 7% of cases) or in the draining lymph nodes (4.4% of cases) as tumor-related sarcoid reactions (30, 33, 34). Testicular cancer (11% in 64 cases) is one of the common cancers associated with sarcoidosis or sarcoid-reaction (35). Just 14% of sarcoidosis cases concomitant with testicular cancer have been diagnosed as having sarcoidosis before the diagnosis of testicular cancer (11). Also, in our case, even if the patient was diagnosed as having sarcoidosis before the appearance of an intrascrotal mass, we needed to exclude the possibility of sarcoid reaction associated with intrascrotal organ cancer.

The prognosis and therapeutic strategy of intrascrotal sarcoidosis are not well established because of its rarity. Spontaneous remission occurred in only

two patients with epididymal sarcoidosis (36, 37). Some reports have documented the resolution of intrascrotal sarcoidosis after corticosteroid therapy (17, 24). Another case of intrascrotal lesion had progressed while the patient was on steroid therapy with recurrent epididymitis associated with interductal fibrosis (38). The important problem of intrascrotal sarcoidosis is azoospermia or oligospermia (39-42). Three cases with azoospermia were successfully treated with corticosteroid therapy (40-42); one case with azoospermia was resistant to corticosteroid therapy (39). In our case, semen examination was normal at the diagnosis of intrascrotal sarcoidosis; however, we need to be careful for the long-term fertility problem because epididymal sarcoidosis could progress to azoopenia, although the semen test was normal at the initial diagnosis of sarcoidosis (39).

Steroid therapy for osseous sarcoidosis would not be effective, although it may be effective to relieve the symptoms, such as pain and swelling (43). Furthermore, prolonged corticosteroid administration increases the risk of osteoporosis, fracture, and avascular necrosis in patients with osseous sarcoidosis (44). Symptomatic relief also may be obtained by colchicine, indomethacin, and other nonsteroidal anti-inflammatory agents. Hydroxychloroquine or tumor necrosis factor inhibitor treatment might be also effective for symptomatic osseous sarcoidosis (43, 45). Just 15% (3 cases out of 20 cases) of osseous sarcoidosis resulted in spontaneous remission (45). Pathological fracture is the most serious issue in patients with osseous sarcoidosis (46-49). In our case, osseous involvement went into spontaneous remission without pathological fracture.

In conclusion, we experienced a rare case of concomitant intrascrotal and osseous sarcoidosis. Radiographic findings of these lesions resembled intrascrotal organ cancer and metastatic bony disease. We obtained the pathological diagnosis of intrascrotal sarcoidosis from a right epididymectomy to exclude the possibility of intrascrotal cancer with systemic sarcoid reaction or complication of systemic sarcoidosis. Intrascrotal and osseous lesions improved spontaneously.

REFERENCES

1. Ricker W, Clark M. Sarcoidosis; a clinicopathologic review of 300 cases, including 22 autopsies. *Am J Clin Pathol* 1949; 19: 725-49.
2. Engle RL, Jr. Sarcoid and sarcoid-like granulomas; a study of twenty-seven post-mortem examinations. *Am J Pathol* 1953; 29: 53-69.

3. Morimoto T, Azuma A, Abe S, et al. Epidemiology of sarcoidosis in Japan. *Eur Respir J* 2008; 31: 372-9.
4. SultanAli I, Zaman M, Yende S. Sarcoidosis mimicking disseminated testicular cancer. *South Med J* 2005; 98: 935-6.
5. Gross AJ, Heinzer H, Loy V, Dieckmann KP. Unusual differential diagnosis of testis tumor: intrascrotal sarcoidosis. *J Urol* 1992; 147: 1112-4.
6. Gupta R, Senadhi V. A diagnostic dilemma: metastatic testicular cancer and systemic sarcoidosis - a review of the literature. *Case Rep Oncol* 2011; 4: 118-24.
7. Esnakula AK, Coleman P, Ahaghotu CA, Naab TJ. Scrotal mass and unilateral lung masses with pleural effusion mimicking metastatic testicular malignancy: an unusual presentation of sarcoidosis. *BMJ Case Rep* 2013.
8. Joel J, Thomas J, Gill K, Biyani CS. Testicular sarcoidosis masquerading as testicular carcinoma. *Cent European J Urol* 2014; 67: 261-3.
9. Leatham EW, Eeles R, Sheppard M, et al. The association of germ cell tumours of the testis with sarcoid-like processes. *Clin Oncol (R Coll Radiol)* 1992; 4: 89-95.
10. Tjan-Heijnen VC, Vlasveld LT, Pernet FP, Pauwels P, De Mulder PH. Coincidence of seminoma and sarcoidosis: a myth or fact? *Ann Oncol* 1998; 9: 321-5.
11. Paparel P, Devonec M, Perrin P, et al. Association between sarcoidosis and testicular carcinoma: a diagnostic pitfall. *Sarcoidosis Vasc Diffuse Lung Dis* 2007; 24: 95-101.
12. Kaikani W, Boyle H, Chatte G, et al. Sarcoid-like granulomatosis and testicular germ cell tumor: the 'Great Imitator'. *Oncology* 2011; 81: 319-24.
13. James DG, Neville E, Carstairs LS. Bone and joint sarcoidosis. *Semin Arthritis Rheum* 1976; 6: 53-81.
14. Krauss L. Genital sarcoidosis: case report and review of the literature. *J Urol* 1958; 80: 367-70.
15. Chowdhury SD, Higgins PM. Sarcoid of the testis. *Br J Urol* 1973; 45: 218-20.
16. Hackney RL, Jr., Jackson AG, Worrell RG. Sarcoidosis of the testis: a case report. *J Natl Med Assoc* 1986; 78: 63: 65-8.
17. Handa T, Nagai S, Hamada K, et al. Sarcoidosis with bilateral epididymal and testicular lesions. *Intern Med* 2003; 42: 92-7.
18. Kodama K, Hasegawa T, Egawa M, Tomosugi N, Mukai A, Namiki M. Bilateral epididymal sarcoidosis presenting without radiographic evidence of intrathoracic lesion: Review of sarcoidosis involving the male reproductive tract. *Int J Urol* 2004; 11: 345-8.
19. Astudillo L, Payoux P, Game X, Sailler L, Arne JL, Arlet-Suau E. Bilateral testicular and epididymal involvement in sarcoidosis. *Am J Med* 2004; 116: 646-7.
20. Stewart VR, Sidhu PS. The testis: the unusual, the rare and the bizarre. *Clin Radiol* 2007; 62: 289-302.
21. Howlett DC. RE: the testes: the unusual, the rare and the bizarre. *Clin Radiol* 2007; 62: 1019.
22. Koyama T, Ueda H, Togashi K, Umeoka S, Kataoka M, Nagai S. Radiologic manifestations of sarcoidosis in various organs. *Radiographics* 2004; 24: 87-104.
23. Hassan A, El-Mogy S, Zalata K, Mostafa T. Bilateral epididymal sarcoidosis. *Fertil Steril*, 2009.
24. Canguven O, Balaban M, Selimoglu A, Albayrak S. Corticosteroid therapy improves the outcome of semen analysis in an oligozoospermic patient with epididymal sarcoidosis. *Korean J Urol* 2015; 54: 558-60.
25. Barratt S, Burn PR, Stone R. Osseous sarcoidosis masquerading as metastatic disease. *Br J Hosp Med (Lond)* 2009; 70: 164-5.
26. Braza DW, Nelson PA. Vertebral sarcoidosis masquerading as breast metastasis. *Am J Phys Med Rehabil* 2014; 93: 274.
27. Moore SL, Kransdorf MJ, Schweitzer ME, Murphey MD, Babb JS. Can sarcoidosis and metastatic bone lesions be reliably differentiated on routine MRI? *AJR Am J Roentgenol* 2012; 198: 1387-93.
28. Sakellariou GT, Anastasilakis AD, Karanikolas D, Vounotrypidis P, Berberidis C. Central skeletal sarcoidosis: a case report with sustained remission only on methotrexate, and a literature review on the imaging approach, treatment, and assessment of disease activity. *Mod Rheumatol*, 2012.
29. Conte G, Zugni F, Colleoni M, Renne G, Bellomi M, Petralia G. Sarcoidosis with bone involvement mimicking metastatic disease at (18) F-FDG PET/CT: problem solving by diffusion whole-body MRI. *Ecancermedalscience* 2015; 9: 537.
30. Statement on sarcoidosis. Joint Statement of the American Thoracic Society (ATS), the European Respiratory Society (ERS) and the World Association of Sarcoidosis and Other Granulomatous Disorders (WASOG) adopted by the ATS Board of Directors and by the ERS Executive Committee, February 1999. *Am J Respir Crit Care Med* 1999; 160: 736-55.
31. Rayson D, Burch PA, Richardson RL. Sarcoidosis and testicular carcinoma. *Cancer* 1998; 83: 337-43.
32. Bonifazi M, Bravi F, Gasparini S, et al. Sarcoidosis and cancer risk: systematic review and meta-analysis of observational studies. *Chest* 2015; 147: 778-91.
33. Brincker H. Sarcoid reactions in malignant tumours. *Cancer Treat Rev* 1986; 13: 147-56.
34. Marruchella A. Sarcoidosis or sarcoid reaction? *Chest* 2009; 136: 943-4; author reply 944.
35. Kiess AP, Wang H, Travis WD, Yahalom J. Sarcoid in cancer patients: clinical characteristics and associated disease status. *Sarcoidosis Vasc Diffuse Lung Dis* 2015; 32: 200-7.
36. Singer EP, Hensler NM, Flynn PF. Sarcoidosis; an analysis of forty-five cases in a large military hospital. *Am J Med* 1959; 26: 364-75.
37. Hines HL, Elgart ML, Mackenzie AR. Sarcoidosis: case presentation and discussion. *J Urol* 1961; 85: 71-4.
38. Winnacker JL, Becker KL, Katz S, Matthews MJ. Recurrent epididymitis in sarcoidosis. Report of a patient treated with corticosteroids. *Ann Intern Med* 1967; 66: 743-8.
39. Svetec DA, Waguespack RL, Sabanegh ES, Jr. Intermittent azoospermia associated with epididymal sarcoidosis. *Fertil Steril* 1998; 70: 777-9.
40. Rees DA, Dodds AL, Rathbone N, Davies JS, Scanlon MF. Azoospermia in testicular sarcoidosis is an indication for corticosteroid therapy. *Fertil Steril* 2004; 82: 1672-4.
41. Kovac JR, Flood D, Mullen JB, Fischer MA. Diagnosis and treatment of azoospermia resulting from testicular sarcoidosis. *J Androl* 2012; 33: 162-6.
42. Paknejad O, Gilani MA, Khoshchreh M. Testicular masses in a man with a plausible sarcoidosis. *Indian J Urol* 2011; 27: 269-71.
43. Wilcox A, Bharadwaj P, Sharma OP. Bone sarcoidosis. *Curr Opin Rheumatol* 2000; 12: 321-30.
44. Sweiss NJ, Lower EE, Korsten P, Niewold TB, Favus MJ, Baughman RP. Bone health issues in sarcoidosis. *Curr Rheumatol Rep* 2011; 13: 265-72.
45. Sparks JA, McSparron JI, Shah N, et al. Osseous sarcoidosis: clinical characteristics, treatment, and outcomes--experience from a large, academic hospital. *Semin Arthritis Rheum* 2014; 44: 371-9.
46. Liu B, Zhang X, Zhang W, Wang JB, Zhang FC. Solitary osseous sarcoidosis: a rare reason for pathologic fracture. *Rheumatol Int* 2012; 32: 2535-8.
47. Handa T, Nagai S, Ito I, et al. Multiple bone fractures found in a young sarcoidosis patient with long stable disease. *Intern Med* 2005; 44: 1269-75.
48. Zickel RE, Bernstein RS, Ryan SF, Carney WP. Pathological ununited fractures of the long bones in a patient who had sarcoidosis. A case report. *J Bone Joint Surg Am* 1995; 77: 440-3.
49. Redman DS, McCarthy RE, Jimenez JF. Sarcoidosis in the long bones of a child. A case report and review of the literature. *J Bone Joint Surg Am* 1983; 65: 1010-4.