

## PIRFENIDONE FOR PRIMARY SJÖGREN'S SYNDROME-RELATED FIBROTIC INTERSTITIAL PNEUMONIA

Yasunori Enomoto<sup>1</sup>, Yutaro Nakamura<sup>1</sup>, Thomas V. Colby<sup>2</sup>, Naoki Inui<sup>1,3</sup>, Takafumi Suda<sup>1</sup>

<sup>1</sup>Second Division, Department of Internal Medicine, Hamamatsu University School of Medicine, Japan; <sup>2</sup>Department of Laboratory Medicine and Pathology, Mayo Clinic, USA; <sup>3</sup>Department of Clinical Pharmacology and Therapeutics, Hamamatsu University School of Medicine, Japan

**ABSTRACT.** Primary Sjögren's syndrome-related interstitial pneumonia (pSS-IP) is occasionally progressive even with immunosuppressive therapy and new treatment options are warranted. A 42-year-old woman was diagnosed with pSS-IP with pathological usual interstitial pneumonia pattern. Although her forced vital capacity (FVC) had temporarily improved after prednisolone therapy, it deteriorated during the prednisolone tapering off period. Therefore, pirfenidone was added in conjunction with prednisolone. During the 12-month treatment period, her FVC was almost stable. A 62-year-old man, a current heavy smoker, was diagnosed with pSS-IP. Chest computed tomography showed bilateral honeycombing with ground-glass attenuation on a background of emphysema. He gradually developed dyspnea on exertion and his FVC deteriorated. Hence, pirfenidone was administered as a monotherapy. Six months later, his FVC and exercise tolerance had significantly improved. Pirfenidone might have a role for the treatment of pSS-IP. (*Sarcoidosis Vasc Diffuse Lung Dis* 2017; 34: 91-96)

**KEY WORDS:** pirfenidone, Sjogren's syndrome, interstitial pneumonia

### Introduction

Interstitial pneumonia (IP) is a common lung complication in primary Sjögren's syndrome (pSS). Although the prognosis of patients with pSS-related IP (pSS-IP) is generally favorable, with 5-year survival rates of 84-87%, progressively worsening and occasionally fatal cases have been reported (1-3). Immunosuppressive therapy including corticosteroids with/without immunosuppressants are often administered to such patients, but the effectiveness

of the drug may be limited particularly for those with pathological usual interstitial pneumonia (UIP) pattern or advanced fibrotic IP (2, 4). In addition, the long-term corticosteroids therapy can cause adverse complications such as infections due to immunosuppression, osteoporosis, and diabetes mellitus. Alternative, less toxic therapeutic options are needed.

Pirfenidone is now one of the standard drugs for patients with idiopathic pulmonary fibrosis (IPF) (5). The most recent and largest randomized controlled trial (ASCEND study) (6), which was performed in patients with IPF who received either pirfenidone or placebo for 52 weeks, reported that the drug prevented disease progression in terms of lung function (particularly forced vital capacity [FVC]), exercise tolerance, and progression-free survival. Pirfenidone has been demonstrated to have antifibrotic effects by inhibiting fibroblast proliferation and transforming growth factor- $\beta$ -stimulated colla-

Received: 1 January 2016

Accepted after revision: 14 March 2016

Correspondence: Yasunori Enomoto, M.D.

Second Division, Department of Internal Medicine,  
Hamamatsu University School of Medicine, Hamamatsu, Japan

1-20-1 Handayama, Hamamatsu, Shizuoka 431-3192, Japan

Tel. +81 534352263

Fax: +81 534352153

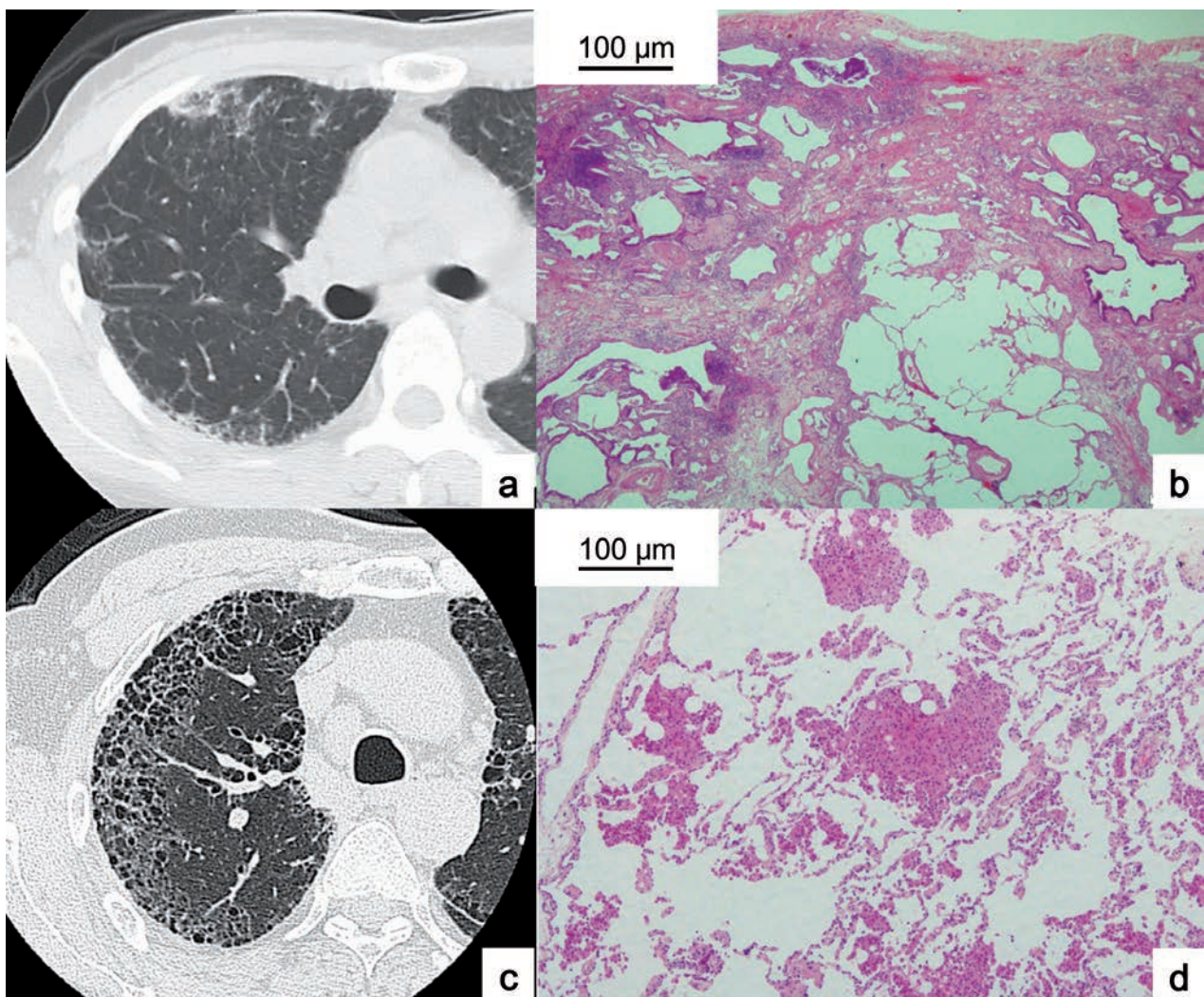
E-mail: enomotoy@hama-med.ac.jp

gen synthesis (7-10), which may be common treatment targets for IPF, as well as other fibrotic IPs. In fact, pirfenidone was suggested to have favorable efficacy to improve FVC even in patients with scleroderma-related IP (11, 12). To our knowledge, there have been no reports on the efficacy of pirfenidone therapy in patients with pSS-IP. Here, we report two cases of pSS-IP with fibrotic changes who received pirfenidone.

## CASE PRESENTATION

### Case 1

A 42-year-old, non-smoking woman was referred to our institution with a 3-month history of dry cough. Auscultation revealed bibasilar fine crackles at the back. The rheumatoid factor was positive and the antinuclear antibody was at a titer of 1:640,



**Fig. 1.** Radiological and pathological findings at diagnoses in case 1 and 2  
 Case 1. (a) Subpleural and patchy reticulation with slight traction bronchiectasis are shown on high-resolution computed tomography (HRCT). (b) On pathology, patchy distribution of dense fibrosis with microscopic-honeycombing is observed. Lymphoid follicles without germinal center are scattered (Hematoxylin-Eosin, x12.5). Case 2. (c) Subpleural cystic changes including honeycombing with ground-glass attenuation are distributed on HRCT. (d) The lung specimen shows an emphysematous change with intra-alveolar pigmented macrophages (Hematoxylin-Eosin, x40)

although the anti-SS-A/Ro autoantibody was negative. Apparent keratoconjunctivitis sicca was not found, but lacrimal secretions were slightly decreased (Shirmer's test: right 4 mm; left 8 mm). A minor salivary gland biopsy showed mild lymphocytic sialadenitis with a focus score of 1 (the focus score is the number of aggregates of  $\geq 50$  lymphocytes per 4 mm<sup>2</sup> of salivary gland tissue), which lead to a diagnosis of pSS according to the criteria published by the American College of Rheumatology (13). Serum Krebs von den Lungen-6 (KL-6) level was relatively high (517 U/mL; reference range <500 U/mL). High-resolution computed tomography (HRCT) showed bilateral, upper-predominant, and subpleural reticulation with slight traction bronchiectasis (Figure 1a). No honeycombing was observed. A surgical lung biopsy at right S<sup>9</sup> demonstrated a UIP pattern with patchy distribution of fibrosis, fibroblastic foci, microscopic-honeycombing, and lymphoid follicles without germinal centers (Figure 1b). The findings were interpreted as a pSS-related UIP pattern.

Prednisolone at a dose of 40 mg/day (1 mg/kg) was administered after the biopsy. FVC significantly improved from 72.7% to 83.6% after 6 months. Serum KL-6 level decreased to 357 U/mL. Those variables, however, deteriorated during the prednisolone tapering off period. The addition of cyclosporine was not effective. Therefore, pirfenidone at 1200 mg/day was added in conjunction with prednisolone at 10 mg/day. As shown in Figure 2, her FVC was relatively stable during the 12-months pirfenidone treatment period. Although serum KL-6 level elevated from 1410 U/mL to 1530 U/mL, HRCT findings did not significantly change (Figure 3a, b). However, she had to discontinue pirfenidone due to severe appetite loss. A methylprednisolone pulse and cyclophosphamide pulse therapy were repeated but failed to control the disease progression. Pulmonary function tests could not be evaluated due to her deteriorating general condition. Serum KL-6 level increased to 3289 U/mL. Six months after the termination of pirfenidone, she died from chronic respiratory failure with hypercapnia.

### Case 2

A 62-year-old man, a current heavy smoker, diagnosed with IPF 4 years earlier was referred to our institution. He was conscious of a dry mouth for 3

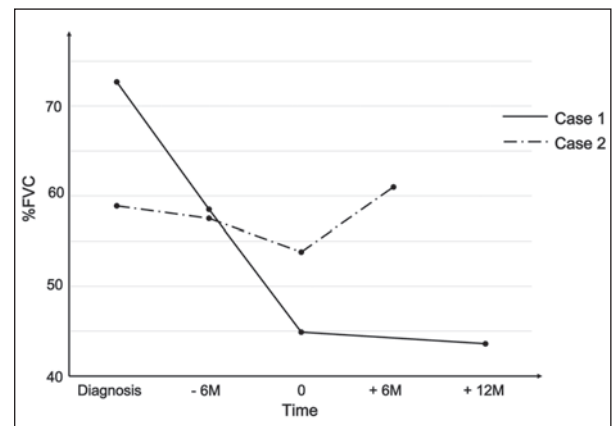
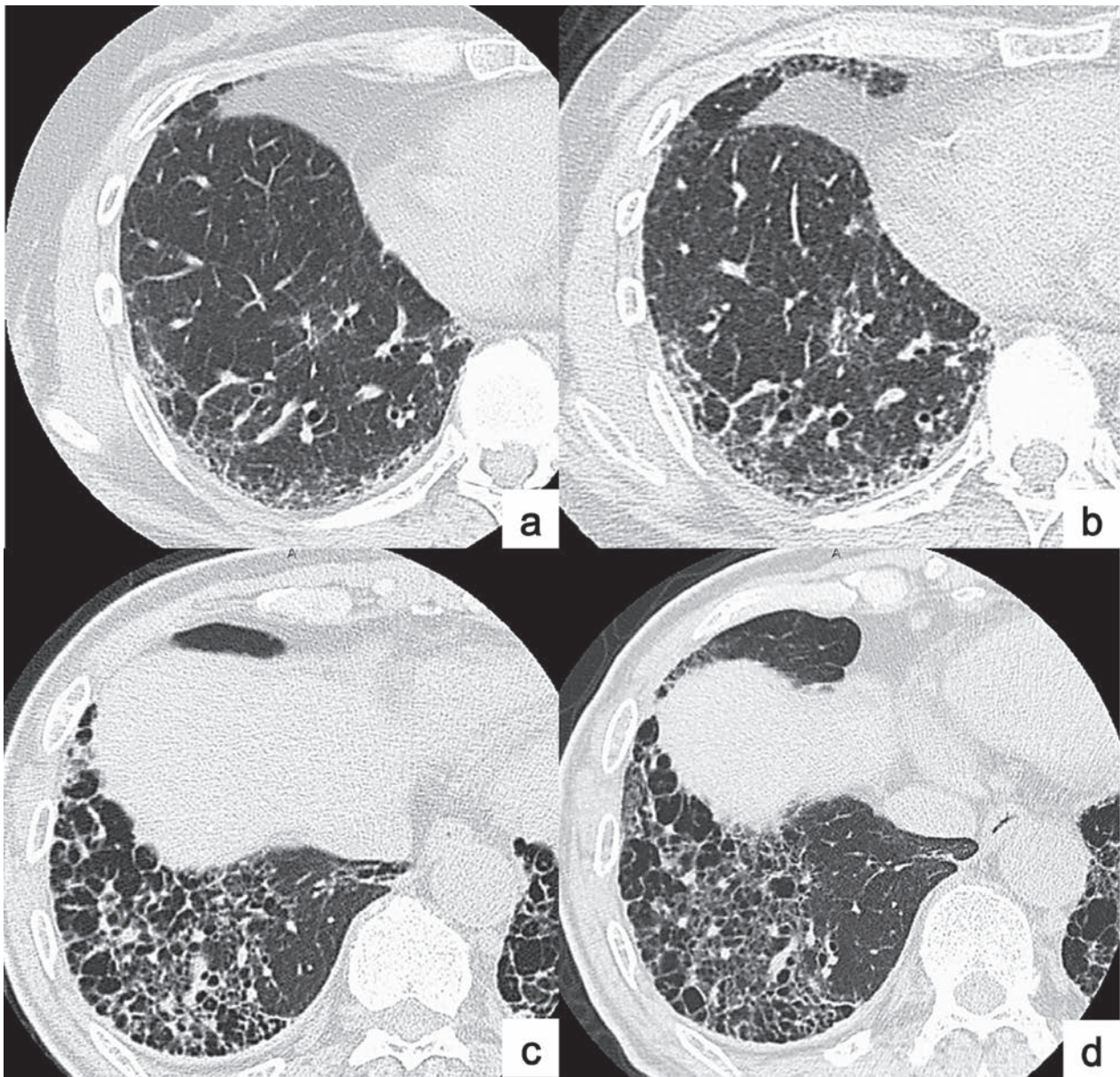


Fig. 2. Changes in forced vital capacity (FVC) before and after pirfenidone administration

years but had no respiratory symptoms. Bibasilar fine crackles were evident on auscultation of both lungs. In laboratory tests, both anti-SS-A/Ro and anti-SS-B/La autoantibodies were positive (titers of 1:256 and 1:8, respectively). The rheumatoid factor was negative and the antinuclear antibody was at a titer of 1:160. Although keratoconjunctivitis sicca was not observed (Rose Bengal test score of 0), lacrimal secretions were significantly decreased (Shirmer's test: right 3 mm; left 3 mm). A minor salivary gland biopsy showed moderate lymphocytic sialadenitis with a focus score of 4. Because there was no clinical evidence of other collagen vascular diseases, he was diagnosed with pSS (13). Serum KL-6 level was high (742 U/mL). On HRCT, bilateral and subpleural honeycombing with ground-glass attenuation were distributed on a background of emphysema (Figure 1c). A surgical lung biopsy at right S<sup>8</sup> revealed an emphysematous change with desquamative interstitial pneumonia-like reaction (Figure 1d). Apparent alveolar fibrosis was not demonstrated, which was thought to be sampling error. Based on the clinical and radiological findings, a multidisciplinary diagnosis of pSS-IP with fibrotic and smoking-related changes was made.

After the diagnosis, he stopped smoking and was followed without any treatment for 8 years. Although ground-glass attenuation on HRCT was decreased, he gradually developed dyspnea on exertion and his FVC deteriorated from 58.9% to 53.8%. Serum KL-6 level was elevated to 962 U/mL. The extent of reticulation with honeycombing increased on HRCT. Therefore, we decided to administer pirfenidone at 1200 mg/day without immunosuppres-



**Fig. 3.** Changes in chest HRCT findings before and after pirfenidone administration. Chest images of case 1 (a: before; b: 12 months after) and case 2 (c: before; d: 6 months after) are shown. There were no significant changes in either case during pirfenidone therapy.

sive drugs. As shown in Figure 2, his FVC was significantly increased 6 months after the pirfenidone administration. In addition, his exercise tolerance improved (6-min walking test: 317 m to 370 m). Serum KL-6 level decreased to 822 U/mL. HRCT findings were almost unchanged (Figure 3c, d). Currently, he continues to receive pirfenidone without any side effects.

## DISCUSSION

This is the first report to suggest that pirfenidone might have a role in the treatment of pSS-IP with fibrotic changes. Although this report was limited because of observation of only two cases and relatively short-term follow-up periods, pirfenidone appeared to reduce disease progression.

Although there are few guidelines for the treatment of pSS-IP, most clinicians would empirically select immunosuppressive therapy particularly for any progressive and/or symptomatic cases. In a previous report, azathioprine alone or in combination with corticosteroids was suggested for improving FVC in patients with pSS-IP, although these patients' pathological patterns were not available (14). In contrast, Perambil et al reported that immunosuppressive therapy was not effective for 3/3 patients with a UIP pattern and 1/5 patients with nonspecific interstitial pneumonia pattern in their cohort of pathologically-proven pSS-IP (2). However, our recent study for pSS-related UIP pattern showed immunosuppressive therapy could control the disease progression in 5/6 patients within 1 year, although long-term efficacy was not found (4). The patient in case 1 in the present report showed such a typical response to immunosuppressive therapy in the pSS-related UIP pattern. The significance of immunosuppression to pSS-IP may be controversial, particularly for cases with UIP pattern or advanced fibrotic changes, which suggests the need for other treatment options.

Pirfenidone has been known to have not only anti-fibrotic but also anti-inflammatory effects by suppressing several inflammatory cytokines, such as tissue necrosis factor- $\alpha$ , interleukin-1 $\beta$  and 6, monocyte chemoattractant protein-1, and interferon- $\gamma$  (15-17). In comparison with IPF, these anti-inflammatory effects may be more favorable for collagen vascular disease-related IP including pSS-IP, in which an inflammatory process plays an important role for pathogenesis. To our knowledge, immunosuppressive adverse complications caused by the anti-inflammatory effects of pirfenidone have been not reported in clinical settings, which would be also beneficial for pSS-IP patients who generally need long-term follow-up and treatment.

As shown in the present two cases and in our recent study (4), the radiological and pathological findings of pSS-IP can mimic those of IPF. Fisher et al examined their 38 patients with IP of unknown causes, who underwent minor salivary gland biopsies, and reported that as many as 13 patients (34%) had focal chronic sialadenitis, suggesting that complete exclusion of pSS is difficult without a minor salivary gland biopsy (18). However, it would be not practical that all the patients having diagnosed with

idiopathic IPs receive a biopsy, particularly for those without the sicca symptom. Therefore, there is the possibility that previous clinical trials of pirfenidone for IPF included patients with subclinical pSS, and the positive results in those trials might be partially applicable even to clinical pSS-IP.

In conclusion, our two cases and literature reviews suggest that pirfenidone may be a promising new treatment option for pSS-IP. Future prospective and large-cohort studies are warranted.

## REFERENCES

- Ito I, Nagai S, Kitaichi M, et al. Pulmonary manifestations of primary Sjögren's syndrome: A clinical, radiologic, and pathologic study. *Am J Respir Crit Care Med* 2005; 171(6): 632-8.
- Parambil JG, Myers JL, Lindell RM, Matteson EL, Ryu JH. Interstitial lung disease in primary Sjögren syndrome. *Chest* 2006; 130(5): 1489-95.
- Enomoto Y, Takemura T, Hagiwara E, et al. Prognostic factors in interstitial lung disease associated with primary Sjögren's syndrome: Analysis of 33 pathologically-proven cases. *PLoS One* 2013; 8(9): e73774.
- Enomoto Y, Takemura T, Hagiwara E, et al. Features of usual interstitial pneumonia in patients with primary Sjögren's syndrome compared with idiopathic pulmonary fibrosis. *Respir Investig* 2014; 52(4): 227-35.
- Raghu G, Rochweg B, Zhang Y, et al. An Official ATS/ERS/JRS/ALAT Clinical Practice Guideline: Treatment of Idiopathic Pulmonary Fibrosis. An Update of the 2011 Clinical Practice Guideline. *Am J Respir Crit Care Med* 2015; 192(2): e3-19.
- King TE Jr, Bradford WZ, Castro-Bernardini S, et al. A phase 3 trial of pirfenidone in patients with idiopathic pulmonary fibrosis. *N Engl J Med* 2014; 370(22): 2083-92.
- Kaneko M, Inoue H, Nakazawa R, et al. Pirfenidone induces intercellular adhesion molecule-1 (ICAM-1) down-regulation on cultured human synovial fibroblasts. *Clin Exp Immunol* 1998; 113(1): 72-6.
- Lee BS, Margolin SB, Nowak RA. Pirfenidone: a novel pharmacological agent that inhibits leiomyoma cell proliferation and collagen production. *J Clin Endocrinol Metab* 1998; 83(1): 219-23.
- Iyer SN, Margolin SB, Hyde DM, Giri SN. Lung fibrosis is ameliorated by pirfenidone fed in diet after the second dose in a three-dose bleomycin-hamster model. *Exp Lung Res* 1998; 24(1): 119-32.
- Antonioni KM, Margaritopoulos GA, Siafakas NM. Pharmacological treatment of idiopathic pulmonary fibrosis: from the past to the future. *Eur Respir Rev* 2013; 22(129): 281-91.
- Miura Y, Saito T, Fujita K, et al. Clinical experience with pirfenidone in five patients with scleroderma-related interstitial lung disease. *Sarcoidosis Vasc Diffuse Lung Dis* 2014; 31(3): 235-8.
- Udwadia ZF, Mullerpattan JB, Balakrishnan C, Richeldi L. Improved pulmonary function following pirfenidone treatment in a patient with progressive interstitial lung disease associated with systemic sclerosis. *Lung India* 2015; 32(1): 50-2.
- Shiboski SC, Shiboski CH, Criswell L, et al. American College of Rheumatology classification criteria for Sjögren's syndrome: a data-driven, expert consensus approach in the Sjögren's International Collaborative Clinical Alliance cohort. *Arthritis Care Res (Hoboken)* 2012; 64(4): 475-87.
- Deheinzlin D, Capelozzi VL, Kairalla RA, Barbas Filho JV, Saldiva PH, de Carvalho CR. Interstitial lung disease in primary Sjögren's

- syndrome. Clinical-pathological evaluation and response to treatment. *Am J Respir Crit Care Med* 1996; 154(3 Pt 1): 794-9.
15. Oku H, Shimizu T, Kawabata T, et al. Antifibrotic action of pirfenidone and prednisolone: different effects on pulmonary cytokines and growth factors in bleomycin-induced murine pulmonary fibrosis. *Eur J Pharmacol* 2008; 590(1-3): 400-8.
  16. Grattendick KJ, Nakashima JM, Feng L, Giri SN, Margolin SB. Effects of three anti-TNF-alpha drugs: etanercept, infliximab and pirfenidone on release of TNF-alpha in medium and TNF-alpha associated with the cell in vitro. *Int Immunopharmacol* 2008; 8(5): 679-87.
  17. Liu H, Drew P, Cheng Y, Visner GA. Pirfenidone inhibits inflammatory responses and ameliorates allograft injury in a rat lung transplant model. *J Thorac Cardiovasc Surg* 2005; 130(3): 852-8.
  18. Fischer A, Swigris JJ, du Bois RM, et al. Minor salivary gland biopsy to detect primary Sjogren syndrome in patients with interstitial lung disease. *Chest* 2009; 136(4): 1072-8.