

CA 15.3: A MARKER OF DISEASE ACTIVITY IN SARCOIDOSIS

Yasemin Türk, Clara Shapiro, Gert-Jan Braunstahl

¹Department of pulmonology and tuberculosis, Franciscus Gasthuis, Rotterdam, The Netherlands

To the editors,

Carbohydrate antigen CA 15.3 is a mucin glycoprotein which is a well-known marker of breast cancer. Elevated levels of CA 15.3 are also found in patients with adenocarcinoma of the lung, pancreas, kidney, ovary and colon (1). Mucin glycoproteins are located on the surface of different epithelial cells and protect the cell against proteolytic enzymes. In malignant tissues, there is an upregulated expression of muc-1 gene resulting in higher concentrations of CA 15.3 in the circulation (1). However, few studies reported an association of CA 15.3 with benign diseases as well, in particular pulmonary fibrosis and advanced stage sarcoidosis (stage III-IV) (2-5). The exact mechanism of this correlation is not clear and this association is unknown by many clinicians. Therefore, we want to present a case in which a history of breast cancer, elevated CA 15.3 levels and lymphadenopathy leads toward a diagnosis of metastatic disease. However, after adequate analysis it turns out to be something else.

We present a 61-year-old woman with a history of breast cancer in 2004, which has been treated with curative intention. In 2012, she presented with symptoms consisting of non-intentional weight

loss, easy fatigability, progressive dyspnoea and non-productive cough. Laboratory results showed only an increased CA 15.3 level of 68 kU/l (n<40 kU/l). CT scan of thorax/abdomen showed bilateral and mediastinal lymphadenopathy as well as multiple small noduli located in both lungs. There was no evidence of recurrence of mamma carcinoma both on CT and mammography. Histological needle biopsy of the mediastinal lymph nodes was performed and unexpectedly, the tissue showed well-formed, non-caseating granulomas without any evidence of malignant disease. Additional laboratory tests showed an increase of the Erythrocyte Sedimentation Rate (ESR) of 71 mm/hr (<20 mm/hr), an angiotensin-converting enzyme level of 31 U/L (5-21 U/L) and lysozyme of 810 kU/L (280-620 kU/L). The Quantiferon test was negative (<0.35 IU/ml). Furthermore, somatostatin scintigraphy demonstrated a typical lambda sign suggestive for sarcoidosis. Based on these findings, the diagnosis sarcoidosis stage II was made. Treatment with corticosteroids (prednisolone 10 mg/day) led to improvement of symptoms and decreased disease activity. The CT-scan showed a reduction in the size of hilar and mediastinal lymph nodes. Laboratory results showed normal levels of calcium (2.43 mmol/l). ACE and CA 15.3 levels decreased within 1 year of follow-up (figure 1). The dose of prednisolone was tapered to 5 mg daily and was stopped after seven months of treatment. After 1 year, the CT-scan showed a significant reduction in hilar and mediastinal lymphadenopathy as well as in the size of the pulmonary lesions.

Our case demonstrates that CA 15.3 can be associated with early stage sarcoidosis. Furthermore CA 15.3 was a potential marker of disease activity

Received: 8 September 2015

Accepted after revision: 29 February 2016

Correspondence: Drs. Yasemin Türk

Department of pulmonology

Franciscus Gasthuis

Kleiweg 500

3045 PM Rotterdam

Tel. 0031-646307929

Fax 0031-104612692

E-mail: y.turk@franciscus.nl

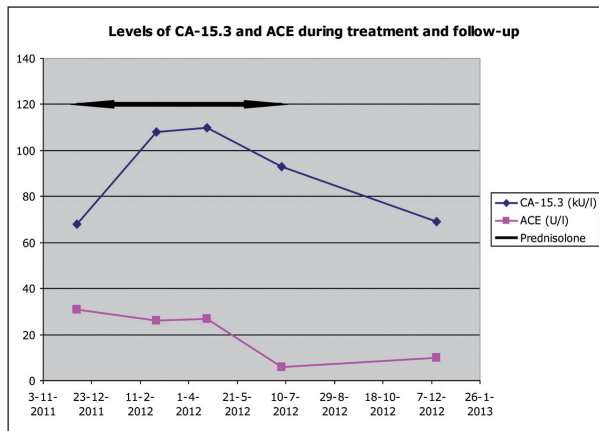


Fig. 1. Levels of CA-15.3 and ACE during treatment and follow-up

in our patient, as CA 15.3 level significantly decreased with reduced disease activity. However, the exact mechanism of the correlation of CA 15.3 with sarcoidosis has to be further investigated. In clinical practice, we have to be aware that an elevated CA

15.3 level in patients with a history of breast cancer is not always associated with recurrence of breast cancer. In these patients, histological confirmation is required to obtain the right diagnosis.

REFERENCES

1. Kamp GJ van, Verstraeten AA, Snijdwint FGM. Ca 15.3 and other MUC1-tests. *Ned Tijdschr Klin Chem* 2001; 26: 24-7.
2. Colomer R, Ruibal A, Genolla J, Rubio D, Del Campo JM, Bodi R, Salvador L. Circulating CA 15-3 levels in the postsurgical follow-up of breast cancer patients and in non-malignant diseases. *Breast Cancer Research and Treatment* 1989; 13: 123-33.
3. Wong RCW, Brown S, Clarke BE, Klingberg S, Zimmerman PV. Transient Elevation of the Tumor Markers Ca 15-3 and CASA as Markers of Interstitial Lung disease Rather than underlying Malignancy in Dermatomyositis Sine Myositis. *Journal of Clinical Rheumatology*; 2002; 8 (4).
4. Ricci A, Mariotta S, Bronzetti E, Bruno P, Vismara L, De Dominicis C, Lagana B, Paone G, Mura M, Rogliani P, Mastrangelo M, Sciacchitano S, Saltini C. Serum Ca 15-3 is increased in pulmonary fibrosis. *Sarcoidosis vasculitis and diffuse lung diseases* 2009; 26: 54-63.
5. Kruit A, Gerritsen WBM, Pot N, Grutters JC, Bosch JMM van den, Ruven HJT. Ca 15-3 as an alternative marker for KL-6 in fibrotic lung diseases. *Sarcoidosis vasculitis and diffuse lung diseases* 2010; 27: 138-46.