

ACUTE EOSINOPHILIC PNEUMONIA AS A COMPLICATION OF INFLUENZA A (H1N1) PULMONARY INFECTION

Jose María Larrañaga¹, Pedro J. Marcos², Francisco Pombo³, Isabel Otero-González²

¹Servicio de Cardiología. Instituto de investigación Biomédica de A Coruña (INIBIC), Complejo Hospitalario Universitario de A Coruña (CHUAC), Sergas. Universidade da Coruña (UDC). As Xubias, 15006, A Coruña, Spain; ²Servicio de Neumología. Instituto de investigación Biomédica de A Coruña (INIBIC), Complejo Hospitalario Universitario de A Coruña (CHUAC), Sergas. Universidade da Coruña (UDC). As Xubias, 15006, A Coruña, Spain; ³Servicio de Radiología. Instituto de investigación Biomédica de A Coruña (INIBIC), Complejo Hospitalario Universitario de A Coruña (CHUAC), Sergas. Universidade da Coruña (UDC). As Xubias, 15006, A Coruña, Spain, Radiology Department. Complejo Hospitalario Universitario de A Coruña (CHUAC). SERGAS. A Coruña, Spain

INTRODUCTION

Acute eosinophilic pneumonia (AEP) is a rare disease characterized by its acute onset and a clinical presentation simulating a bacterial pneumonia. It can be idiopathic (when there is absence of determined cause) or secondary to use of drugs, toxic agents, parasitic infection or other infectious causes. Influenza related complications are mostly respiratory and includes bacterial pneumonia or acute respiratory distress syndrome (ARDS). We describe a cause of a middle age patient who had a severe influenza A (H1N1) pneumonia requiring ICU admission with persistent dyspnea and severe hypoxemia with rapid radiological progression, which its ultimate cause was an eosinophilic pneumonia confirmed by bronchoalveolar lavage (BAL). We suggest that in the context of a nonresolving influenza A(H1N1) pneumonia, AEP should be suspected.

CASE PRESENTATION

A 60-year old man was admitted to our hospital with a 2 weeks episode of asthenia, rapidly progressive dyspnea, fever (38°C) and increased in sputum production. He had no history of smoking or drug use, except for alcohol abuse of 70 gr per day, and he had not travelled in the last year. His medical story was unremarkable except for bicuspid aortic valve and mild stenosis. He had taken esomeprazole and tamsulosine since few years ago for benign prostatic disease and gastric reflux. Chest auscultation revealed inspiratory crackles in both lower lung fields. A chest radiograph showed bilateral alveolointerstitial infiltrates (Figure 1A). The patient's arterial blood gases with $\text{FiO}_2=0.50$ was pH 7.61, PaCO_2 33 mmHg, PaO_2 6 mm Hg and 91% O_2 saturation. The results of other laboratory test showed 8.97×10^9 leucocytes with normal differential account, and elevation of transaminases and cholestasis enzymes. Patient received empiric antibiotic treatment with levofloxacin. Blood, urine cultures and antigen for pneumococci and legionella was negative. A throat swab for real-time reverse transcriptase-PCR (RT-PCR) test for 2013 Influenza A (H1N1) was positive. Patient was admitted to the Intensive Care Unit (ICU) where he re-

Received: 17 March 2015

Accepted after revision: 19 March 2015

Correspondence: Pedro J Marcos, MD

Servicio de Neumología

Complejo Hospitalario Universitario de A Coruña,

A Coruña, Spain

Tel. +34981178000

E-mail: pedro.jorge.marcos.rodriguez@sergas.es

quired support with noninvasive mechanical ventilation (NIMV) and ceftriaxone, azithromycin and oseltamivir (75mg twice a day) were initiated. Five days later, and after stabilization, patient was transferred to our intermedios respiratory care unit.

During the days following admission to our unit, patient persisted with severe hypoxemia and a chest radiograph showed further aggravation with multiple alveolointerstitial radiopacities. A Computerized Tomography (CT) scan was done, revealing peripheral ill-defined ground-glass opacities and mild right pleural effusion (Figure 1B). We performed a BAL with a differential account of 34% eosinophils, 30% lymphocytes and 4% polymorphonuclear leucocytes. BAL cultures for virus and bacteria were negative. We repeated blood test which showed no peripheral eosinophilia, and we also tested for atypical pneumonia serologies, PCR HIV-1, serum total immunoglobulin (Ig) E and parasitic infection which all were negative. Finally we made a spirometry with forced vital capacity (FVC) 49.5%, forced expiratory volume at first second (FEV1) 53.8%, FEV1/FVC 85.76% and carbon monoxide diffusion (DLCO) 30.7%. Acute eosinophilic pneumonia diagnosis was made based on the AEP criteria [1] and prednisone was pre-

scribed (60 mg a day). After the patient started taking prednisone his symptoms improved quickly, hypoxemia get better and he underwent discharge to home. In a scheduled visit in our outpatient clinic, patient presented with a favourable clinical evolution and a complete resolution of functional and radiological features (Figure 1C).

DISCUSSION

Eosinophilic pneumonias includes a variety of lung diseases characterized by an infiltration of the parenchyma by eosinophil (1). AEP is an acute illness that may lead to respiratory failure and it is characterized by an increase in BAL eosinophils. Although it can be idiopathic, AEP has been related with toxic agents, radiation, allergic bronchopulmonary aspergillosis, infections and drug use. Most of drugs include antibiotics and non-steroidal anti-inflammatories, and the list can be found online (www.pneumotox.com). Although it has been linked with infections (*Aspergillus*, *Coxsackie A2*, *Pseudomonas*), most of the cases were associated with parasitic infections or AIDS (2). In the present case we excluded causes of potential AEP and pa-

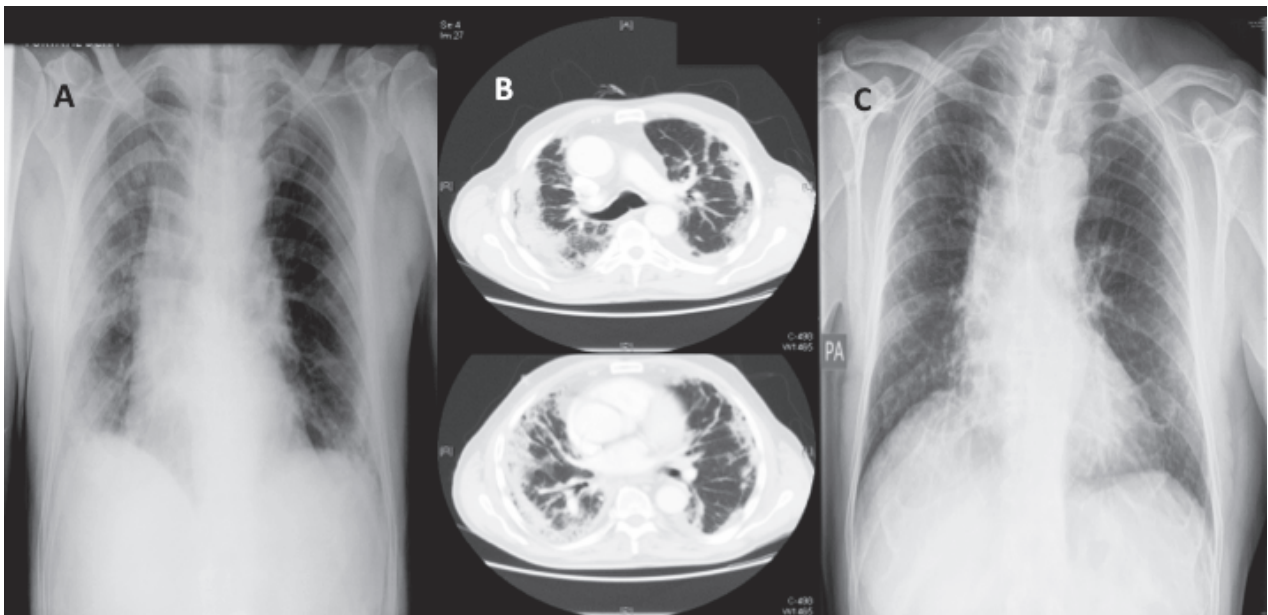


Fig. 1. A: Chest X-Ray showing bilateral alveolointerstitial infiltrates. B: CT scan showing ill-defined ground-glass opacities and mild right pleural effusion. C: Chest X-Ray showing a complete resolution of the infiltrates

tient had not taken any of drugs related with. We also excluded parasite, HIV and bacterial infection, so the only possible cause of AEP was the influenza A (H1N1) infection. After a review of the literature we have only found one case of an AEP associated with influenza(H1N1), in this case during the 2009 epidemic (3).

Influenza A (H1N1) virus can cause pulmonary complications as pneumonia and ARDS in healthy persons. This seasonal virus has risen as a highly infective and virulence strain, with many cases of severe viral pneumonia, ARDS and other complications. Diagnosis is based using a RT-PCR test of a swab obtained from the upper respiratory tract, with a sensibility of 81%. RT-PCR in lower respiratory tract specimen is recommended in cases with severe pneumonia that are intubated or undergoing bronchoscopy, with a high sensibility. Treatment is based on oseltamivir, especially in the first 48 hours and in severe cases (4) . In our case, RT-PCR of the upper respiratory tract confirmed the infection and specific treatment with oseltamivir was prescribed after we received the microbiological results. When the BAL was performed the patient had been received the fully treatment with oseltamivir which could justify the RT-PCR negative results on BAL.

Diagnosis of AEP is based in clinical-radiological features and alveolar and/or peripheral eosinophilia and diagnosis criteria has been proposed (1). This last one is typically absent on the presentation of acute disease. A cut-off of >25% eosinophils in BAL has been recommended for AEP, and >40% for CEP. Radiological features in-

clude bilateral infiltrates, with alveolointerstitial opacities, frequently migratory, and up to a 66% have bilateral pleural effusion. Lung function test on AEP may show a restrictive pattern with reduced transfer factor, as our case. Treatment is based on steroids and the response is dramatic with fast resolution of the clinical and radiological findings, with rare relapsing episodes. It is recommended 40-60 mg of prednisone daily for 2-4 weeks or until full resolution. Although recently it have been published a case related to influenza vaccination (5), this is to our knowledge the second report of AEP related with Influenza A (H1N1) pneumonia. We think that influenza A (H1N1) should be considered as cause of AEP, and this diagnosis be suspected when the viral infection resolves slowly or has radiography changes as our case and in these situations the BAL will be very useful to help the clinicians to address this questions.

REFERENCES

1. Cottin V, Cordier J-F. Eosinophilic pneumonias. *Allergy* 2005 ;60: 841-57.
2. Glazer CS, Cohen LB, Schwarz MI. Acute eosinophilic pneumonia in AIDS. *Chest* 2001; 120: 1732-5.
3. Jeon EJ, Kim KH, Min KH. Acute eosinophilic pneumonia associated with 2009 influenza A (H1N1). *Thorax* 2010; 65: 268-70.
4. Labella AM, Merel SE. Influenza. *Med Clin North Am* 2013; 97: 621-45.
5. Pornsuriyasak P, Suwatanapongched T, Jettanong Klaewsongkram J, Buranapraditkun S, Rotjanapan P. Acute respiratory failure secondary to eosinophilic pneumonia 4 following influenza vaccination in an elderly man with chronic 5 obstructive pulmonary disease. *Int J Infect Dis*, 2014; 26: 14-16.