

## NEUROSARCOIDOSIS PRESENTING AS TRIGEMINAL NEURALGIA: A CASE REPORT AND REVIEW OF THE LITERATURE

S. Braksick<sup>1</sup>, S. Shah-Haque<sup>1</sup>, B. El-Haddad<sup>1</sup>, R. Moussa<sup>2</sup>

<sup>1</sup>University of Kansas School of Medicine-Wichita, Department of Internal Medicine; <sup>2</sup>University of Kansas School of Medicine-Kansas City, Department of Internal Medicine

**ABSTRACT.** Sarcoidosis is a granulomatous disease that can present systemically, but primarily has pulmonary manifestations. It is reported across all races, but has a higher incidence among African Americans. Neurological involvement in sarcoidosis is rare, with cranial nerve seven being the most commonly reported neurological finding. Trigeminal neuralgia, as presented in this case, is very rare. A 38-year-old African American female, with history of refractory trigeminal neuralgia, cutaneous sarcoidosis, and an extensive psychiatric history, presented to the hospital for fifth cranial nerve decompression. She had failed medical therapy and gamma knife therapy. Prior to surgery, magnetic resonance imaging (MRI) revealed a mass of 1.5 cm x 0.6 cm x 1.1 cm in the left Meckel's cave, which, when compared with prior imaging, was not present. A partial craniotomy was done to excise the mass. Frozen pathological sections showed granulomatous inflammation consistent with sarcoidosis. Stains for acid fast bacilli and fungi remained negative. Quantiferon Gold and HIV serum studies were negative. High resolution computed tomography (CT) scan the chest showed patchy infiltrates in the lungs that presented as chronic interstitial lung disease. The patient's neurological symptoms resolved after surgical resection. She was dismissed home on a tapering dose of dexamethasone and follow-up with a rheumatologist. This case illustrates that when a patient with sarcoidosis presents with neurological symptoms, neurosarcoid should be considered. Most cases are diagnosed during autopsies. Recognizing and correctly diagnosing neurosarcoid leads to proper treatment and decreased morbidity in patients. (*Sarcoidosis Vasc Diffuse Lung Dis* 2013; 30: 153-156)

**KEY WORDS:** trigeminal neuralgia, sarcoidosis, neurosarcoidosis

### INTRODUCTION

Sarcoidosis is a granulomatous, systemic disease, manifesting primarily in the lungs (1-3). It manifests usually in the range of 20-40 years of age (2, 3) with an incidence three times greater in African Americans than white Americans (3). Neurological involvement is rare, appearing in 5-10 percent of all patients diagnosed with sarcoidosis (1, 3, 4). Only half of neurosarcoidosis

cases are reported premortem (3). Seventh nerve cranial involvement is the most common neurological finding of neurosarcoid (1) while fifth nerve neuralgia (trigeminal neuralgia) is a rare finding. We report the case of a young African American female with trigeminal neuralgia secondary to neurosarcoidosis.

### HOSPITAL COURSE

Eleven months prior to admission, a 38 year-old African American woman presented to an outpatient clinic with constant 'electric, shock-like' sensations traveling through her left eye and left cheek over the zygomatic arch. A magnetic resonance

Received: 8 July 2012

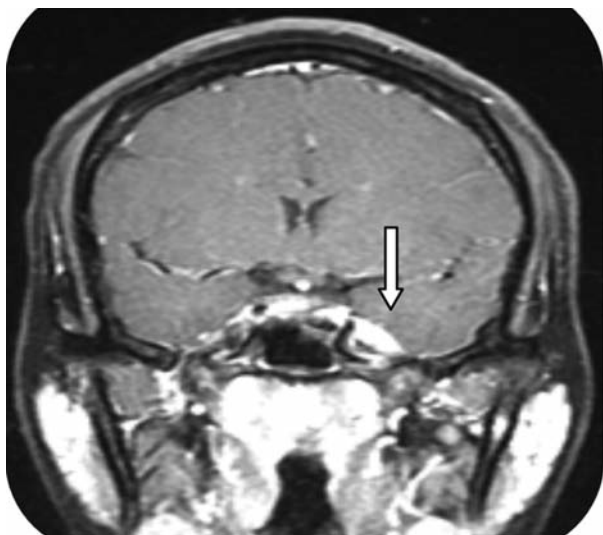
Accepted after Revision: 21 August 2012

Correspondence: Sapna Shah-Haque, M.D., M.B.A.

University of Kansas School of Medicine-Wichita,

Department of Internal Medicine

E-mail: Sshah2@kumc.edu



**Fig. 1.** Magnetic resonance imaging T1 with gadolinium demonstrating an enhancing lesion in the region of Meckel's Cave on the left

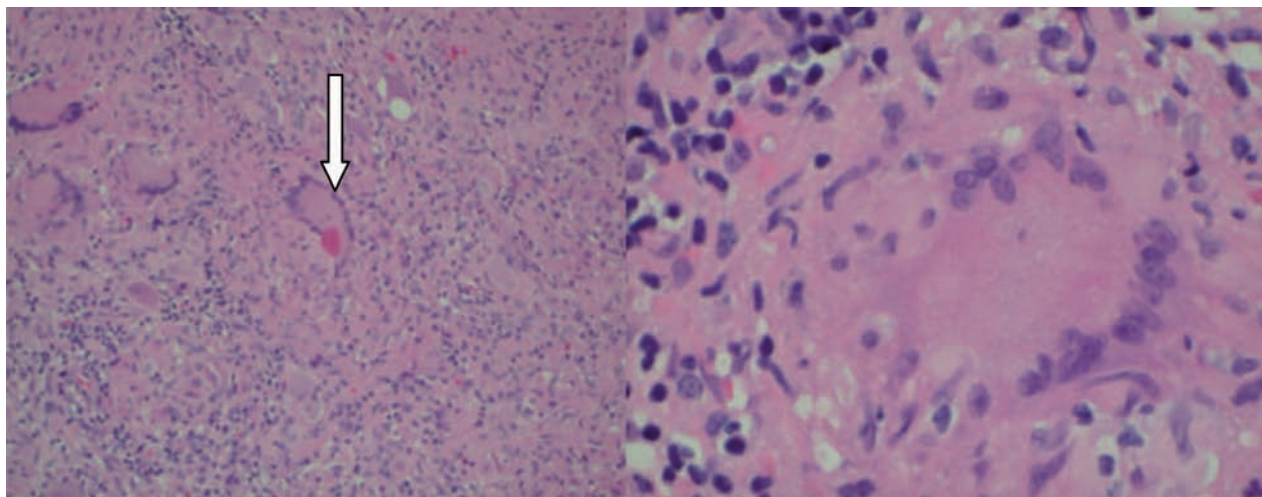
imaging (MRI) of the brain was negative for a lesion that could explain her symptoms. She was unable to drink cold liquids and endured constant stabbing, shocking pain. At times she was unable to sleep on her left side secondary to increased irritation. She had seen several physicians, and was diagnosed clinically with trigeminal neuralgia. Her pain became refractory to neuropathic pain medications, including carbamazepine, gabapentin, and amitriptyline. She underwent gamma knife treatment without success.

She presented to the hospital with intractable pain, and was scheduled for left trigeminal nerve decompression.

Her pain was partially controlled with multiple agents. An MRI of the brain was repeated, which revealed a 1.5 cm x 0.6 cm x 1.1 cm contrast-enhancing mass in Meckel's cave on the left (Figure 1). When the most recent MRI was compared with the initial MRI it was found that the initial imaging showed no abnormal enhancement or masses. An angiotensin-converting enzyme (ACE) was ordered on serum, and was 27 U/L (reference range 8-53 U/L). A Quantiferon Gold and Human evaluate for (HIV) antibody were ordered to exclude tuberculosis or possibility for opportunistic infection; both of which were negative. C-ANCA was 17 U/ml (0-99 reference range) and P-ANCA was slightly elevated at 111 U/ml (0-99 reference range).

The patient underwent a partial craniotomy for mass removal, which was sent to pathology as frozen sections and for histologic staining and review. Frozen sections were identified as granulomatous inflammation. Histologic staining for acid fast bacilli and fungi were negative, as well as cultures. The official pathology report was read as ganglion and nervous tissue with granulomatous inflammation, dystrophic calcification, and was found to be consistent with sarcoidosis (Figure 2).

Upon further investigation, the patient had been diagnosed with sarcoidosis three years prior via



**Fig. 2.** Low-power image of resected tissue demonstrating inflammatory cells with multinucleate giant cells, characteristic of granuloma formation. (Left) High-power image of multinucleate giant cell. (Right)

skin lesion removal on her left eyelid. Based on the findings and past medical history, a plain chest radiograph was done, and showed chronic interstitial lung markings. For further evaluation, a high resolution computed tomography (CT) of the chest was done, and it showed scattered patchy, infiltrates most prominently seen in the upper lobe of the right lung. Both findings on chest imaging were suspicious for sarcoidosis with pulmonary involvement. The patient's neurological manifestations resolved post-operatively. She was discharged on dexamethasone with scheduled follow up with her primary care physician and a rheumatologist.

## DISCUSSION

Neurologic manifestations of sarcoidosis are rare, affecting 5 to 13% of patients with known sarcoidosis (1-4).

At autopsy, the incidence of neurosarcoidosis may be as high as 25% (2).

The manifestations of systemic sarcoidosis most commonly affect the lungs (2, 5). Other commonly affected organ systems include the eyes and skin (1, 2). Once the diagnosis of systemic sarcoidosis is made, neurosarcoidosis typically presents within the next two years (1).

As systemic sarcoidosis has typical presentations, neurologic manifestations commonly affect specific areas of the brain and spinal column. The cranial nerves are most commonly affected (4-6), with the facial nerve being the most frequently involved (1, 4, 5, 7-10) followed by the optic nerve (1, 7-10). Involvement of the trigeminal nerve is rare, with only scant case reports of patients presenting with trigeminal neuralgia (4, 8, 10), for which the differential diagnosis should also include compression secondary to a cyst, tumor (benign or malignant), vascular loop, or presentation of multiple sclerosis (11). Other cranial nerves sometimes involved in neurosarcoidosis include the oculomotor, vagus and hypoglossal nerves (8, 12), as well as one case report of complete ophthalmoplegia secondary to a cavernous sinus lesion (1).

Many other neurologic manifestations have been attributed to sarcoidosis, and include seizure, (3, 13) leptomeningitis, (8) hydrocephalus, (7) spasticity, (14) and ataxia (3). Executive functions, such

as slowed information processing, memory impairment, and deficits in expressive language, indicate some degree of frontal lobe dysfunction, and have been attributed to sarcoidosis (15).

Diagnosis of neurosarcoidosis can sometimes be difficult, as lesions seen on imaging may suggest sarcoidosis, but do not rule out other, particularly infectious, etiologies. In addition, lesions may be visualized, but may not be easily accessed by neurosurgical intervention for definitive diagnosis. As a result, patients with known systemic sarcoidosis diagnosed by biopsy from another organ system may be treated for neurosarcoidosis once other causes have been ruled out (2, 12).

The simultaneous occurrence of both systemic and neurologic sarcoidosis is not uncommon, with anywhere from 28 to 97% of patients presenting with neurologic symptoms having evidence of systemic disease as well (4, 9, 10). The most common site in addition to the central nervous system was the respiratory system (4, 9).

Laboratory evaluation for evidence of sarcoidosis is limited. Serum angiotensin converting enzyme (ACE) is elevated in 29 to 60% of patients, but its absence does not exclude the diagnosis of sarcoidosis (2, 3). In addition, erythrocyte sedimentation rate (ESR) may be elevated in up to 23% of cases (3). Cerebral spinal fluid (CSF) analysis is not diagnostic itself, but evaluation for infectious agents (tuberculosis, fungi), differential cell count, and ACE can exclude other etiologies as well as support the diagnosis of neurosarcoïd (2, 8).

Magnetic resonance imaging (MRI) is commonly used with the onset of new neurologic symptoms. Lesions proven to be granulomatous lesions attributed to sarcoidosis have some common characteristics, with leptomeningeal or parenchymal enhancement being present in the majority of cases (3, 5). Lesions can affect the brain or spinal cord parenchyma as well as cranial nerve nuclei (3). One such case report demonstrated imaging essentially identical to our patient's radiographic findings (5). Other sites sometimes affected include the hypothalamus and pituitary (8).

In one study, the lesions identified on MRI were followed throughout the course of treatment, and suggest that MR lesions resolve as clinical symptoms subside as well (10).

The gold standard of diagnosis of sarcoid involving any body system is histologic examination.

The classic histologic characteristic is non-caseating granuloma in the absence of microorganisms (2). If the location of a suspicious lesion within the central nervous system precludes biopsy, diagnosis may be made by clinical and radiographic evidence combined with histologic diagnosis from another organ system (2).

Treatment options for patients with neurosarcoid are numerous. The mainstay of initial therapy, once diagnosis has been confirmed is steroids (2, 4, 6, 8). The initiation of therapy for sarcoidosis is recommended when organ function becomes impaired. Clinical response should be monitored every one to three months and the dosage of steroid tapered as symptoms allow (2, 4, 8). Total duration of treatment with steroids should typically last nine to twelve months, as short course therapy has not been found to be beneficial (2).

Approximately 33% of patients may be refractory to steroid therapy (8). In these cases, immunomodulators such as methotrexate, hydroxychloroquine, cyclophosphamide, and anti-tumor necrosis factor medications may be used, or radiation to lesions has also shown to be beneficial in some cases (8).

The success of each treatment modality varies from patient to patient, but overall improved morbidity has been seen. For patients with neurosarcoidosis treated with steroids, 29% showed improved symptoms, 61% improved with methotrexate, and 90% of patients treated with cyclophosphamide improved as well (6).

The success of treatment can be monitored with imaging. Serial MRI examinations have shown improvement in existing lesions that correlate with improved clinical symptoms in patients undergoing treatment (2, 10) and allow for an objective measure of response to treatment.

Overall outcome following treatment in patients with neurosarcoidosis can be predicted based on clinical symptoms. Involvement of the optic nerve, as well as the vestibulocochlear nerve, has been shown to have a poorer response to therapy when compared to other involved cranial nerves (9). Myelopathy is also a poor prognostic indicator in neurosarcoidosis (3).

The overall mortality for sarcoidosis is estimated to be less than five percent, with the most com-

mon causes being pulmonary fibrosis, cardiac conditions, or neurologic causes (2).

## CONCLUSION

While the incidence of trigeminal neuralgia in neurosarcoidosis is rare, there are no typical neurological presentations of sarcoidosis. Patients with evidence of systemic sarcoidosis with onset of neurologic symptoms should be evaluated for development of CNS sarcoidosis, as well as sequelae of long-term immunosuppressive therapy. Though a definitive diagnosis can be difficult to make, the treatment can provide relief to the patient and prevent significant morbidity.

## REFERENCES

1. Chang CS, Chen WL, Chien-Te L, Wang P Y. Cavernous sinus syndrome due to neurosarcoidosis: a case report. *Acta Neurol Taiwan* 2009; 18: 37-41.
2. Iannuzzi MC, Rybicki BA, Tierstein AS. Sarcoidosis *N Engl J Med* 2007; 357: 2153-65.
3. Joseph FG, Scolding NJ. Neurosarcoidosis: a study of 30 new cases. *J Neurol Neurosurg Psychiatry* 2009; 80: 297-304.
4. Stern BJ, Krumholz A, Johns C, Scott P, Nissim J. Sarcoidosis and its neurological manifestations. *Arch Neurol* 1985; 42: 909-17.
5. Arias M, Iglesias A, Vila O, Brasa J, Conde C. MR Imaging findings of neurosarcoidosis of the gasserian ganglion: an unusual presentation. *Eur Radiol* 2002; 12: 2723-5.
6. Lower EE, Broderick JP, Brott TG, Baughman RP. Diagnosis and management of neurological sarcoidosis. *Arch Intern Med* 1997; 157: 1864-8.
7. Lee CH, Sub Jung Y, Hyung Lee, S. Hydrocephalus as a presenting manifestation of neurosarcoidosis: easy to misdiagnosis as tuberculosis. *J Korean Neurosurg Soc* 2010; 48: 79-81.
8. Vargas DL, Stern BJ. Neurosarcoidosis: diagnosis and management. *Seminars in Respiratory and Critical Care Medicine* 2010; 31: 419-27.
9. Pawate S, Moses H, Sriram S. Presentations and outcomes of neurosarcoidosis: a study of 54 cases. *QJ Med* 2009; 102: 449-60.
10. Shah R, Roberson GH, Cure JK. Correlation of MR Imaging findings and clinical manifestations in neurosarcoidosis. *Am J Neuroradiol* 2009; 30: 953-61.
11. Bennetto L, Nikunj KP, Fuller G. Trigeminal neuralgia and its management. *BMJ* 2007; 334 (7586): 201-5.
12. Erer-Ozbek S, Bora I, Yurtogullar S. Acute multiple cranial neuropathy in a patient with neurosarcoidosis. *Neurol Sci* 2010; 31: 865-6.
13. Besur S, Bishnoi R, Talluri SK. Neurosarcoidosis: rare initial presentation with seizures and delirium. *QJ Med* 2010.
14. Roopesh Kumar VR, Gopalakrishnan MS, Shankar Ganesh CV, Singh Negi V, Elangovan S. Neurosarcoidosis: an unusual presentation. *Neurol India* 2010; 58: 673-5.
15. Ruocco AC, Lacy M. Neuropsychological findings in a case of neurosarcoidosis. *J Neuropsychiatry Clin Neurosci* 2010; 22: E36.