

## HERMANSKY PUDLAK SYNDROME AND PULMONARY ALVEOLAR PROTEINOSIS AT THE SAME PATIENT: FIRST CASE REPORT IN THE WORLD LITERATURE

E. Ozyilmaz<sup>1</sup>, S. Gunasti<sup>2</sup>, Y. Kuyucu<sup>3</sup>, S. Polat<sup>3</sup>, D. Gumurdulu<sup>4</sup>, S. Kuleci<sup>1</sup>, I. Hanta<sup>1</sup>, A. Kocabas<sup>1</sup>

<sup>1</sup>Cukurova University Faculty of Medicine Department of Pulmonary Diseases; <sup>2</sup>Cukurova University Faculty of Medicine Department of Dermatology; <sup>3</sup>Cukurova University Faculty of Medicine Department of Histology and Embryology; <sup>4</sup>Cukurova University Faculty of Medicine Department of Pathology

**ABSTRACT.** Hermansky-Pudlak Syndrome (HPS) is a rare autosomal recessive disorder presenting with oculocutaneous albinism, bleeding diathesis and lysosomal accumulation of ceroid lipofuscin which leads to interstitial fibrosis in lung. Pulmonary fibrosis which is usually associated with HPS-1 and HPS-4 subtypes usually manifests in the third/fourth decades of life representing with giant lamellar bodies of alveolar type-II-cells and their apparent degeneration causes restrictive lung disease. Pulmonary manifestation of this syndrome may lead to premature death. Pulmonary Alveolar Proteinosis (PAP) is another rare disease characterized by alveolar deposition of surfactant phospholipids and proteins secondary to defective clearance by alveolar macrophages. PAP may occur as autoimmune diseases and/or secondary to toxic inhalation, systemic infections or hematological disorders. None of the cases were reported secondary to HPS according to the best our knowledge. As well, pulmonary involvement of HPS was never reported as PAP. We report the first case of PAP in a patient with HPS. (*Sarcoidosis Vasc Diffuse Lung Dis* 2013; 30: 217-220)

**KEY WORDS:** Sarcoidosis, Pulmonary alveolar proteinosis, case report

### INTRODUCTION

Hermansky Pudlak Syndrome (HPS) is an autosomal recessive disorder characterized by a classic triad of oculocutaneous albinism, bleeding diathesis due to platelet storage pool defect and lysosomal accumulation of ceroid lipofuscin which leads interstitial fibrosis in lung (1). HPS-1 and HPS-4 subtypes

were reported as having the most frequent pulmonary involvement (2, 3). Pulmonary fibrosis associated with HPS-1 is known as a progressive interstitial lung disease which usually manifest in the third and fourth decades of life (4, 5). Gruson et al reported one case of HPS with pulmonary sarcoidosis however no pulmonary alveolar proteinosis (PAP) was defined in patients with this syndrome (6).

PAP is a rare disease characterized by alveolar deposition of surfactant phospholipids and proteins due to defective clearance by alveolar macrophages (7). The vast majority of PAP occurs as autoimmune diseases and/or secondary to toxic inhalation, systemic infections or hematological disorders (7, 8). According to the best our knowledge, none case as reported secondary to HPS. As well, pulmonary in-

Received: 29 August 2012

Accepted after Revision: 22 October 2012

Correspondence: Dr. Ezgi Ozyilmaz

Cukurova University Faculty of Medicine

Department of Pulmonary Diseases,

Balcali, Adana, Turkey

Tel. 0090 505 384 1435

Fax 0090 322 338 7760

E-mail: ezgiozyilmaz@hotmail.com

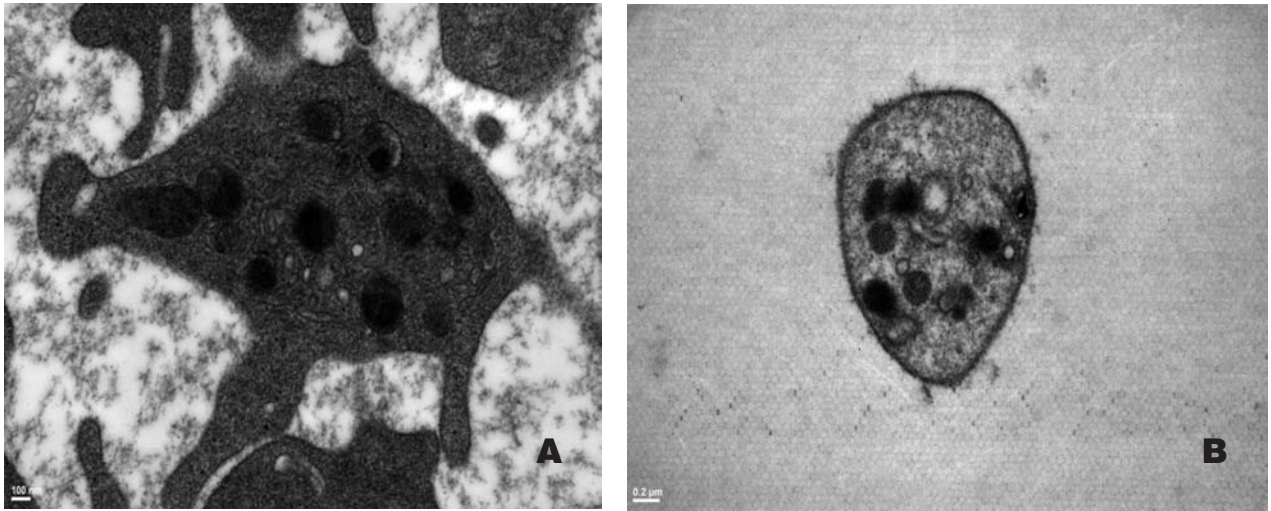
involvement of HPS was never reported as PAP. Herein, we report the first case of PAP in a patient with HPS.

### CASE REPORT

Twenty nine year old male patient was admitted with exercise induced gradually increasing dyspnea for two months. He was otherwise asymptomatic. He had a 14-packet year of smoking history and had no occupational, environmental exposure to known organic or inorganic particles or no history of any drug use. Past medical history revealed frequent epistaxis and gingival bleeding. On physical examination, the vital signs were normal. Albinism, nystagmus and visual defect were present on inspection. Pulmonary examination and laboratory investigations were normal. Chest radiography revealed bilateral diffuse ground glass opacity, reticular infiltration predominantly at the left lung and lower lung zones (Figure 1). High resolution computerized tomography (HRCT) showed bilateral diffuse interlobular septal thickening with extensive ground glass opacity and geographical pattern which were more prominent at the left lung and basal segments of lower lobes. The peripheral lung was commonly spared. Respiratory function tests were normal except decreased residual volume and carbon monoxide diffusing capacity (DLCO=60 mmol/min/kPa). Arterial blood gas analysis and alveoloarterial oxygen gradient ( $p_{A-a}O_2$ ) were normal. Eye examination revealed albino fundus, horizontal nystagmus and visual defect. HPS was considered as initial diagnosis thought at the patient. Platelets from the patient were examined and compared with a control by transmission electron microscopy (Jeol JEM 1400) and the diagnosis was confirmed. The typical appearance of dense granules with dens bodies inside of them were apparent in control platelets, but dens bodies in electron dense granules were not visible in platelets from the patient (Figure 2). As the patient refused to be performed fiberoptic bronchoscopy, no evidence was obtained. Since the HRCT findings were inconsistent with interstitial fibrosis due to HPS, the patient underwent open lung biopsy. The histopathologic examination was reported as "microscopically alveoli and terminal airway spaces are filled with a fine eosinophilic material that stains strongly with PAS. The alveolar wall and interstitial architec-

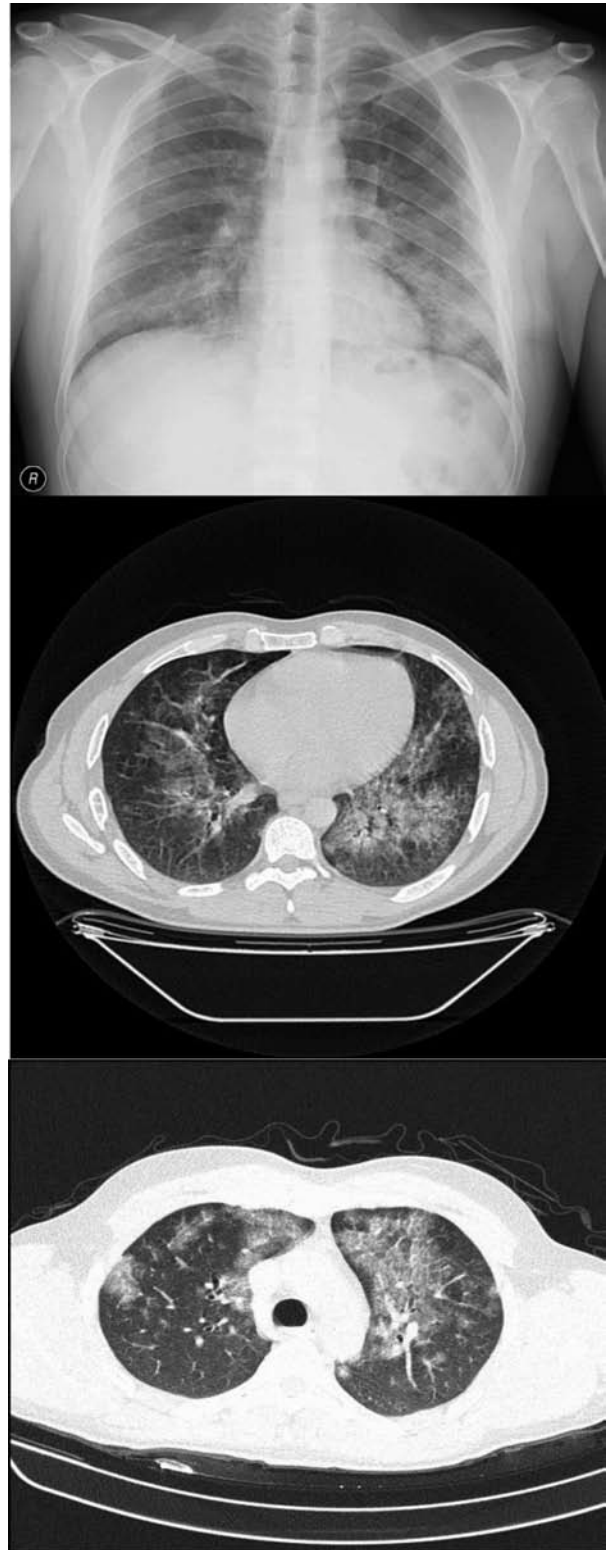

Fig. 1. Chest X-ray and computerized tomography of the patient




**Fig. 2.** Electron microscopic photography of platelets. A. control Bar= 100 nm. B. patient  $\mu\text{m}$ . which demonstrates the decreased number of electron dense bodies with the absence of electron dense granules inside Bar= 0, 2  $\mu\text{m}$ .

ture are well preserved" (Figure 3). PAP was reported as final pathologic diagnosis.

## DISCUSSION

Pulmonary fibrosis is the most serious complication of HPS which accounts significant mortality and morbidity. HRCT is more sensitive than chest

radiography for diagnosis. The radiographic appearance of pulmonary fibrosis in HPS reveals bilateral and symmetrical reticulonodular interstitial pattern, perihilar fibrosis, ground glass opacities and peribronchovascular thickening (9). In our patient, the radiographic pattern was atypical for HPS whereas the extensive ground glass opacities were more prominent at the left lung with central localization accompanying with typical crazy paving pattern and



**Fig. 3.** Lung biopsy showing alveoli filled with eosinophilic amorphous material; the intra-alveolar material shows cleft-like spaces (HE: 200X)

without any significant interlobular or peribronchovascular septal thickening. Thus, open lung biopsy was performed in order to obtain the certain diagnosis. The outcome of the disease varies according to the severity. Steroid therapy is ineffective and there has been one successful lung transplant performed to date (10). A promising agent pirfenidone showed to slow the progression of the disease in a number of preliminary studies but it does not eradicate the disease, completely (11, 12).

PAP is a rare and potentially treatable disease. Autoimmune PAP is characterized by high levels of GM-CSF antibodies (8). The standard care of PAP is whole lung lavage. Alternative therapies include GM-CSF supplemental therapy, rituximab and plasmapheresis (6). We have decided to follow up the patient since he did not have severe dyspnea, hypoxemia or abnormal  $p_{A-a}O_2$  (13).

Pathophysiology of PAP in HPS is still remains to be elucidated. It is possible that high levels of GM-CSF auto antibodies resulting in myeloid dysfunction and surfactant clearance impairment from ceroid filled macrophages may be the pathophysiological underlying link between HPS and PAP (14). This hypothesis may be supported with a previous report of Nakatani et al which immunohistochemically showed an over accumulation of surfactant in lung tissues of autopsy material in patients who died from HPS. These results were concluded as the presence of a basic defect in the formation/secretion process of surfactant by the type-2 pneumocytes in HPS, which may be the triggering factor for the lung involvement of HPS development (15).

In conclusion, we reported the first case of HPS with PAP in the world literature according to the best our knowledge. Although PAP is not a common clinical scene in patients with HPS and HPS is not a reported cause of secondary PAP, it should be kept in mind that PAP may be present in the lungs of the patients with HPS especially with atypical radiographic appearance.

#### ACKNOWLEDGEMENTS

The authors disclose any financial and personal relationships with other people or organization which may af-

fect the present work. We thank our patient for giving written permission to present this work.

#### REFERENCES

- Pierson DM, Ionescu D, Qing G, et al. Pulmonary fibrosis in hermansky-pudlak syndrome. a case report and review. *Respiration* 2006; 73 (3): 382-95.
- Santiago Borrero PJ, Rodriguez-Perez Y, Renta JY, et al. Genetic testing for oculocutaneous albinism type 1 and 2 and Hermansky-Pudlak syndrome type 1 and 3 mutations in Puerto Rico. *J Invest Dermatol* 2006; 126: 85-90.
- Wei ML. Hermansky-Pudlak syndrome: a disease of protein trafficking and organelle function. *Pigment Cell Res* 2006; 19 (1): 19-42.
- Wang L, Lyerla T. Histochemical and cellular changes accompanying the appearance of lung Wbrosis in an experimental mouse model for Hermansky Pudlak syndrome. *Histochem Cell Biol* 2010; 134 (2): 205-10.
- Gochuico BR, Huizing M, Golas GA, et al. Interstitial Lung Disease and Pulmonary Fibrosis in Hermansky-Pudlak Syndrome Type 2, an Adaptor Protein-3 Complex Disease. *Molecular Medicine* 2012; 18 (1): 56-64.
- Gruson L, Berk T. A case of Hermansky Pudlak Syndrome with Pulmonary Sarcoidosis. *J Clin Aesthetic Dermatol* 2009; 2 (10): 41-4.
- Borie R, Danel C, Debray MP, et al. Pulmonary alveolar proteinosis. *Eur Respir Rev* 2011; 20 (120): 98-107.
- Trapnell BC, Puchalski J. Pulmonary Alveolar Proteinosis. In: Fishman AP, Elias JA, Fishman JA, Grippi MA, Senior RM, Pack AI, eds. *Fishman's Pulmonary Diseases and Disorders*. The McGraw Hill Companies Inc 2008; 1313-23.
- Avila NA, Brantly M, Premkumar A, Huizing M, Dwyer A, Gahl WA. Hermansky-Pudlak syndrome: radiography and CT of the chest compared with pulmonary function tests and genetic studies. *Am J Roentgenol* 2002; 179 (4): 887-92.
- Lederer DJ, Kawut SM, Sonett JR, et al. Successful bilateral lung transplantation for pulmonary fibrosis associated with the Hermansky-Pudlak syndrome. *J Heart Lung Transplant* 2005; 24 (10): 1697-9.
- O'Brien K, Troendle J, Gochuico BR, et al. Pirfenidone for the treatment of Hermansky-Pudlak syndrome pulmonary fibrosis. *Mol Genet Metab* 2011; 103 (2): 128-34.
- Gahl WA, Brantly M, Troendle J, et al. Effect of pirfenidone on the pulmonary fibrosis of Hermansky-Pudlak syndrome. *Mol Genet Metab* 2002; 76 (3): 234-42.
- Michaud G, Reddy C, Ernst A. Whole-lung lavage for pulmonary alveolar proteinosis. *Chest* 2009; 136 (6): 1678-81.
- Uchida K, Nakata K, Suzuki T, et al. Granulocyte/macrophage-colony-stimulating factor autoantibodies and myeloid cell immune functions in healthy subjects. *Blood* 2009; 113 (11): 2547-56.
- Nakatani Y, Nakamura N, Sano J, et al. Interstitial pneumonia in Hermansky-Pudlak syndrome: significance of florid foamy swelling/degeneration (giant lamellar body degeneration) of type-2 pneumocytes. *Virchows Arch* 2000; 437 (3): 304-13.