

A NOVEL MISSENSE MUTATION OF *DKC1* IN DYSKERATOSIS CONGENITA WITH PULMONARY FIBROSIS

S. Hisata¹, H. Sakaguchi², H. Kanegane³, T. Hidaka⁴, J. Shiihara¹, M. Ichinose¹, S. Kojima², T. Nukiwa⁵, M. Ebina¹

¹Department of Respiratory Medicine, Tohoku University Graduate School of Medicine, Sendai, Japan; ²Department of Pediatrics, Nagoya University Graduate School of Medicine, Nagoya, Japan; ³Department of Pediatrics, Graduate School of Medicine and Pharmaceutical Science, University of Toyama, Toyama, Japan; ⁴Department of Dermatology, Tohoku University Graduate School of Medicine, Sendai, Japan; ⁵South Miyagi Medical Center, Ohgawara, Japan

ABSTRACT. Dyskeratosis congenita (DC) is a rare inherited multisystem disorder caused by mutations in seven genes involved in telomere biology, with approximately 20% of cases having pulmonary complications. *DKC1* mutations exhibit a severe disease phenotype of DC that develops in early childhood. Here, we report a unique case of DC with pulmonary fibrosis diagnosed at the age of 46. A novel missense mutation (p.Arg65Lys) of *DKC1* was detected, and predicted to show a weak mutagenic effect. In spite of the steroid and immunosuppressive treatment, he died of an acute exacerbation seven months after the initial visit. This case suggests that mutation subtypes can cause heterogeneity in DC and pulmonary fibrosis. (*Sarcoidosis Vasc Diffuse Lung Dis* 2013; 30: 221-225)

KEY WORDS: Dyskeratosis congenita, *DKC1* mutations, pulmonary fibrosis

INTRODUCTION

Mutations in the genes encoding telomerase (*TERT* and *TERC*) cause pulmonary fibrosis in familial cases and in sporadic cases (1). This suggests that telomerase activity and telomere length maintenance are important in the pathogenesis of disease. Dyskeratosis congenita (DC), which is associated with defective telomere maintenance, is a rare inherited multisystem disorder characterized by a

classical triad of reticular skin pigmentation, nail dystrophy, and mucosal leukoplakia. Pulmonary complications, such as pulmonary fibrosis and abnormalities in the pulmonary microvasculature, occur in approximately 20% of patients (2). In childhood, bone marrow failure is the most frequent complication of DC, while pulmonary fibrosis is a frequent cause of mortality in adults (1). To date, seven genes involved in telomere biology (*DKC1*, *TERT*, *TERC*, *NOP10*, *NHP2*, *TINF2*, and *TCAB1*) have been found to cause DC. *DKC1* mutations are the most common in DC, occurring in 30% of all probands (3). Most often, patients with *DKC1* mutations exhibit a severe disease phenotype that presents in early childhood, in contrast to mutations of *TERT* and *TERC* (3, 4). Here, we report a novel missense mutation of *DKC1* in a 46-year-old man with pulmonary fibrosis.

Received: 3 September 2012

Accepted after Revision: 5 February 2013

Correspondence: Shu Hisata

Department of Respiratory Medicine,

Tohoku University Graduate School of Medicine

1-1 Seiryomachi, Aoba-ku, Sendai 980-8574, Japan

Tel. +81-22-717-8534

Fax +81-22-717-8549

E-mail: hisata@idac.tohoku.ac.jp

CASE PRESENTATION

A 46-year-old Japanese man was referred to our institute for worsening lung infiltrates, shortness of breath, and hypoxia. Three and a half years before, computed tomography of the chest in a complete physical examination showed diffuse ground-glass opacities. Six months before, he had shortness of breath and had been treated with prednisolone and home oxygen therapy in another hospital. He had smoked 20 cigarettes a day from the age of 20 to 45. He had right pneumothorax at the age of 25. He had no history of connective tissue disorder, or environmental or occupational exposure linked to pulmonary fibrosis. Since the age of 30 he had noticed skin changes that had emerged from his neck.

On physical examination, the blood pressure was 109/69 mm Hg, the pulse 98 beats per minute, and the body temperature 36.8 C°. Chest examination revealed weak bilateral inspiratory crackles. Skin examination revealed a widespread reticulated pigmentation around the neck and shoulders (Figure 1A). Dermatoscopy showed diffuse pigmentation with the exception of the near-normal skin color around the hair follicles (Figure 1B). Leukoplakia on the palate and mild dystrophy of the fingernails were noted (data not shown).

The chest X-ray showed significant loss of lung volume (Figure 2A). High-resolution computed tomography (HRCT) of the chest showed diffuse reticular and ground-glass changes in the upper and lower lung fields, which were compatible with fibrotic nonspecific interstitial pneumonia pattern

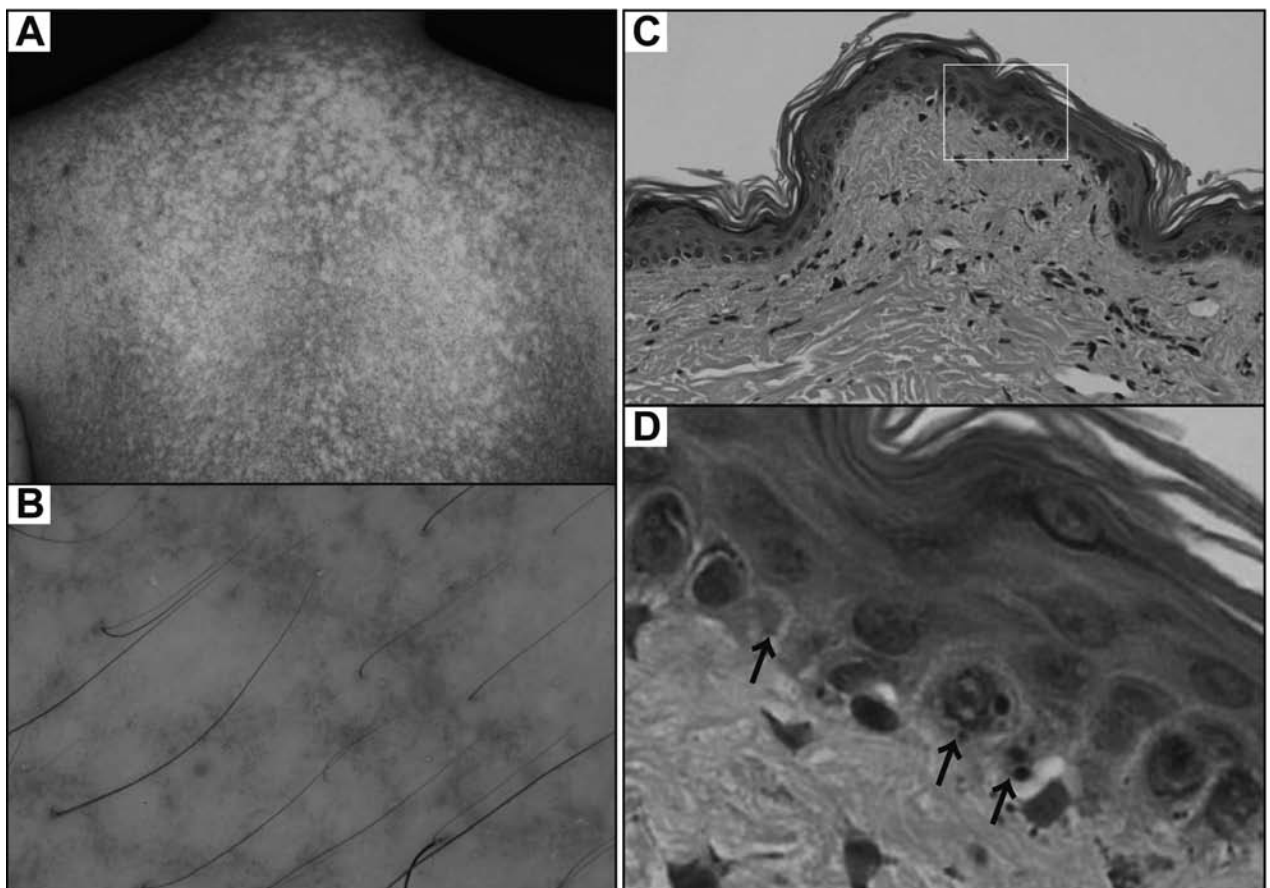


Fig. 1. (A) Widespread reticulated pigmentation around the neck and shoulders. (B) Dermatoscopy finding, showing diffuse pigmentation with the exception of the near-normal skin color around the hair follicles. (C) A Hematoxylin-Eosin stain section of a biopsy specimen from a forearm skin lesion, showing an atrophic epidermis ($\times 100$). (D) Partial enlargement of white box in Figure 1C, showing condensed or fragmented nuclei (black arrow) of basal cells at the epidermis, which indicated cell death ($\times 400$).

with traction bronchiectasis (Figure 2Ba, 2Bb). Pulmonary function testing showed a severe restrictive pattern (Forced vital capacity, 1.66 L; 44.3% predicted) with a considerably reduced diffusing capacity of the lung for carbon monoxide (24.4% predicted). The initial laboratory findings showed macrocytosis with a near-constant hemoglobin concentration (mean cell volume 110.1 fl, hemoglobin 13.3 g/dl). The serum levels of Krebs von den Lungen-6 and surfactant protein D were elevated to 4644 U/mL and 358 ng/mL, respectively. Total cell count of bronchoalveolar lavage was 4.3×10^5 per mL with a slightly raised percentage of neutrophils (5%), and the ratio of CD4 to CD8 was 0.34. A biopsy specimen from his forearm skin lesion showed an atrophic epidermis (Figure 1C). Some basal cells at the epidermis showed condensed or fragmented nuclei, indicating cell death (Figure 1D).

Clinically, the patient was diagnosed as DC and interstitial pneumonia complicated with DC. He was treated with low-dose prednisolone and cyclosporine. After one month from the initial visit, he had right pneumothorax, and underwent bullectomy of the right upper lobe. The surgical specimen of the lung revealed patchy collagen deposition, although the histopathological pattern could not be deter-

mined because of the limited size of the specimen. A few fibrotic foci and honeycomb-like cystic lesions were detected. There were only a few infiltrating inflammatory cells in the parenchyma of the lung (Figure 3). After the medication, his shortness of breath was slightly improved, but he died of an acute exacerbation seven months after the initial visit.

His telomere length and telomere related genes were analyzed. The telomere length of his white blood cells was shorter than that of healthy age-matched controls (-3.4SD). Genetic analysis of telomere-related genes (*DKC1*, *TERT*, *TERC*, *NOP10*, *TINF2*, *TCAB1*) revealed a missense mutation c.194G→A in exon4 of the *DKC1* gene. The gene mutation c.194G→A leads to the substitution of arginine by lysine at the 65th amino acid of dyskerin (p.Arg65Lys substitution). Although the p.Arg65Thr substitution has already reported, p.Arg65Lys of dyskerin was a novel mutation in DC (Figure 4A). The patient had a two-year-older brother, who had not smoked. Although his brother had similar skin changes around the neck and shoulder, he had neither respiratory symptoms nor abnormal shadow on chest X-ray in his annual health check. Unfortunately, genetic analysis of his family members has not been completed because of their refusal.

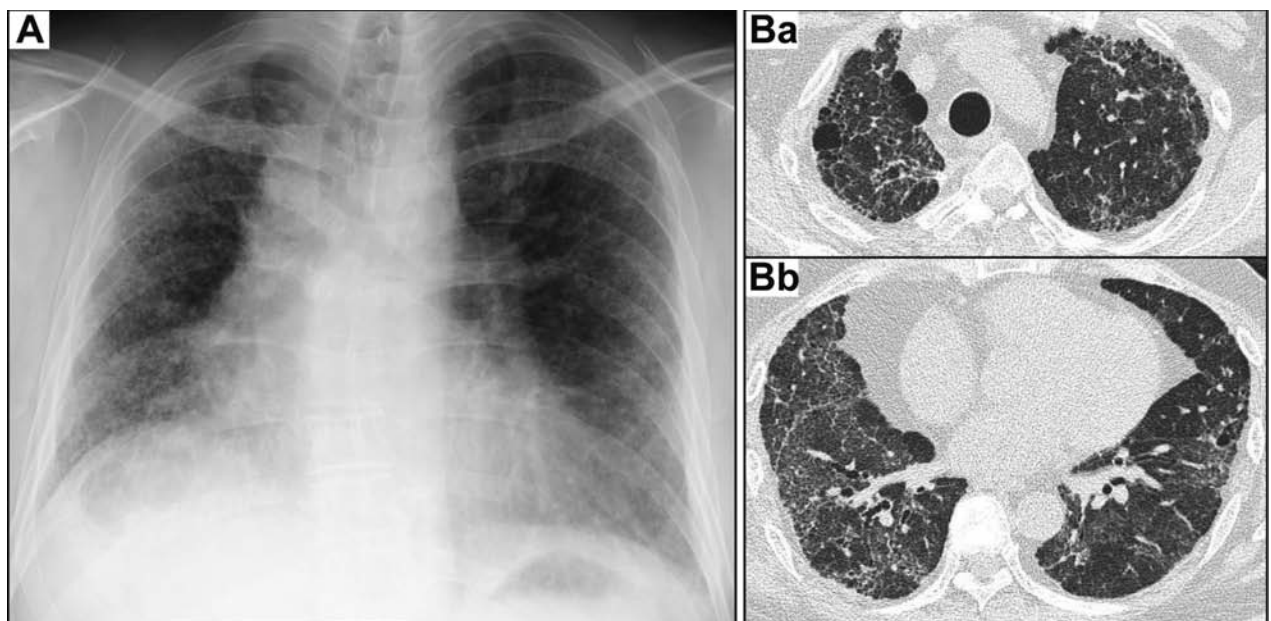


Fig. 2. (A) The chest X-ray, showing significant loss of lung volume. (B) High-resolution computed tomography of the chest, showing diffuse reticular and ground-glass changes in the upper (Ba) and lower (Bb) lung fields. Although basal subpleural honeycombing was not apparent, subpleural cysts in the upper lung fields were noted.

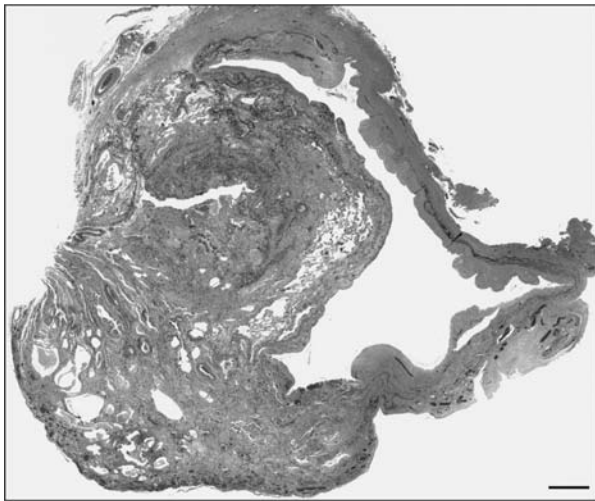


Fig. 3. An Elastica-Masson stain section of the bullectomy-specimen from his right upper lung, showing patchy dense collagen deposition (green staining) with architectural distortion. Honeycomb-like cysts were also detected at the bottom left. Scale bar: 1 mm

DISCUSSION

DC is a rare, inherited multisystem disorder characterized by defects in telomere maintenance.

Three modes of inheritance have been recognized: X-linked recessive, autosomal dominant, and autosomal recessive. The gene responsible for X-linked DC, which is associated with a severe phenotype, has been identified as *DKC1*. Dyskerin, encoded by *DKC1*, is a 58 kD nucleolar protein that has a close association with the RNA component of telomerase (TERC), and mutations in dyskerin cause a reduction in the accumulation of TERC and reduced telomere length(3) (Figure 4A, 4B).

We report here a novel missense mutation of the *DKC1* gene, leading to the substitution of arginine by lysine at the 65th amino acid of dyskerin (p.Arg65Lys substitution), although p.Arg65Thr has already been reported (5) (Figure 4A). Individuals who carry mutations in *DKC1*, which is associated with a more severe phenotype, usually require medical attention in the first two decades of life (3, 4). However, the patient presented here was diagnosed at the age of 46. The telomere length of his white blood cells was shorter than that of healthy age-matched controls (-3.4SD), but relatively well-preserved, considering the telomere length is often under -5SD in DC. It is estimated that the effect of the mutation is weaker in p.Arg65Lys than in p.Arg65Thr, because both arginine and lysine have very basic side chains,

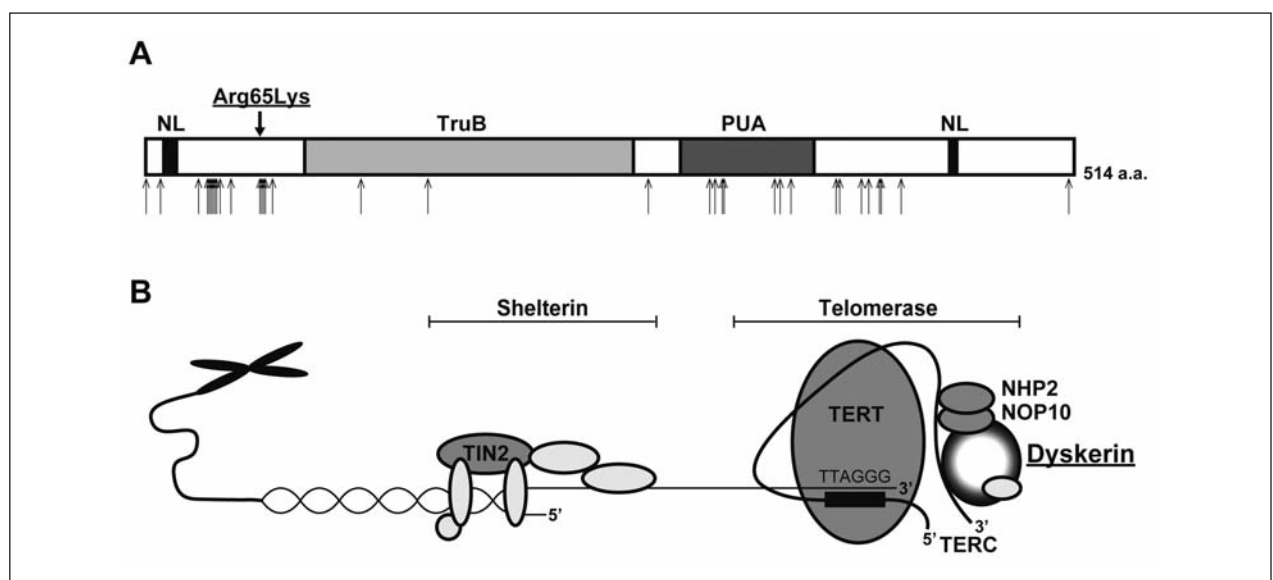


Fig. 1. (A) Structural organization of dyskerin with localization of disease-associated mutations. Upper and lower arrows indicate a novel mutation and known mutations, respectively. Dyskerin contains a TruB domain that participates in eukaryotic ribosomal RNA processing, two nuclear localization (NL) signals, and the Pseudouridine synthase and archaeosine transglycosylase (PUA) domain involved in RNA modification. (B) Schema of telomerase and shelterin complex

while threonine has an uncharged polar side chain. The clinical presentation may be mild because of the chemical similarity between arginine and lysine in the novel missense mutation. This may be why this patient developed DC at a later age than usual in DC with a *DKC1* mutation.

His two-year-old brother, who had not smoked, had neither respiratory symptoms nor abnormal shadows on chest X-ray in his annual health check, although detailed examination by HRCT had not been performed. His brother had similar skin changes around the neck and shoulder. In addition, the mode of inheritance of DC in *DKC1* mutations is X-linked recessive inheritance. Therefore, his brother was highly suspicious for DC, although genetic analysis has not been completed. Previous studies showed that cigarette smoking can accelerate disease onset, with those having a smoking history presenting as much as a decade earlier than those who never smoked (6). Smoking behavior might have precipitated the onset of pulmonary fibrosis in this patient.

In conclusion, we report a novel missense mutation of the *DKC1* gene leading to the substitution of

arginine by lysine at the 65th amino acid (p.Arg65Lys substitution) of dyskerin. This case suggests that mutation subtypes can cause heterogeneity in DC and pulmonary fibrosis.

ACKNOWLEDGEMENTS

The authors gratefully acknowledge Mr. Brent K. Bell for reading the manuscript.

REFERENCE

1. Armanios M. Telomerase and idiopathic pulmonary fibrosis. *Mutat Res* 2012; 730 (1-2): 52-8.
2. Walne AJ, Dokal I. Dyskeratosis Congenita: a historical perspective. *Mech Ageing Dev* 2008; 129 (1-2): 48-59.
3. Nelson ND, Bertuch AA. Dyskeratosis congenita as a disorder of telomere maintenance. *Mutat Res* 2012; 730 (1-2): 43-51.
4. Vulliamy TJ, Kirwan MJ, Beswick R, et al. Differences in disease severity but similar telomere lengths in genetic subgroups of patients with telomerase and shelterin mutations. *PLoS One* 2011; 6(9): e24383.
5. Dokal I, Vulliamy T. Dyskeratosis congenita: its link to telomerase and aplastic anaemia. *Blood Rev* 2003; 17 (4): 217-25.
6. Steele MP, Speer MC, Loyd JE, et al. Clinical and pathologic features of familial interstitial pneumonia. *Am J Respir Crit Care Med* 2005; 172 (9): 1146-52.