

## SULFASALAZINE INDUCED LUNG TOXICITY MASQUERADING AS SARCOIDOSIS - CASE REPORT AND REVIEW OF THE LITERATURE

G.R. Mohyuddin, F. Sultan, K. Zhang, G. Khaleeq

Geisinger Medical Center - Danville, PA

**ABSTRACT.** A commonly prescribed drug for rheumatoid arthritis (R.A) and inflammatory bowel disease (IBD) treatment, sulfasalazine can occasionally cause lung toxicity such as interstitial pneumonitis and eosinophilic pneumonias. We report a case of a 46 year old female being treated with sulfasalazine for ulcerative colitis, who developed shortness of breath and a radiographic pattern of hilar adenopathy. Biopsy showed granulomas that resembled Sarcoidosis. We review different presentations of sulfasalazine induced lung disease and describe the first known case of Sulfasalazine lung toxicity mimicking sarcoidosis. (*Sarcoidosis Vasc Diffuse Lung Dis* 2013; 30: 226-230)

**KEY WORDS:** Sarcoidosis, sulfasalazine, adenopathy

### Abbreviations

Inflammatory Bowel Disease: IBD

### INTRODUCTION

Sulfasalazine is a commonly prescribed drug used for rheumatoid arthritis and inflammatory bowel disease (IBD) treatment.

Common side-effects seen in up to one-fifth of patients are mostly nausea and vomiting, skin rashes, joint pain, hepatic dysfunction and fever (1). Al-

though very rare, sulfasalazine does on occasion cause pulmonary toxicity. Most often these reactions are interstitial pneumonitis and eosinophilic pneumonias (1). However, sulfasalazine has been known to cause a myriad of atypical lung pathologies, as our case and the subsequent discussion will serve to highlight.

### CASE

A 46 year old female presented to us with shortness of breath, dry cough and worsening hypoxemia. she had a history of hypertension, gastroesophageal reflux disease, depression, splenectomy following a motor vehicle accident, sarcoidosis and ulcerative colitis. Her ulcerative colitis was diagnosed in early 1991 and treated initially with sulfasalazine. In August 1992, she developed shortness of breath and was subsequently diagnosed with sarcoidosis after a bronchoscopy and transbronchial biopsy showed non necrotizing, non caseating granulomatous inflammation. Soon however, her ulcerative colitis went into remission and she discontinued use of Sulfasalazine,

Received: 28 November 2012

Accepted after Revision: 3 January 2013

Correspondence: Ghulam Khaleeq, M.D. (GK)

Associate, Departments of Pulmonary Disease, Critical Care and Sleep Medicine

100 N. Academy Ave. Danville, PA 17822

E-mail: gkhaleeq1@geisinger.edu

Consent:

Written informed consent was obtained from the patient for publication of this Case report and any accompanying images. A copy of the written consent is available for review by the Editor of this journal.

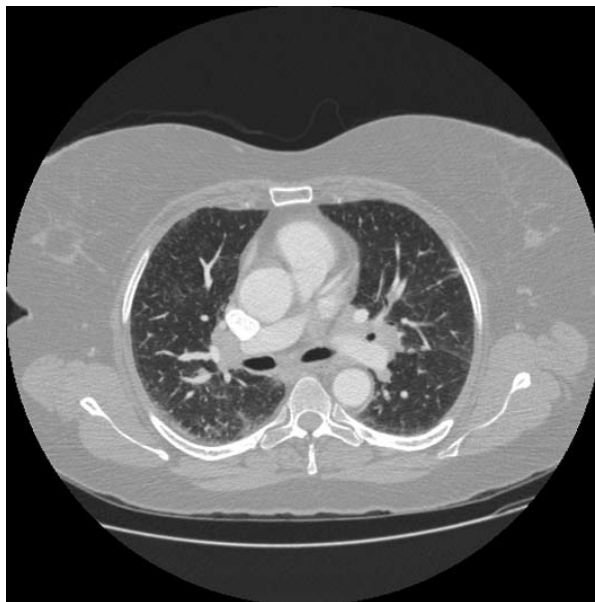with improvement of her respiratory symptoms. Her social history was significant for 5 pack years of smoking which she quit in 1995. She had worked initially in a valve factory for 17 years, and currently was working in a kitchen. She had never been exposed to tuberculosis, fungi, asbestosis, silicosis or any other occupational hazards. She had no pets and no significant travel history.

Both her sarcoidosis and ulcerative colitis had remained stable until recently, however a few months prior to her visit at our clinic, our patient had an exacerbation of ulcerative colitis. Her symptoms persisted despite mesalamine enemas and subsequently she was started on sulfasalazine, following which her gastrointestinal symptoms gradually began to show improvement.

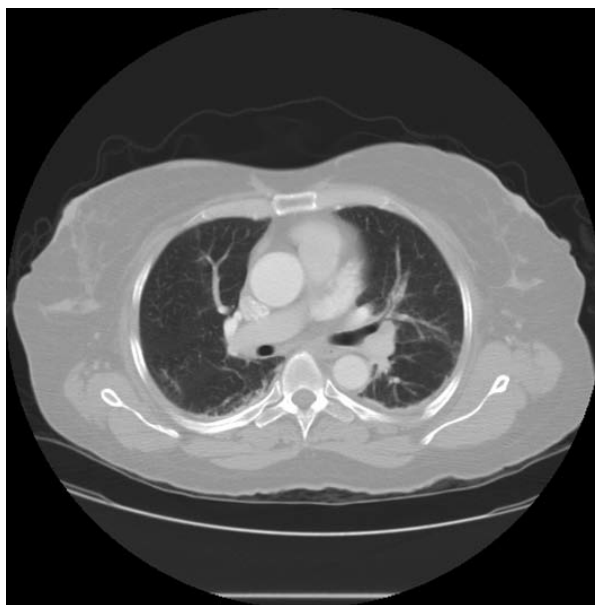
A few weeks after starting sulfasalazine, she presented to the emergency department with a week-long history of progressive shortness of breath and mild cough. Her review of symptoms was negative for fever, chest pain, leg edema, and orthopnea or leg pain. Her oxygen saturation had dropped to 88% at room air. A chest X-ray showed hilar fullness and computed tomography showed multiple mediastinal and hilar lymph nodes and patchy ground glass opacification towards the bases. She was diagnosed with an exacerbation of sarcoidosis, and Prednisone was started at 60mg a day.

Her symptoms continued to worsen. At her next visit, she had shortness of breath on walking 15 stairs, a dry cough with occasional sputum production, and an oxygen saturation of 90% on room air. Physical examination was negative for any edema or lymphadenopathy and the lungs were clear to auscultation. We performed pulmonary function tests and a bronchoscopy to confirm the diagnosis and severity of Sarcoidosis.

Endobronchial ultrasound bronchoscopy showed bilateral hilar, mediastinal and paratracheal adenopathy. EBUS FNA biopsy of the right and left hilar and subcarinal lymph nodes was hypocellular, prompting us to do a regular bronchoscopy. Trans-bronchial lung biopsies were performed from the left lower lobe that showed non-necrotizing, non-caseating, granulomatous inflammation. Cultures were negative, the lavage showed a mixed inflammatory infiltrate with absence of any features of malignancy. The differential count stood at 41% lymphocytes and 59% monocytes with no neutrophils or eosinophils.



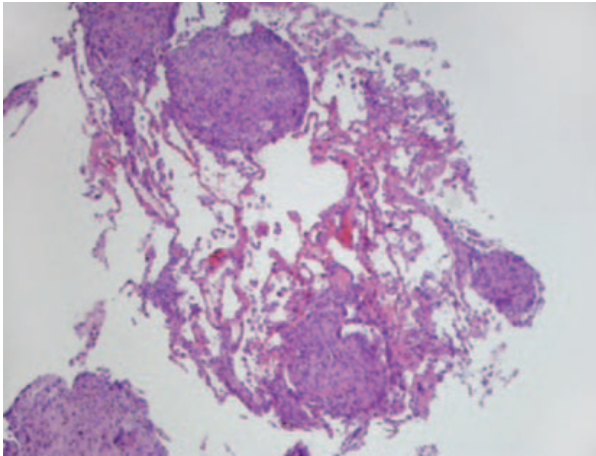
**Fig. 1.** CT chest lung windows showing subpleural nodules along with bilateral ground glass opacities.



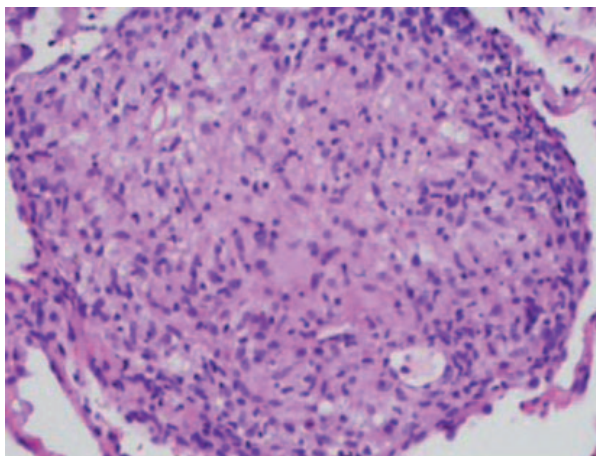
**Fig. 2.** CT chest after being off sulfasalazine for 4 months, shows clearing off the lungs and resolution of hilar/mediastinal adenopathy

PFT's showed a restrictive pattern with severely reduced diffusion capacity.

A month later, the patient presented again with worsening symptoms. Her saturations and PFT's continued to worsen. She was thus hospitalized. As



**Fig. 3.** Well-defined non-caseating granulomas can be seen (low power view x 100)



**Fig. 4.** Well-defined non-caseating granulomas can be seen (high power view x 400)

part of her work-up, an auto-immune panel was done which was normal. A second bronchoscopy was done, with a bronchioalveolar lavage taken from the right middle lobe which ruled out any opportunistic infection and showed an absence of eosinophilia. The differential count was lymphocytes 53%, monocytes 39% and neutrophils 8%.

We transferred our patient to the nearest lung transplant center, but she refused lung transplant. She was started on second line therapy with Methotrexate (15mg per week) and Steroids which were tapered to a lower dose (20 mg). A GI evaluation was done at the outside hospital, and she was put off Sulfasalazine because of improvement of her GI symptoms.

A follow up visit a month later was most surprising as our patients symptoms had improved and was now off oxygen. We gradually tapered off her steroids and methotrexate and with each subsequent visit her condition further improved. Subsequent PFT's continued to show an increasing diffusion capacity, and resolution of the prior restrictive pattern. Within a few months, our patient had resumed working full time and was off all medications, a remarkable turnaround for a prior lung transplant candidate.

## DISCUSSION

Sarcoidosis is a disorder of unknown etiology. A diagnosis of exclusion, it presents with granulomas in multiple systems. Most commonly affected are the lungs, with characteristic radiological findings of hilar lymphadenopathy, and interstitial changes with more severe involvement (2).

Sarcoidosis co-occurring with IBD is a recognized clinical phenomenon. In a thorough review, Hayashi et al discussed all reported cases of sarcoidosis co-existing with UC in the literature. He noticed an increased incidence of these diseases occurring concomitantly than would occur by chance alone and concluded that there may be a common factor in these two diseases, a possible genetic linkage (3).

The differential diagnosis of pulmonary disease in a patient with ulcerative colitis is extensive. Although extra intestinal manifestations of IBD can be seen in almost half of all IBD patients, pulmonary disease is less common. Pulmonary manifestations of IBD include bronchiectasis, pulmonary parenchymal disease such as interstitial pneumonitis and organizing lung disease, serositis, and pulmonary embolism (4).

Contrary to common belief, pulmonary disease in IBD patients is most frequently drug induced, often due to sulfasalazine, mesalamine, or methotrexate. Anti-tumor necrosis factor agents, azathioprine or calcineurin antagonists can also predispose to secondary infections. Any patient with IBD who presents with lung disorders should initially be evaluated for drug induced and opportunistic infections prior to the diagnosis of extra-intestinal manifestations of inflammatory bowel disease (5).

We were unaware of any of the drugs being administered to this patient having the potential to

cause a granulomatous lung reaction resembling Sarcoidosis; hence we did not consider a drug induced reaction as a possibility.

We believe our patient to have sulfasalazine induced lung toxicity based on the temporality of the symptoms with sulfasalazine administration. Her initial symptoms in 1992 occurred only when she was receiving treatment for ulcerative colitis with Sulfasalazine. Her symptoms resolved soon after her ulcerative colitis improved and sulfasalazine use was discontinued. Although she was diagnosed as Sarcoidosis again when the respiratory symptoms recurred, she did not show any improvement to standard therapy and continued to deteriorate, improving only upon discontinuation of sulfasalazine.

Sulfasalazine can cause a great variety of lung reactions. It is known to be a cause of acute pulmonary infiltrates, acute and chronic eosinophilic pneumonias, bronchiolitis obliterans, and fibrosing alveolitis(6). However, to the best of our knowledge, only a total of four cases of granulomatous lesions occurring with sulfasalazine toxicity have been reported in the literature (7-10).

Amongst these cases was a 68 year old lady with Sjögren's Syndrome who developed progressive cough and shortness of breath after administration of sulfasalazine. Bronchoscopy showed a high percentage of eosinophils, and biopsy showed epithelioid granulomas. Her symptoms resolved promptly upon discontinuation of sulfasalazine and administration of steroids(9).

Another report described a patient where Sulfasalazine pulmonary toxicity mimicked Wegener's granulomatosis, and again upon discontinuation, the symptoms disappeared (7).

Another patient who presented with granulomatous lesions in the lung with sulfasalazine therapy, also happened to suffer from pulmonary TB, thus the lesions here likely represented TB(8).

The fourth and final case report of a granulomatous lesion as a result of Sulfasalazine, was of a patient with sero-negative arthritis on whose transbronchial biopsy histiocytes and giant cell granulomas were seen (10).

The effects of methotrexate on the pulmonary system are also well recognized. Methotrexate typically causes pulmonary infiltrates which on histology resemble hypersensitivity disease. Most often these lesions do resolve within a few days of stopping methotrexate (11), however given that our patient began improve-

ment as soon as sulfasalazine was discontinued, and that the patient was improving while on methotrexate lends weight to sulfasalazine as the culprit.

Our patient was also given meselamine enemas. although meselamine pulmonary toxicity is also exceedingly rare, such that a study of 1700 patients failed to show any pulmonary toxicity (12), in case reports Meselamine has caused a range of different histological pulmonary manifestations, mostly interstitial lymphocytic infiltrates, alveolar fibrinous exudates, and poorly formed non-necrotizing granulomas (13). Meselamine again was unlikely as a cause here, given the temporality of the symptoms with Sulfasalazine.

The standard treatment of sulfasalazine induced pulmonary toxicity once recognized is prompt discontinuation of the drug. Symptoms are seen to resolve rapidly as in our patient. Perry et al, while comparing cases where steroids were given for treatment of this condition versus where they were not, concluded that there was no evidence for steroid use for treatment (1).

Generally, sulfasalazine induced pneumonitis has a good prognosis. Fatal case reports are very rare, and some of them can be attributed to underlying pulmonary conditions, or a failure to discontinue the drug (1).

## CONCLUSION

Our review serves to show that although rare, pulmonary toxicity can be highly variable in Sulfasalazine, and patients developing pulmonary complaints while on sulfasalazine should be promptly evaluated. The possibility of atypical presentations should always be entertained and recognized by the treating physician.

## Competing Interests

The authors declare that they have no competing interests.

## Authors Contribution

FS and GM were the resident and medical student respectively, who saw our patient. GK was the attending in charge of this patient. KZ provided his expert pathology opinion on our patient. GM and GK were involved in manuscript writing.



## REFERENCES

1. Parry SD, Barbatzas C, Peel ET, Barton JR. Sulphasalazine and lung toxicity. *Eur Respir J*. 2002 Apr;19(4):756-64.
2. Dempsey OJ, Paterson EW, Kerr KM, Denison AR. Sarcoidosis. *BMJ*. 2009;339:b3206.
3. Hayashi T, Nakamura T, Kurachi K, Asai Y, Nakajima A, Suzuki S, et al. Ulcerative colitis accompanied with sarcoidosis and dermatomyositis: report of a case. *Dis Colon Rectum*. 2008 Apr;51(4):474-6.
4. Sostegni R, Daperno M, Pera A. Pulmonary manifestations of inflammatory bowel disease. *Dig Liver Dis*. 2007 Mar;39(3):239-41.
5. Schleiermacher D, Hoffmann JC. Pulmonary abnormalities in inflammatory bowel disease. *J Crohns Colitis*. 2007 Dec;1(2):61-9.
6. Case records of the Massachusetts General Hospital. Weekly clinicopathological exercises. Case 12-1993. A 44-year-old man with pulmonary disease and proctitis. *N Engl J Med*. 1993 Mar 25;328(12):869-76.
7. Salerno SM, Ormseth EJ, Roth BJ, Meyer CA, Christensen ED, Dillard TA. Sulfasalazine pulmonary toxicity in ulcerative colitis mimicking clinical features of Wegener's granulomatosis. *Chest*. 1996 Aug;110(2):556-9.
8. Lorente JA P-RE, Badala G, Fogue L. Pulmonary disease induced by salazopyrine coexisting with pulmonary tuberculosis. *Med Clin*. 1989;93(476).
9. Bargon J, Rust M, Kardos P, Schneider M, Meier-Sydow J. [Salazosulfapyridine-induced eosinophilic pneumonia with pulmonary and cutaneous epithelioid cell granulomatosis in Sjogren syndrome]. *Pneumologie*. 1990 Apr;44(4):744-50.
10. Kolbe J, Caughey D, Rainer S. Sulphasalazine-induced sub-acute hyper-sensitivity pneumonitis. *Respir Med*. 1994 Feb;88(2):149-52.
11. Searles G, McKendry RJ. Methotrexate pneumonitis in rheumatoid arthritis: potential risk factors. Four case reports and a review of the literature. *J Rheumatol*. 1987 Dec;14(6):1164-71.
12. Brimblecombe R. Mesalazine: a global safety evaluation. *Scand J Gastroenterol Suppl*. 1990;172:66.
13. Foster RA, Zander DS, Mergo PJ, Valentine JF. Mesalamine-related lung disease: clinical, radiographic, and pathologic manifestations. *Inflamm Bowel Dis*. 2003 Sep;9(5):308-15.

