

SCADDING REVISITED: A PROPOSED STAGING SYSTEM FOR CARDIAC SARCOIDOSIS BASED ON ADVANCED IMAGING

Jeffrey S. Berman¹, Praveen Govender¹, Frederick L. Ruberg^{2,3}, Michael Mazzini², Edward J. Miller^{2,3}

¹Pulmonary Center and Sarcoidosis Center, Boston University School of Medicine; ²Section of Cardiovascular Medicine, Boston University School of Medicine; ³Department of Radiology, Boston University School of Medicine

Cardiac involvement in patients with sarcoidosis is an important problem. While autopsy findings suggest that up to 25% of patients with sarcoidosis (1) may have myocardial granulomas, only about 5% (2) of American patients with sarcoidosis manifest symptomatic cardiac disease. Cardiac involvement may result in heart block, wall motion abnormalities, cardiomyopathy, and malignant arrhythmias, all of which may adversely impact quality of life and survival (3). Since fatal arrhythmia/sudden death or cardiomyopathy may be the first manifestation of myocardial involvement (4, 5) there is interest in early identification and more precise diagnosis of cardiac sarcoidosis (CS).

Advanced imaging modalities, including cardiac positron emission tomography (PET) and cardiac magnetic resonance (CMR), have emerged as critically important tests by which cardiac sarcoidosis can be identified and prognosis determined. Both modalities can image inflammation and fibrosis – the two key distinctive features of CS. PET can identify active sarcoid inflammation by means of 18-fluorodeoxyglucose (FDG) uptake and fibrosis by means of Rubidium-82 (Rb-82) or Nitrogen-13 (N-13) myocardial perfusion imaging defects. CMR can identify inflammation by means of T2-weighted imaging and fibrosis by means of late gadolinium enhancement (LGE). Data compar-

ing the diagnostic accuracy of PET vs. CMR in CS are not well developed, while data supportive of the clinical utility of each modality in isolation has been widely reported. There is no consensus upon which test is superior, with modality choice usually dependent upon institutional availability and local expertise. Data suggest that PET imaging with FDG may be more sensitive than CMR imaging for detection of myocardial inflammation in sarcoidosis, in part due to the limited reproducibility and challenge of interpretation of T2 weighted CMR imaging (6, 7). As an example, one report presented a patient in whom an initial CMR was negative while PET showed evidence of inflammation by FDG, whereas a year later MRI showed delayed enhancement in the area previously shown to have FDG uptake on PET (8). Conversely, CMR with late gadolinium enhancement (LGE) imaging may be more specific for the identification of the myocardial fibrosis that can develop following granulomatous inflammation and LGE appears to predict adverse clinical outcomes including death or arrhythmic events, whereas absence of CMR-LGE appears predictive of low risk (9, 10).

Despite abundant data for both modalities, there is little published guidance as to which test (CMR or PET) to use in which clinical setting and no consensus of how to report PET findings. The purpose of this document is to propose a structure for the classification of cardiac sarcoidosis using PET imaging, so as to establish a standardization of reporting for both clinical and research applications and allow for future comparison to CMR (Table 1, Figure 1). This is important in order to frame more robust comparative studies between CMR

Correspondence: Dr. Jeffrey Berman
The Pulmonary Center
72 East Concord Street - R-304
Boston, MA, 02118
Phone: (617) 638-4860
Fax (617) 536-8093
Email: jsberman@bu.edu

and PET to better define appropriate utilization, particularly because PET, unlike CMR, can be used to follow disease progression and response to therapy in patients who have undergone implantation of a pacemaker or implantable conversion defibrillator (ICD). In addition to FDG imaging, concomitant myocardial perfusion imaging (Rb-82 or N-13) (11, 12) with PET can provide complementary and additive information about the sarcoid disease process in the heart (13). For example, FDG uptake suggests the presence of inflammation, while a perfusion abnormality, in the absence of coronary stenosis in the matched vascular territory, suggests myocardial fibrosis from granulomatous inflammation. This area should correspond to fibrosis identified by CMR-LGE. Reports have supported this

Table 1. Proposed PET staging system of Cardiac Sarcoidosis (CS).

Staging of CS is based on PET imaging and clinical manifestations of disease. Abnormal FDG uptake on PET scanning will be either present (+ FDG) or absent (- FDG) and myocardial perfusion imaging (assessed with Rb-82 or N-13) will be either Normal or Abnormal. Stage 0 reflects a normal PET (no abnormal FDG uptake, normal perfusion). Imaging of CS showing only abnormal FDG uptake and no perfusion abnormality is designated Stage I. When both abnormal FDG uptake and perfusion abnormalities are seen in the same or contiguous areas, Stage II cardiac sarcoidosis is present. Stage III indicates both abnormal FDG uptake and perfusion abnormalities, but the areas of abnormality are not necessarily contiguous. Stage IV indicates perfusion abnormality without FDG uptake. Subscripts would be added to the stage describing the clinical manifestations of CS; an “a” would represent asymptomatic, or “silent” CS; “b” would indicate a history of symptomatic bradycardia or conduction system disease (i.e. LBBB, RBBB or any level of heart block); “c” would denote cardiac dysfunction by presence of heart failure symptoms (NYHA class II-IV) or a left ventricular ejection fraction of less than 35%; and “d” would indicate the presence of ventricular dysrhythmias (unexplained syncope, aborted sudden death, or documented sustained ventricular tachycardia or ventricular fibrillation either spontaneously or during electrophysiologic study).

	(-) FDG	(+) FDG
Normal Perfusion	Stage 0 (normal)	Stage I
Abnormal Perfusion	Stage IV	Stage II (same myocardial segments) Stage III (different segments)
Clinical Manifestations	a – Asymptomatic b – symptomatic Bradycardia or heart Block c – Cardiac dysfunction d - ventricular Dysrhythmias	

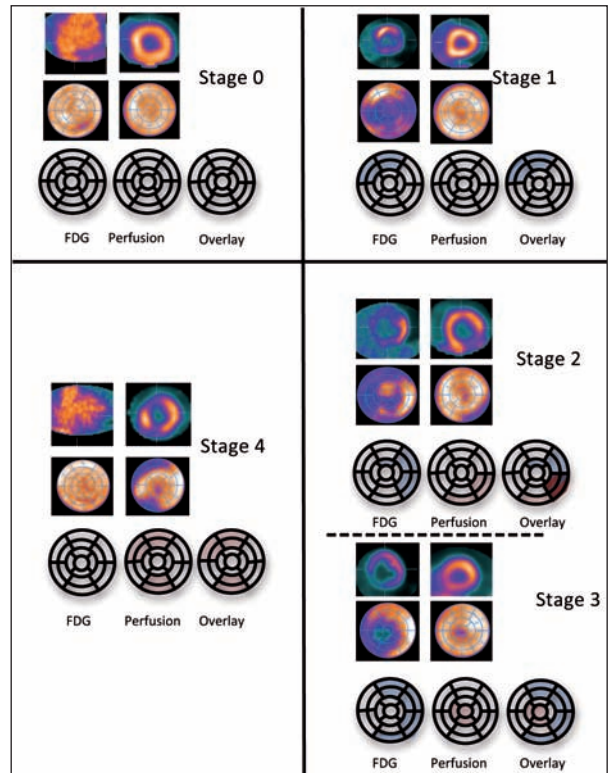


Fig. 1. Examples of PET Imaging Patterns for Classification of Cardiac Sarcoidosis. (Top Left) Stage 0: Normal (absent) FDG uptake and normal perfusion. (Top Right) Stage 1: Increased FDG uptake and normal perfusion. (Middle Right) Stage 2: Increased FDG uptake and perfusion defects in some or all overlapping segments. (Bottom Right) Stage 3: Increased FDG uptake and perfusion defects with no overlapping segments. (Bottom Left) Stage 4: Normal (absent) FDG uptake and perfusion defects. Representative short axis images (top) bulls eye images (middle) and 17 segment model (bottom) for each example. Blue infill represents segments with abnormal FDG uptake, red infill represents segments with abnormal perfusion and red/blue combined stripe represents segments with both abnormal FDG and perfusion abnormalities.

assertion by observing that treatment with immunomodulatory medications may reduce or eliminate FDG uptake/ inflammation, but that perfusion defects are fixed (14-17). Thus decisions to treat with immunomodulatory agents would be impacted by the presence of FDG uptake, and in the absence of FDG myocardial uptake such treatment would generally be withheld.

PET findings, either increased FDG uptake or Rb-82/N-13 perfusion defects, are often in areas that correlate to the electrical and/or mechanical function disturbances such as wall motion abnormalities. Prognostic studies in cardiac sarcoidosis of either increased

FDG uptake and/or perfusion defects by PET have been recently reported and provide evidence that the addition of myocardial perfusion imaging to FDG PET is helpful to define prognosis(13), and some data suggest increased FDG uptake may be associated with increased risk of VT (18, 19). CMR data using LGE show that the irregular scars of sarcoidosis appear to be particularly arrhythmogenic irrespective of ejection fraction (9). Use of the FDG PET cardiac sarcoidosis staging system proposed here will allow easier comparisons among these imaging modalities.

Staging of sarcoidosis based on imaging disease patterns is not a new concept. In 1961, Scadding proposed a now well known "staging" system for pulmonary sarcoidosis based solely on the appearance of the chest x-ray (20). The x-ray "stages" range from stage 0 (normal chest X ray) to stage IV (fibrosis) with the implication that progression occurs between stages. Data suggest that radiologic stage correlates with overall prognosis for pulmonary disease. We propose a similar classification system for cardiac sarcoidosis based on PET imaging and clinical manifestations, both of which may reflect the degree and activity of granulomatous myocardial involvement and scar.

We feel that this system will be helpful to clinicians in that it reflects the key issues in regard to treatment of inflammation and cardiac function and to researchers as it might serve as a framework for investigation and standardized reporting of imaging findings.

Our proposed classification of PET imaging in CS is based on imaging and clinical manifestations of disease, and is analogous to the familiar Scadding staging of pulmonary sarcoidosis ranging from Stage 0 to Stage IV (see Table 1), realizing that the term 'Stage' refers to the imaging disease pattern and not prognosis. Stage 0 reflects a normal PET (no abnormal FDG uptake, normal perfusion) in a patient with suspected CS. Imaging of CS showing only abnormal FDG uptake and no perfusion abnormality is designated Stage I. When both abnormal FDG uptake and perfusion abnormalities are seen in the same or contiguous areas, Stage II cardiac sarcoidosis is present. Stage III indicates both abnormal FDG uptake and perfusion abnormalities, but the areas of abnormality are not necessarily contiguous. Stage IV indicates perfusion abnormality without FDG uptake, reflecting, presumably, scar. In the future, should T2 imaging with CMR for CS become routine, an analogous staging using CMR would simply substitute T2-weighted imaging for FDG (to

identify edema related to inflammation) and LGE for perfusion defects (to identify fibrosis). Thus, stage 0 CMR would be no T2 abnormalities and no LGE, whereas stage IV would be LGE without T2 abnormality.

To add information relevant to patient management, subscripts could be added to the stage describing the clinical manifestations of CS; an "a" would represent asymptomatic, or "silent" CS; "b" would indicate a history of symptomatic bradycardia or conduction system disease (i.e. LBBB, RBBB or any level of heart block); "c" would denote cardiac dysfunction by presence of heart failure symptoms (NYHA class II-IV) or a left ventricular ejection fraction of less than 35%; and "d" would indicate the presence of ventricular dysrhythmias (unexplained syncope, aborted sudden death, or documented sustained ventricular tachycardia or ventricular fibrillation either spontaneously or during electrophysiology study). Describing patterns of cardiac involvement on the basis of information from FDG uptake and perfusion has been described recently by Skali et al. (21), but organizing this information as an imaging tool analogous to that currently used for staging lung involvement is novel.

Thus as an example, a patient with sarcoidosis is referred for cardiac PET, which shows FDG uptake and perfusion abnormality in the septum. The ejection fraction is normal. The patient subsequently suffers a syncope episode, and is found to have inducible ventricular tachycardia during EP study; the staging for this patient would be Stage II_d. Immunomodulatory therapy in addition to ICD would be prescribed. If, in a future follow-up PET, the FDG uptake regressed but the perfusion defect remained, the patient would be restaged Stage IV_d.

This vignette illustrates the desirability of using PET to stage CS both because FDG uptake influences the decision to treat with immunomodulatory agents, and because PET can be used to follow such patients even after the insertion of pacemaker or ICD.

Caution should be applied to any interpretation of cardiac PET imaging to avoid false positive studies. Specific recommendations include ensuring appropriate dietary preparation (22) in order to null physiologic myocardial glucose uptake in FDG studies, and awareness of other causes of focal myocardial glucose uptake or perfusion abnormalities, such as myocardial ischemia or infarction from obstructive coronary artery disease. Also, a movement towards a quantitative rather than

qualitative analysis of PET data, including utilization of a standard uptake value (SUV)-driven interpretive system, should decrease inter-observer subjectivity. Caution should also be applied to the term “staging” as it may result in patient anxiety related to the implications of higher stages, even when the actual prognostic implications of such staging are not completely elucidated. Further research will be required to more precisely define the implications of each stage. Despite these caveats, we hope that this system will serve as useful shorthand for the follow-up and management of CS patients, and might serve as a research tool to examine the influence of various forms of CS on treatment, morbidity and mortality.

REFERENCES

- Silverman KJ, Hutchins GM, Bulkley BH. Cardiac sarcoid: a clinicopathologic study of 84 unselected patients with systemic sarcoidosis. *Circulation*. 1978;58(6):1204-11. PubMed PMID: 709777.
- Sharma OP, Maheshwari A, Thaker K. Myocardial sarcoidosis. *Chest*. 1993;103(1):253-8. PubMed PMID: 8417889.
- Kandolin R, Lehtonen J, Kupari M. Cardiac sarcoidosis and giant cell myocarditis as causes of atrioventricular block in young and middle-aged adults. *Circulation Arrhythmia and Electrophysiology*. 2011;4(3):303-9. PubMed PMID: 21427276.
- Roberts WC, McAllister HA, Jr, Ferrans VJ. Sarcoidosis of the heart. A clinicopathologic study of 35 necropsy patients (group 1) and review of 78 previously described necropsy patients (group 11). *The American Journal of Medicine*. 1977;63(1):86-108. PubMed PMID: 327806.
- Perry A, Vuitch F. Causes of death in patients with sarcoidosis. A morphologic study of 38 autopsies with clinicopathologic correlations. *Archives of pathology & Laboratory Medicine*. 1995;119(2):167-72. PubMed PMID: 7848065.
- Ohira H, Tsujino I, Ishimaru S, Oyama N, Takei T, Tsukamoto E, et al. Myocardial imaging with 18F-fluoro-2-deoxyglucose positron emission tomography and magnetic resonance imaging in sarcoidosis. *European journal of Nuclear Medicine and Molecular Imaging*. 2008;35(5):933-41. PubMed PMID: 18084757.
- Mehta D, Lubitz SA, Frankel Z, Wisnivesky JP, Einstein AJ, Goldman M, et al. Cardiac involvement in patients with sarcoidosis: diagnostic and prognostic value of outpatient testing. *Chest*. 2008;133(6):1426-35. PubMed PMID: 18339784.
- Ohira H, Tsujino I, Sato T, Yoshinaga K, Manabe O, Oyama N, et al. Early detection of cardiac sarcoid lesions with (18)F-fluoro-2-deoxyglucose positron emission tomography. *Internal Medicine*. 2011;50(11):1207-9. PubMed PMID: 21628936.
- Greulich S, Deluigi CC, Gloekler S, Wahl A, Zurn C, Kramer U, et al. CMR Imaging Predicts Death and Other Adverse Events in Suspected Cardiac Sarcoidosis. *JACC Cardiovascular Imaging*. 2013. PubMed PMID: 23498675.
- Patel MR, Cawley PJ, Heitner JF, Klem I, Parker MA, Jaroudi WA, et al. Detection of myocardial damage in patients with sarcoidosis. *Circulation*. 2009;120(20):1969-77. PubMed PMID: 19884472; PubMed Central PMCID: PMC2778859.
- Yamagishi H, Shirai N, Takagi M, Yoshiyama M, Akioka K, Takeuchi K, et al. Identification of cardiac sarcoidosis with (13)N-NH(3)/(18)F-FDG PET. *Journal of Nuclear Medicine*. 2003;44(7):1030-6. PubMed PMID: 12843216.
- Okumura W, Iwasaki T, Toyama T, Iso T, Arai M, Oriuchi N, et al. Usefulness of fasting 18F-FDG PET in identification of cardiac sarcoidosis. *Journal of Nuclear Medicine*. 2004;45(12):1989-98. PubMed PMID: 15585472.
- Blankstein R, Osborne M, Naya M, Waller A, Kim CK, Murthy VL, et al. Cardiac Positron Emission Tomography Enhances Prognostic Assessments of Patients with Suspected Cardiac Sarcoidosis. *J Am Coll Cardiol*. 2013. PubMed PMID: 24140661.
- Tadamura E, Yamamuro M, Kubo S, Kanao S, Hosokawa R, Kimura T, et al. Images in cardiovascular medicine. Multimodality imaging of cardiac sarcoidosis before and after steroid therapy. *Circulation*. 2006;113(20):e771-3. PubMed PMID: 16717157.
- Takeda N, Yokoyama I, Hiroi Y, Sakata M, Harada T, Nakamura F, et al. Positron emission tomography predicted recovery of complete A-V nodal dysfunction in a patient with cardiac sarcoidosis. *Circulation*. 2002;105(9):1144-5. PubMed PMID: 11877369.
- Pandya C, Brunken RC, Tchou P, Schoenhagen P, Culver DA. Detecting cardiac involvement in sarcoidosis: a call for prospective studies of newer imaging techniques. *The European Respiratory Journal*. 2007;29(2):418-22. PubMed PMID: 17264327.
- Mc Ardle BA, Leung E, Ohira H, Cocker MS, Dekemp RA, Dasilva J, et al. The role of F(18)-fluorodeoxyglucose positron emission tomography in guiding diagnosis and management in patients with known or suspected cardiac sarcoidosis. *Journal of Nuclear Cardiology*. 2013;20(2):297-306. PubMed PMID: 23288545.
- Betensky BP, Tschabrunn CM, Zado ES, Goldberg LR, Marchlinski FE, Garcia FC, et al. Long-term follow-up of patients with cardiac sarcoidosis and implantable cardioverter-defibrillators. *Heart rhythm: the official journal of the Heart Rhythm Society*. 2012; 9(6): 884-91. PubMed PMID: 22338670.
- Mc Ardle BA, Birmie DH, Klein R, de Kemp RA, Leung E, Renaud J, et al. Is there an association between clinical presentation and the location and extent of myocardial involvement of cardiac sarcoidosis as assessed by (1)(8)F- fluorodeoxyglucose positron emission tomography? *Circulation Cardiovascular Imaging*. 2013;6(5):617-26. PubMed PMID: 23884290.
- Scadding JG. Prognosis of intrathoracic sarcoidosis in England. A review of 136 cases after five years' observation. *British Medical Journal*. 1961;2(5261):1165-72.
- Skali H, Schulman AR, Dorbala S. (18)F-FDG PET/CT for the Assessment of Myocardial Sarcoidosis. *Current Cardiology Reports*. 2013;15(5):352. PubMed PMID: 23504346.
- Langah R, Spicer K, Gebregziabher M, Gordon L. Effectiveness of prolonged fasting 18f-FDG PET-CT in the detection of cardiac sarcoidosis. *Journal of Nuclear Cardiology: official publication of the American Society of Nuclear Cardiology*. 2009;16(5):801-10. PubMed PMID: 19548047.