

RAPID IMPROVEMENT OF OSSEOUS SARCOIDOSIS AFTER THE TREATMENT OF PULMONARY ASPERGILLOSIS BY ITRACONAZOLE

K. Murakami¹, T. Tamada¹, K. Abe¹, M. Nara², S. Hisata¹, Y. Mitsuishi¹, S. Muramatsu¹, K. Gomi¹, M. Ebina¹, T. Nukiwa¹

¹Department of Respiratory Medicine, Tohoku University Graduate School of Medicine; ²Department of Comprehensive Medicine, Tohoku University Graduate School of Medicine

ABSTRACT. Osseous sarcoidosis is relatively uncommon, and treatment with corticosteroids is not always effective. Moreover, patients with an advanced stage of pulmonary sarcoidosis are sometimes infected with aspergillus in the cavities of the pulmonary lesions, and long-term use of corticosteroids should be prohibited to prevent the development of fatal invasive pulmonary aspergillosis. Here, we described a unique case of osseous sarcoidosis with pulmonary aspergillosis, showing a rapid improvement of the osseous symptoms just after the administration of the antifungal agent, itraconazole. Itraconazole is likely to become a candidate among new therapeutic agents for osseous sarcoidosis. (*Sarcoidosis Vasc Diffuse Lung Dis* 2011; 28: 75-78)

KEY WORDS: bone sarcoidosis, itraconazole, aspergillosis, corticosteroids

INTRODUCTION

Sarcoidosis is a multisystem granulomatous disorder of unknown etiology. Especially, osseous involvement of sarcoidosis is relatively uncommon with a frequency ranging from 1 to 13% (1, 2). The recommended medications for osseous sarcoidosis are still controversial, because it seems to respond poorly to corticosteroids (3), and only a few reports mention the effectiveness of colchicine or nonsteroidal anti-inflammatory drugs for only symptomatic relief (2).

Here, we described a unique case of osseous sarcoidosis showing a rapid improvement of the osseous symptoms just after the administration of an antifungal agent, itraconazole, without corticosteroids. Itraconazole is likely to become a candidate among new therapeutic agents for osseous sarcoidosis.

CASE REPORT

A 62-year-old woman with a thirteen-year history of pulmonary and skin sarcoidosis had been treated with oral minocycline (100 mg/day) because of facial erythema nodosum for 2 years, and showed only slight signs of improvement. Additionally, she experienced progressive finger pain and persistent cough. She was admitted to our hospital for the detailed examinations and treatment.

On admission, her fingers were considerably swollen and showed mild deformation (Figure 1A).

Received: 1 September 2010

Accepted after Revision: 22 November 2010

Correspondence: Tsutomu Tamada, M.D., Ph.D.

Department of Respiratory Medicine,

Tohoku University Graduate School of Medicine

1-1 Seiryō-machi, Aoba-ku, Sendai 980-8574, Japan

Tel. +81-22-717-8539

Fax +81-22-717-8549

E-mail: tamada@m.tains.tohoku.ac.jp

Skin lesions involved facial erythema nodosum and subcutaneous nodules in bilateral extremities. Serum angiotensin-converting enzyme (ACE) and soluble interleukin-2 receptor (sIL-2R) were elevated up to 31.5 U/L (normal, 7-25) and 1066 U/mL (normal, 127-582), respectively. Serum aspergillus antigen was up to 1.4 (normal, <0.5). The bone

scintigraphy revealed multiple uptakes at bilateral phalanges. The hand radiograph showed multiple cystic and lytic lesions, which are typical in osseous sarcoidosis (Figure 1B). Chest computed tomography (CT) revealed linear fibrosis in both upper lobes and a large cavity with a fungus ball in her right upper lobe (Figure 1C). Based on these findings, she

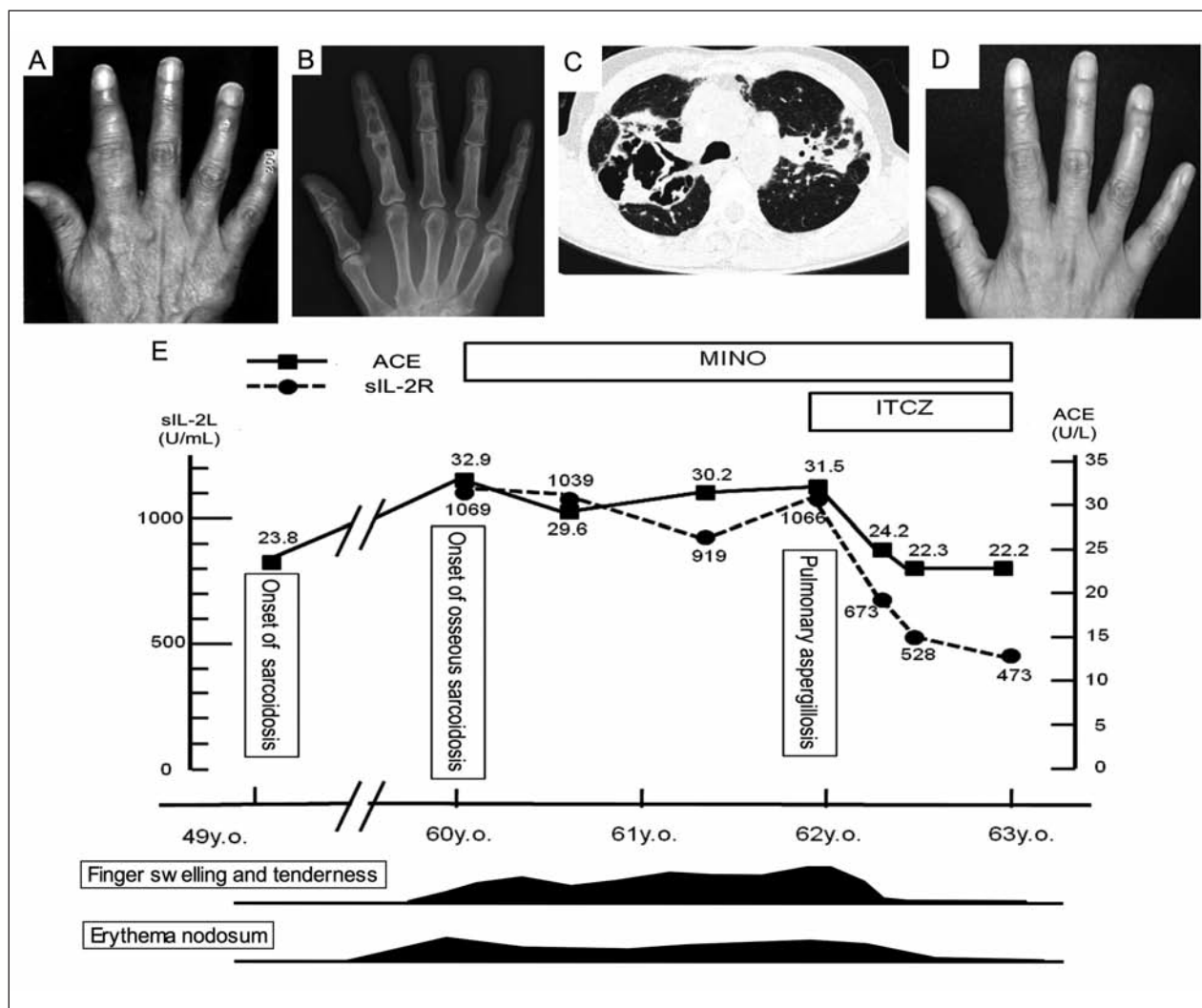


Fig. 1. (A) A photograph of her right hand on admission. Her fingers are considerably swollen and there is mild deformation at the proximal interphalangeal joint of the forefinger. (B) Right hand radiograph before treatment shows multiple lytic lesions at the metacarpal bone, proximal phalanx and middle phalanx of her all fingers, especially prominent in the forefinger. These observations are typical for osseous sarcoidosis. (C) Chest CT at the diagnosis of pulmonary aspergillosis combined with pulmonary sarcoidosis. Linear bilateral fibrosis and consolidations are observed in both upper lobes. A fungus ball-like structure is also observed in a cavity of the right upper lobe. (D) A photograph of her right hand one month after itraconazole treatment. The swelling was reduced and the range of motion of her forefinger had improved completely. (E) A drawing delineating the clinical course of this case. As serum levels of both ACE and sIL-2R decreased after itraconazole administration, the painful swelling of her fingers and erythema nodosum of her face improved. MINO: minocycline; ITCZ: itraconazole; ACE: angiotensin-converting enzyme; sIL-2R: soluble interleukin-2 receptor.

was diagnosed as pulmonary aspergillosis in combination with osseous, pulmonary and skin sarcoidosis. Concerning treatments for osseous sarcoidosis, we could not choose corticosteroids, because she might have developed a fatal invasive pulmonary aspergillosis under long-term use of corticosteroids. We thought that if the presence of combined infection worsened the activity of osseous sarcoidosis, then the control of infection would slightly improve the osseous symptoms. In addition to minocycline, we started oral itraconazole (400 mg/day) without corticosteroids as a treatment for the pulmonary aspergillosis. Surprisingly, both pain and swelling of her fingers were considerably relieved and the range of motion of her fingers fully improved after just one month, along with a rapid decrease in serum aspergillus antigen (0.6), ACE (24.2 U/L) and sIL-2R (673 U/mL) (Figure 1D, 1E). Her facial erythema nodosum and her persistent cough also showed a gradual improvement after administering itraconazole. On radiograph of her fingers, multiple cystic lesions gradually reduced with marked improvements in both density and thickness of the bone cortex (Figure 2). Although obvious pulmonary improvement could not be detected in chest CT, she continued to be asymptomatic without showing any adverse effects at the two-year follow-up.

DISCUSSION

Osseous sarcoidosis is thought to be difficult to treat, because corticosteroids are not always effective for osseous lesions (2). Furthermore, long-term use of corticosteroids induces osteoporosis, exacerbations of combined infections and many other adverse events.

Concerning the present case, her good clinical course indicated that itraconazole improved not only the pulmonary aspergillosis but also osseous and skin involvements without corticosteroids. As far as we know, there is only one report describing the usefulness of itraconazole in combination with corticosteroids for pulmonary sarcoidosis without fungal infection (4). However, our case is different from this report in four points: i) corticosteroid was not applied to our case, ii) our case was infected with aspergillus, iii) our case showed a remarkable im-

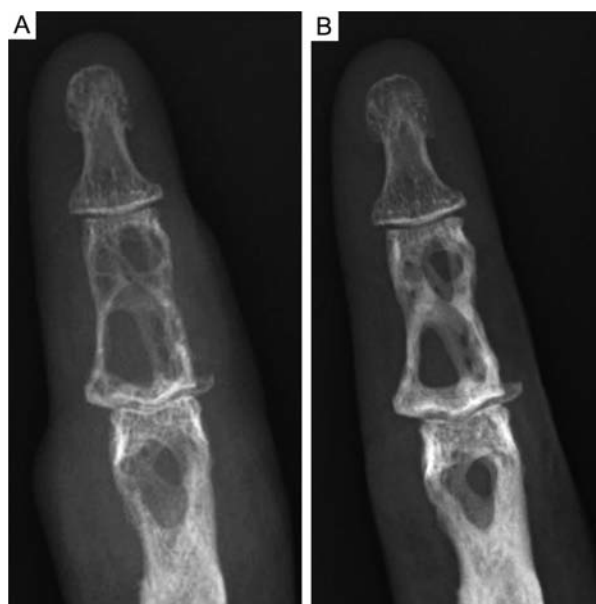

Fig. 2. Radiographs of right hand forefinger before (A) and one year after (B) the administration of ITCZ. Multiple cystic lesions gradually reduced with marked improvements in both density and thickness of the bone cortex. A remarkable swelling of soft tissue also improved.

provement in the osseous involvement as well as fungal infection and iv) the serum levels of ACE and sIL-2R, commonly used biomarkers of sarcoidosis, decreased to within normal limits in parallel with the improvement of her symptoms. Therefore, we believe that this is the first case report describing the usefulness of itraconazole for osseous sarcoidosis.

It is well known that pulmonary sarcoidosis often remits spontaneously within several years after the diagnosis. However, spontaneous remission of osseous sarcoidosis has not been reported yet. In the present case, the osseous involvements had been progressive for two years after onset, but her osseous symptoms improved rapidly in parallel with decreases in the serum levels of ACE or sIL-2R one month after the administration of itraconazole. This drastic change in clinical course considerably supports the relationship between itraconazole and the remission of osseous involvements. Even if this is true, it is still controversial whether itraconazole itself directly improved osseous sarcoidosis or whether the control of pulmonary aspergillosis by itraconazole improved it. Further clinical trials are needed to clarify this issue.

In conclusion, we reported the first case suggesting that itraconazole could be useful for the treatment of osseous sarcoidosis.

ACKNOWLEDGEMENTS

The authors gratefully acknowledge Mr. Brent K. Bell for reading the manuscript.

REFERENCES

1. James DG, Neville E, Carstairs LS. Bone and joint sarcoidosis. *Semin Arthritis Rheum* 1976; 6: 53-81.
2. Wilcox A, Bharadwaj P, Sharma OP. Bone sarcoidosis. *Curr Opin Rheumatol* 2000; 12: 321-30.
3. Johns CJ, Michele TM. The clinical management of sarcoidosis. A 50-year experience at the Johns Hopkins Hospital. *Medicine (Baltimore)* 1999; 78: 65-111.
4. Terceļj M, Rott T, Rylander R. Antifungal treatment in sarcoidosis - a pilot intervention trial. *Respir Med* 2007; 101: 774-8.