

EQUINE SARCOIDOSIS

E.P.R. Reijerkerk¹, E.J.B. Veldhuis Kroeze², M.M. Sloet van Oldruitenborgh-Oosterbaan¹

¹Department of Equine Sciences, Faculty of Veterinary Medicine, Utrecht University, the Netherlands, ²Department of Pathobiology, Faculty of Veterinary Medicine, Utrecht University, the Netherlands

Equine sarcoidosis, also known as “equine idiopathic systemic granulomatous disease” (16), “generalised or granulomatous disease” (13), “systemic granulomatous disease” (19), “equine histiocytic disease” (13) and “equine histiocytic dermatitis” (3) is a rare disease of unknown aetiology and pathogenesis (15). Equine sarcoidosis is usually characterised by exfoliative dermatitis, less commonly by moderate to severe wasting and sarcoïdal granulomatous inflammation of multiple organ systems (10, 15, 18). Sarcoidosis has been reported in humans, cattle and horses (2, 6, 14, 16).

Stannard classified equine generalised sarcoidosis in two forms (19): the cutaneous form and the nodular form. The most common cutaneous form starts with skin lesions showing generalised scaling and crusting combined with variable alopecia of face and limbs, often sparing the mane and tail (10, 15). Localisation of the dermatologic lesions described in horses for generalised cutaneous sarcoidosis found in literature are the face, girth area, back, ventral abdomen, axillary and inguinal region, neck, shoulder, extremities, prepuce and scrotum (18). Previous reports mention pruritus as a clinical sign in patients with sarcoidosis (7, 18) whereas other reports do not mention this (1, 5, 8, 12, 16). The second form, with

nodules or tumour-like masses, is rare in horses and is often combined with extensive scaling and crusting as well. Commonly affected organs in horses with the nodular form are the skin, lungs, lymph nodes and gastrointestinal tract (1, 5, 13, 15, 18) as seen in humans as well (6). Less commonly reported affected organs or tissue(s) include liver, spleen, kidney, the skeletal system, heart, adrenal- and thyroid glands, pancreas and the nervous system (15, 18). Recently a “localised cutaneous form”, has been described (15, 17). In these patients the typical hyperkeratotic, crusted and alopecic areas stayed localised (for many years) and occurred most often on the lower limbs, and incidentally elsewhere, in otherwise systemically healthy and well performing horses (17). In horses most cases start with dermatologic problems (5, 8, 15, 16, 18). Horses with localised cutaneous sarcoidosis have no clinical systemic signs other than the affected (un)pigmented lower limb, which can become crusty, thick and painful sometimes resulting in lameness (17). Non cutaneous clinical signs of sarcoidosis in horses indicating systemic involvement include weight loss, anorexia, respiratory distress, peripheral lymphadenopathy, fever and exercise intolerance (1, 5, 12, 16) which are similar to those in humans with sarcoidosis (2, 6). Additional clinical signs depend on the organ system that is involved.

So far no underlying cause or mechanism has been found in sarcoidosis (18). Sarcoidosis is suggested to be the result of an exaggerated immunologic response, due to exogenous infectious agents or allergens as the antigenic stimulus (9, 18). No (causative) agent has been identified yet in the equine species (15, 18).

Received: 16 March 2009

Accepted after Revision: 13 May 2009

Correspondence: Dr. E.P.R. Reijerkerk

Department of Equine Sciences

Faculty of Veterinary Medicine

Utrecht University

Utrecht, the Netherlands

E-mail: E.P.R. Reijerkerk@uu.nl

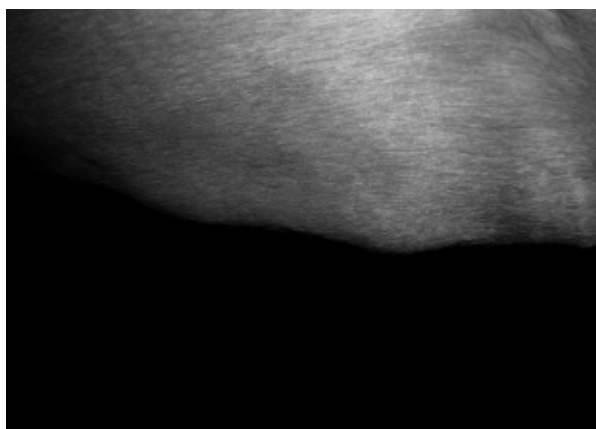
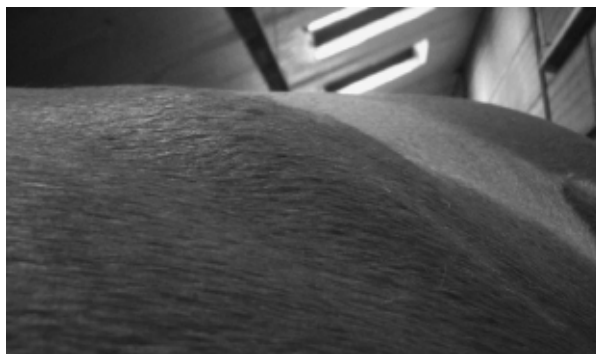
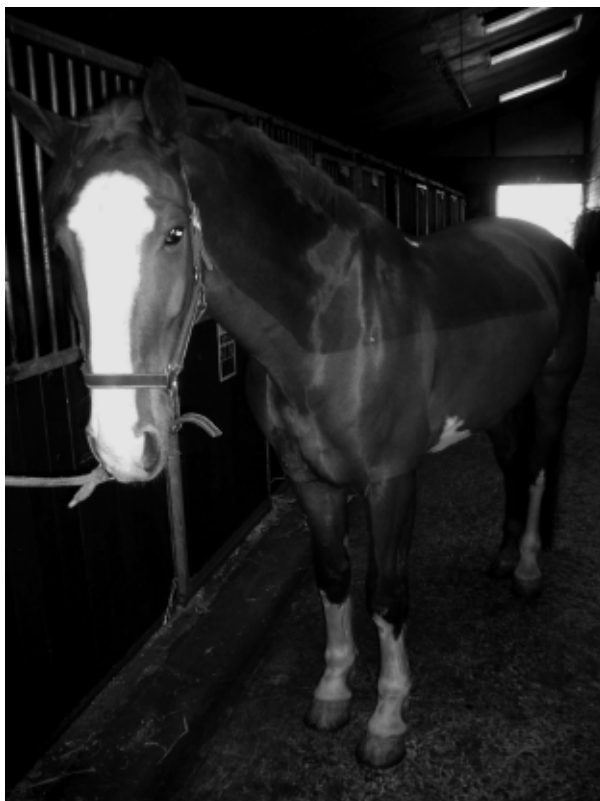
Fig. 1 (a). Seven-year old Dutch Warmblood gelding with several firm non painful nodules varying in diameter between 5 and 15 cm between the forelimbs, on the neck, in the lumbar region and on the abdomen

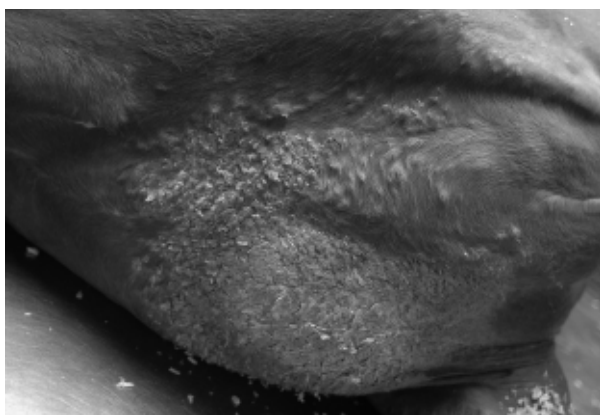


Fig. 1 (b). Macroscopic view of the affected skin in the pectoral region at post-mortem examination. Note the large greyish ('asbestos-like') hyperkeratotic and scaling patch of skin with multiple surrounding small prominent subcutaneous nodules.

Diagnosis of equine sarcoidosis is often based on history, clinical appearance and histopathology of a skin biopsy combined with excluding all other granulomatous diseases of known cause (6, 17). In

horses thoracic radiographs may be helpful in incidental cases with respiratory signs.

Clinical management in generalised or localised sarcoidosis is often problematic (13). Several cases, especially the localised form, are reported to show a good response to a prolonged course of systemic corticosteroids (e.g. dexamethasone or prednisolone) (17, 18). A few horses showed spontaneous remission as well for no apparent reason (10, 14, 18). Although some equine cases may stay unaltered without any treatment, treatment of both generalised and localised sarcoidosis is limited to prolonged (months to years) doses of systemic corticosteroids (15, 17, 18).

The prognosis can not be easily predicted (6), because of the unknown cause and highly variable nature of its natural course (6). The prognosis for generalised sarcoidosis with only lung involvement seem to be better than for horses with multi-organ or gastro-intestinal involvement (18). Also the study from Spiegel et al. (18) indicated a more favourable

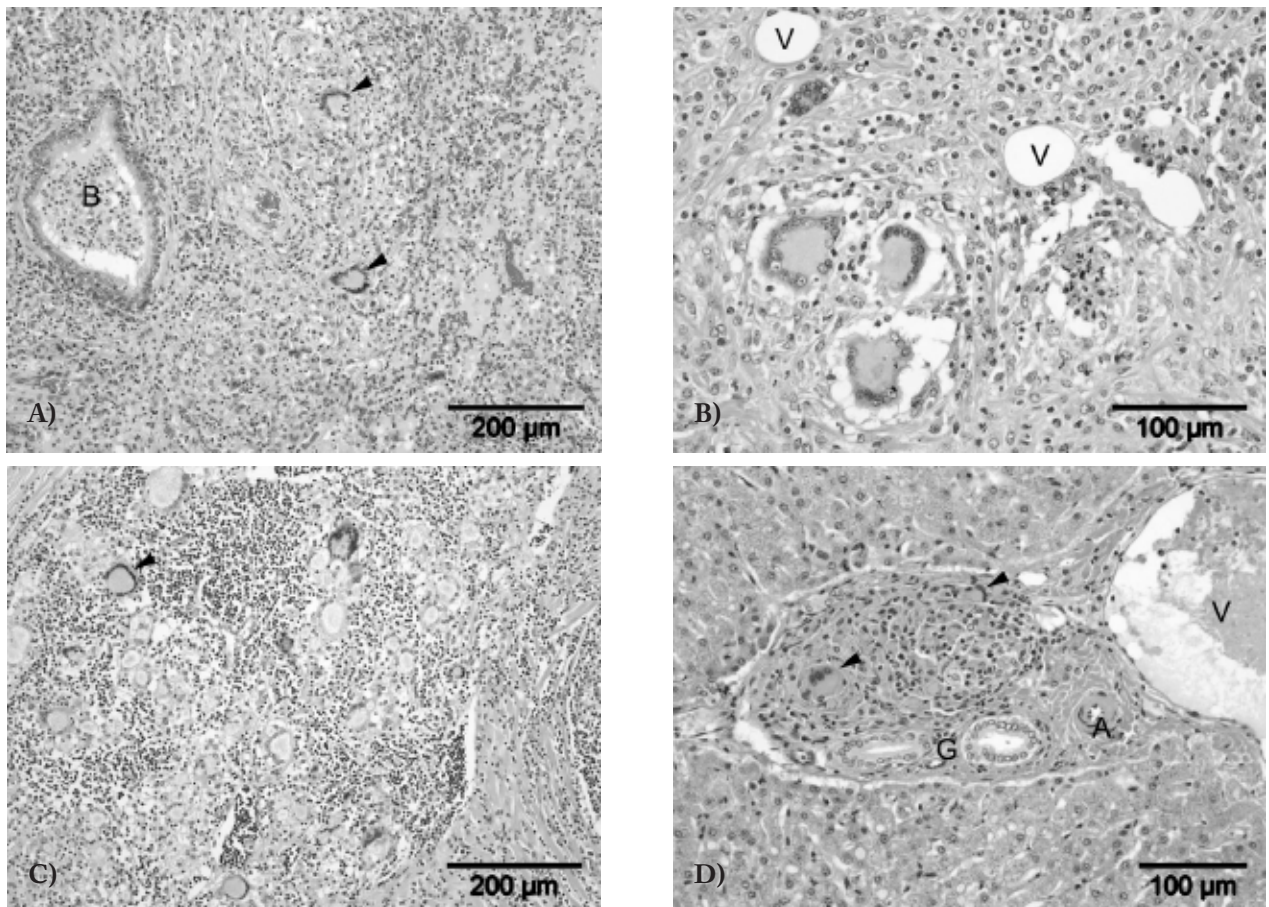


Fig. 2 (a,b,c and d). Micrographs of several affected organs displaying typical histological lesions such as lymphohistiocytic infiltrates admixed with more or less numbers of Langhans-type multinucleated giant cells (arrowheads). **(a):** Consolidated fibrotic and infiltrated areas of pulmonary tissue. B = bronchiole with neutrophilic exudate. **(b):** Granulomatous panniculitis in the pectoral subcutis, note the cluster of three giant cells (bottom left). V = adipocytes. **(c):** Affected sternal lymphnode containing, amongst numerous multinucleated giant cells, an archetypal Langhans type giant cell with abundant finely granular eosinophilic cytoplasm and margined nuclei in a horse-shoe-shape configuration. **(d):** Granulomatous hepatic lesions represented by few multinucleated giant cell within a portal area. V = portal vein, A = hepatic artery, G = bile ducts. (Hematoxylin & Eosin stain).

prognosis, especially when fewer organs were involved. In general, the prognosis for localised sarcoidosis is regarding the life of the horse, but poor for the affected skin (17).

Recently two cases of equine generalised sarcoidosis in an 11-year old Trakehner mare and a 7-year old Dutch Warmblood gelding have been described (11).

The first horse showed an onset of severe extensive dermatologic problems with only slight pulmonary involvement, whereas the second horse showed localised crusty, multifocal skin nodules and involvement of several organs. The first horse was diagnosed with generalised cutaneous sarcoidosis on

the basis of histological examination of a skin biopsy and the second with generalised systemic sarcoidosis at post-mortem examination. Both horses showed distinctive histological alteration of the skin with extensive lymphohistiocytic infiltrations and Langhans-type multinucleated giant cells. In these two cases no infectious agent was found, but prior to the onset of the clinical problems in both horses an event of surgery or a vaccination was mentioned. In literature no description of these events as risk factors was found. It is still thought that equine sarcoidosis has an underlying immunological cause. In these cases hypothesised immune influencing events are for example chronic stress, surgery and vaccina-

tion. For both cases the prognosis was unfavourable because of the limited effect of corticosteroid therapy and progressive deterioration of the disease.

Unfortunately for these reasons both horses were euthanased.

As described in horses commonly affected organs such as skin, lungs, lymph nodes and gastrointestinal tract (1, 5, 13, 15, 18) are seen in human sarcoidosis as well (6). In human medicine, sarcoidosis is also an idiopathic granulomatous disease which usually affects the lung, whereas dermatological problems occur later or not at all in the course of the disease (6). The clinical signs of sarcoidosis, weight loss, anorexia, respiratory distress, peripheral lymphadenopathy, fever and exercise intolerance (1, 5, 12, 16) are similar to those in humans with sarcoidosis (2, 6). In humans pulmonary sarcoidosis is the most common form and the thoracic radiography is abnormal in more than 90% of prognostic cases (6) although predictions for individual patients based on chest radiograph alone are unreliable (6).

Treatment for sarcoidosis is not always indicated since the disease may spontaneously remit and the prolonged use of corticosteroids has severe side-effects (6). In both human and horses the prognosis can not be easily predicted (6), because of its unknown cause and highly variable natural course (6).

REFERENCES

1. Axon JE, Robinson P, Lucas J. Generalised granulomatous disease in a horse. *Aust Vet J* 2004; 82: 48-51.
2. English JC, Patel PJ, Greer KE. Sarcoidosis. *J Am Acad Dermatol* 2001; 44: 725-43.
3. Fadok VA. An overview of equine dermatoses characterized by scaling and crusting. *Vet Clin N Am-Equine* 1995; 11: 43-51.
5. Heath SE, Bell RJ, Clark EG, et al. Idiopathic granulomatous disease involving the skin in a horse. *J Am Vet Med Assoc* 1990; 197: 1033-6.
6. Judson MA. Sarcoidosis: clinical presentation, diagnosis and approach to treatment. *Am J Med Sci* 2008; 335: 26-33.
7. Kobluk CN, Ames TR, Geor RJ. Generalized granulomatous disease. In: Kobluk CN, Ames TR, Geor RJ eds. *The Horse: Diseases and Clinical Management*. Philadelphia: W.B. Saunders, 1995: 558-9.
8. Loewenstein C, Bettenay SV, Mueller RS. A retrospective study of equine sarcoidosis. *Vet Derm* 2004; 15: 67
9. Newman LS, Rose CS, Maier LA. Sarcoidosis. *N Engl J Med* 1997; 336: 1224-34.
10. Pascoe RRR, Knottenbelt DC. Sarcoidosis. Immune mediated/allergic diseases. In: *Manual of Equine Dermatology*. London: Harcourt Brace, 1999: 169-170.
11. Reijerkerk EPR, Veldhuis Kroeze EJB, Sloet van Oldruitenborgh-Oosterbaan MM. Generalized sarcoidosis in two horses. *Tijdschr Diergeneesk* 2008; 133: 654-61.
12. Rose JF, Littlewood JD, Smith K et al. A series of four cases of generalized granulomatous disease in the horse. In: *proceedings of 3rd World Congress of Veterinary Dermatology* 1998; 562-3.
13. Schlipf JW. Dermatological conditions associated with crusts and scales: Sarcoidosis. In: Robinson NE ed. *Current therapy in Equine Medicine*, 4th edn. Philadelphia: W.B. Saunders, 1997: 384.
14. Scott DW. *Large Animal Dermatology*. Philadelphia: W.B. Saunders, 1983: 326-8.
15. Scott DW, Miller WH. Sarcoidosis. In: *Equine dermatology*. Saunders, St. Louis, 2nd edition, 2003: 675-80.
16. Sellers RS, Toribio RE, Blomme EAG. Idiopathic systemic granulomatous disease and macrophage expression of PTHrP in a miniature pony. *J Comp Pathol* 2001; 125: 214-8.
17. Sloet van Oldruitenborgh-Oosterbaan MS, Koeman JP. Recognition and therapy of sarcoidosis. In: *Proceedings of the 45th BEVA Congress*. Birmingham, 2006: 184-5.
18. Spiegel IB, White SD, Foley JE, et al. A retrospective study of cutaneous equine sarcoidosis and its potential infectious aetiological agents. *Vet Dermatol* 2006; 17: 51-62.
19. Stannard AA. Generalized granulomatous disease. In: Robinson NE ed. *Current Therapy in Equine Medicine*, 2nd edn. Philadelphia: W.B. Saunders, 1987: 645-6.