

A CASE OF SYSTEMIC POLYARTERITIS NODOSA INVOLVING BRONCHIAL ARTERY

Y.J. Lee¹, S.S. Park¹, S.Y. Kim¹, J.Y. Lee¹, H.-K. Koo¹, H.I. Yoon²

¹Division of Respiratory and Critical Care Medicine, Department of Internal Medicine and Lung Institute, Seoul National University Hospital, Seoul, Republic of Korea; ²Division of Respiratory and Critical Care Medicine, Department of Internal Medicine, Seoul National University Bundang Hospital, Seongnam-si, Gyeonggi-do, Republic of Korea

ABSTRACT. Polyarteritis nodosa (PAN) is a systemic necrotizing vasculitis involving predominantly medium-sized muscular arteries. It commonly involves skin, kidney, cardiovascular system, gastrointestinal system, and neurological system. But bronchial artery involvement of PAN is rarely identified. We report a case of PAN with initial presentation of hemoptysis. On admission, chest radiograph and chest CT angiography revealed no focus of bleeding. Angiography showed a bronchial artery aneurysm and multiple arterial aneurysms in both renal, hepatic, mesenteric and branches of small bowel arteries. These findings were compatible with the diagnosis of PAN. The patient was started on steroid and cyclophosphamide. (*Sarcoidosis Vasc Diffuse Lung Dis* 2010; 27: 164-168)

KEY WORDS: polyarteritis nodosa, bronchial artery, hemoptysis

INTRODUCTION

Polyarteritis nodosa (PAN) is a systemic necrotizing vasculitis involving predominantly medium-sized muscular arteries. It commonly involves skin, kidney, cardiovascular system, gastrointestinal system, and neurological system. But bronchial artery and pulmonary artery involvement of PAN is rarely identified. Since there has been no premortem case with well documented bronchial arteritis in PAN, we report a case of PAN involving the bronchial artery that initially presented as hemoptysis.

CASE REPORT

A 29-year-old nonsmoking man was admitted to our hospital on August 8, 2008 because of a 10-month history of recurrent hemoptysis. Before being admitted to our hospital, the patient was admitted to a local hospital due to bleeding and had chest radiographs, a chest CT, and bronchoscopy done. But there was no specific focus of the bleeding. The amount and frequency of hemoptysis increased over time and he gradually lost weight over several months. Also, he complained about numbness and pain in both hands.

He had a long history of asthma since age 5. He had taken systemic corticosteroids and methotrexate for asthma control, but the bronchospasms were severe and poorly controlled.

The patient was acutely ill and appeared to be in moderate respiratory distress. He had a rounded moon face. Diffuse wheezing was audible but no rale or heart murmur was auscultated. Blood pressure was 160/100 mmHg; temperature was 36.4; pulse

Received: 28 June 2010

Accepted after Revision: 5 July 2010

Correspondence: Ho Il Yoon, MD, PhD

Department of Internal Medicine

Division of Pulmonary and Critical Care Medicine

Seoul National University Bundang Hospital

300 Gumi-dong, Bundang-gu, Seongnam,

Gyeonggi-do, 463-707, Korea

Tel. +82-31-787-7036

Fax: +82-31-787-4052

E-mail: dextro@snu.ac.kr

was 82 beats/min, and the respiration rate was 22/min. Laboratory tests revealed white blood cells $10.8 \times 10^9/l$ (neutrophils 56.1%, lymphocytes 32.3%, monocytes 6.0%, and eosinophils 5.2%), hemoglobin 13.8 g/dL and C-reactive protein 0.3 mg/dL. Arterial blood gas analysis was pH 7.295, $p\text{CO}_2$ 53.8 mmHg, $p\text{O}_2$ 50.4 mmHg, bicarbonate 25.6 mmol/L, and 80.4% O_2 saturation in room air. Levels of serum immunoglobulin G, A, M, C_3 and C_4 were all within normal limits, but immunoglobulin E was highly elevated. The antinuclear antibodies, rheumatoid factor, ANCA, serological testing for hepatitis B and C were all negative.

The patient complained of numbness in the right forearm and hand. A consulting neurologist could find no evidence of central or peripheral nervous system disease. We recommended electromyographic and nerve conduction velocity studies, but the patient refused to take the exam.

No abnormality was found in the chest x-ray film, and we could not find the focus of bleeding in chest CT angiography. So selective bronchial arteriography was done and it revealed a vascular aneurysm in the terminal branch of the right bronchial artery. Embolization was done for RUL aneurysm (figure 1) and the bleeding stopped.

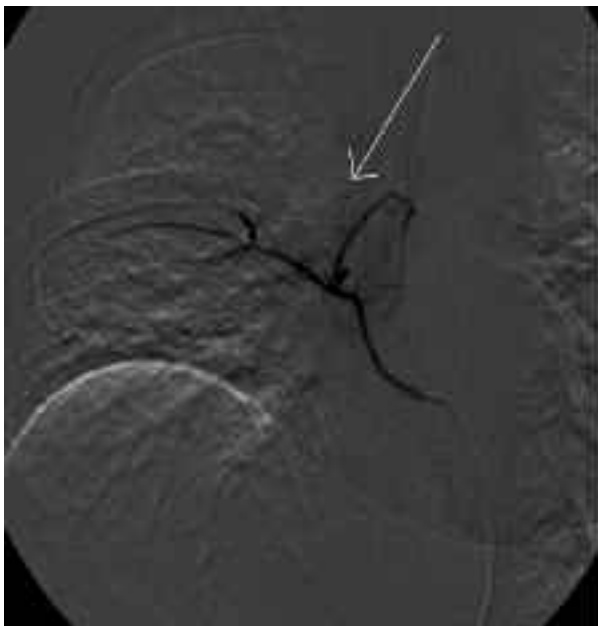


Fig. 1. Aneurysm in terminal branch of right bronchial artery

Ten days after the embolization, hemoptysis started again in the ward. So thoracic aortography and abdominal angiography were done. Selected celiac arteriography and aortography revealed a wide distribution of aneurysms throughout the both kidneys, small bowel, and liver (figure 2).

He was diagnosed with polyarteritis nodosa by typical angiographic findings. Because he already had some steroid side effects, we thought that high-dose steroid therapy was not suitable for him. So, monthly intravenous cyclophosphamide was started for PAN and scheduled to continue for 6 months.

DISCUSSION

PAN is a systemic necrotizing vasculitis that typically involves medium sized muscular arteries commonly associated with the kidneys, skin, joints, muscles, nerves, and gastrointestinal tract (1). Arteritis occurs in bronchial arteries and involvement of pulmonary arteries is rare (2). Prevalence for PAN was estimated from 2-33 cases per million but regional variations also appeared (3-5). The variation in estimates may be partly explained by differences in diagnostic criteria, but regional differences also appear to exist (6-8). The diagnosis is most commonly made in middle aged or older adults, and the incidence rises with age with a peak in the sixth decade of life (3, 6, 8).

Although most cases of PAN are idiopathic, a few studies have reported about the pathogenetic roles of HBV, HCV and hairy cell leukemia on the development of PAN (9-12). In one report from France, about 30% of the cases with HBV infection also had cases of PAN, but it is possible that many more HBV infections may coexist with PAN in endemic areas of HBV (9).

ACR criteria are widely used in the diagnosis of PAN. The condition is classified as PAN if at least three of the following 10 criteria(13) are present: wt loss over 4 kgs, livedo reticularis, testicular pain or tenderness, myalgia, weakness or leg tenderness, mono- or polyneuropathy, diastolic BP >90 mmHg, elevated BUN or creatinine, presence of hepatitis B surface antigen or antibody in serum, arteriographic abnormality and small or medium-sized arteries containing polymorphonuclear cells as shown by biopsy. These criteria have a reported sensitivity of

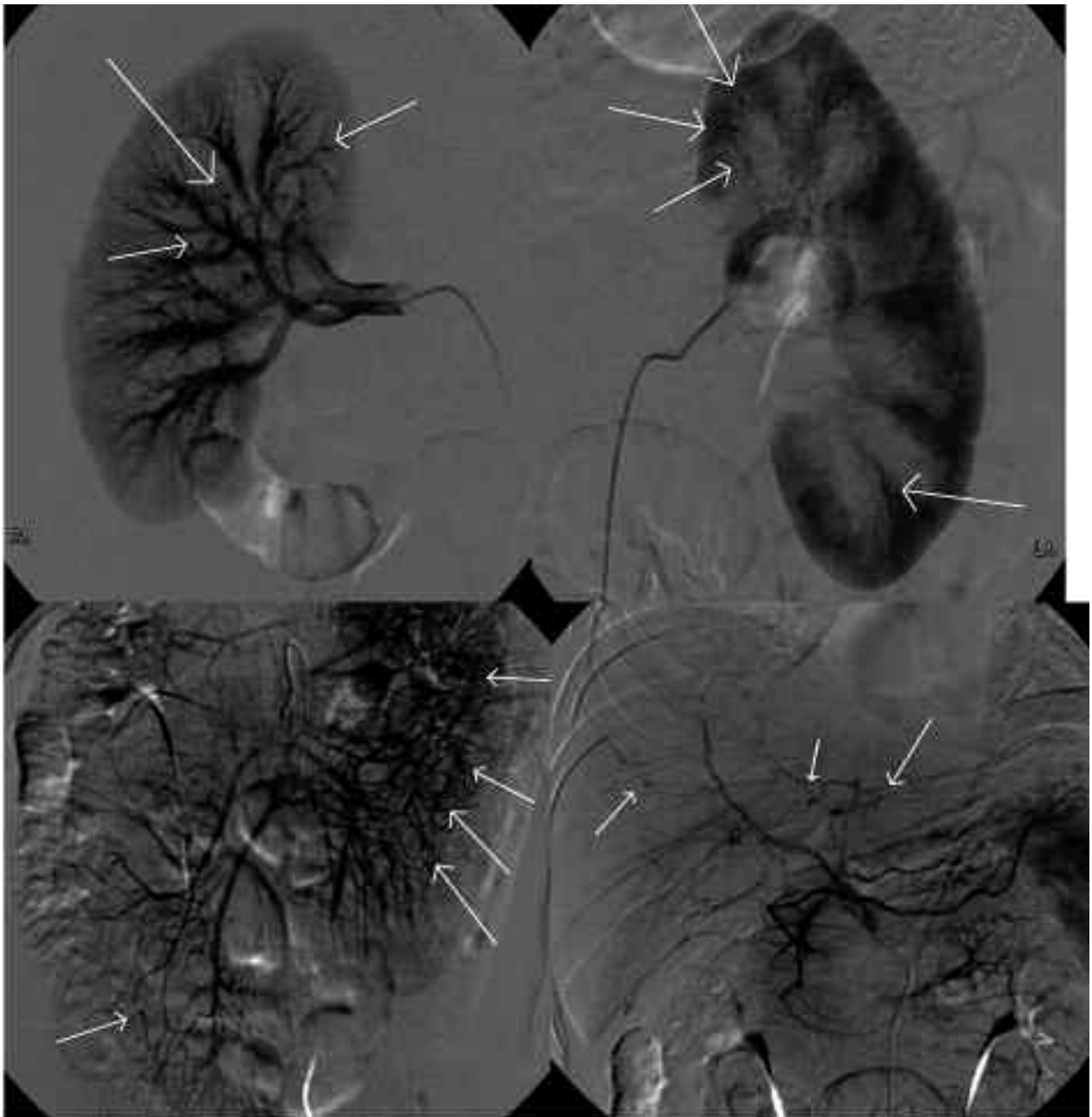

Fig. 2. Multiple small aneurysms in both renal arteries, small bowel branches, mesenteric arteries, branches of intercostals artery and hepatic artery suggesting systemic vasculitis such as polyarteritis nodosa

82.2%, and a reported specificity of 86.6% for the classification of polyarteritis nodosa compared with other vasculitides (13).

In this case, the patient presented with weight loss over 4 kgs, general myalgia including hip joint and shoulders, DBP over 90 mmHg, polyneuropathy,

and abnormal arteriographic features. It was not difficult to diagnose PAN despite the absence of a biopsy result since the patient showed typical arteriographic findings, such as multiple aneurysms on hepatic, mesenteric, and both renal arteries (1).

This case had a long standing history of asthma, and we should consider Churg-Strauss syndrome as a differential diagnosis. However, the absence of peripheral eosinophilia, negative ANCA and no evidence of lung parenchymal involvement were all favorable aspects of polyarteritis nodosa rather than Churg-Strauss syndrome (10, 14). In addition, small, typical aneurysms of the renal, mesenteric, and hepatic arteries were compatible with polyarteritis nodosa.

After reviewing the available literature, there was no premortem case of a well documented bronchial arteritis in PAN. Matsumoto et al (15) described a detailed pathologic analysis of lung involvement in 10 autopsied cases of PAN. In this report, only 3 of the 10 patients were diagnosed with PAN prior to death. There was clear evidence of a vasculitis affecting the bronchial arteries present in 7 of the cases without involvement of the pulmonary arteries (15). These findings suggest that bronchial involvement is a more frequent complication of PAN than was previously identified. But to our knowledge, this case is the first premortem diagnosis of bronchial arteritis in PAN.

In 2002, Hakanson et al. (16) reported a case of PAN presenting with massive hemoptysis. In this case, a chest CT scan showed a large aneurysm (15 cm diameter) of the descending aorta that had ruptured into the left lung resulting in a massive hemoptysis. The patient underwent emergency repair of the aneurysm. In the postoperative specimen, there was no evidence of PAN involvement but atherosclerosis(16).

In contrast, there were several reported cases (17-18) of premortem diagnosis of pulmonary arteritis in PAN. In 1996, Nick et al. (18) reported the first case of premortem diagnosis of pulmonary arteritis in PAN in which the patient had a good response to the treatment. In this report, a 62-yr-old white male presented with constitutive symptoms and RUQ pain. Chest radiograph and CT revealed diffuse patchy areas of consolidation. In the thoracoscopic lung biopsy, necrotizing arteritis of medium sized muscular pulmonary arteries was observed which was compatible with PAN. Moreover, arteriography of the abdominal aorta, superior and inferior mesenteric arteries demonstrated diffuse areas of irregularity and narrowing as well as aneurysms of the inferior mesenteric artery.

In general, the prognosis of untreated PAN is very poor. 1-year and 5-year survival rates are 50% and 13% (1). However, using steroid and other immunosuppressive drugs have prolonged the survival time. Recently, the reported 5 YSR was over 80% (19). Based on observational studies, remission may be induced in about 50% of cases with glucocorticoid alone. The combination of glucocorticoid and cyclophosphamide also appears to improve survival in patients with more severe disease when compared to steroid therapy alone (19-20).

Patients with a relatively mild case of the disease can be treated, at least initially, with prednisolone alone (1 mg/kg), and this regimen can spare the risk of adverse events associated with the use of cyclophosphamide or other immunosuppressive drugs.

Moderate and severe PAN (e.g., renal insufficiency, mesenteric artery ischemia, mononeuropathy multiplex) have better outcomes when treated with a combination of cyclophosphamide and glucocorticoid(20).

Since there has been no premortem case with well documented bronchial arteritis in PAN, we report a case of PAN involving the bronchial artery that initially presented as hemoptysis.

REFERENCES

1. Balow JE. Renal vasculitis. *Kidney Int* 1985; 27 (6): 954-64.
2. Lie JT. Systemic and isolated vasculitis. A rational approach to classification and pathologic diagnosis. *Pathol Annu* 1989; 24 Pt 1: 25-114.
3. Mahr A, Guillevin L, Poissonnet M, Ayme S. Prevalences of polyarteritis nodosa, microscopic polyangiitis, Wegener's granulomatosis, and Churg-Strauss syndrome in a French urban multiethnic population in 2000: a capture-recapture estimate. *Arthritis Rheum* 2004; 51 (1): 92-9.
4. Reinhold-Keller E, Zeidler A, Gutfleisch J, Peter HH, Raspe HH, Gross WL. Giant cell arteritis is more prevalent in urban than in rural populations: results of an epidemiological study of primary systemic vasculitides in Germany. *Rheumatology (Oxford)* 2000; 39 (12): 1396-402.
5. Haugeberg G, Bie R, Bendvold A, Larsen AS, Johnsen V. Primary vasculitis in a Norwegian community hospital: a retrospective study. *Clin Rheumatol* 1998; 17 (5): 364-8.
6. Watts RA, Lane SE, Bentham G, Scott DG. Epidemiology of systemic vasculitis: a ten-year study in the United Kingdom. *Arthritis Rheum* 2000; 43 (2): 414-9.
7. Watts RA, Gonzalez-Gay MA, Lane SE, Garcia-Porrúa C, Bentham G, Scott DG. Geoepidemiology of systemic vasculitis: comparison of the incidence in two regions of Europe. *Ann Rheum Dis* 2001; 60 (2): 170-2.
8. Watts RA, Lane SE, Scott DG, Koldingsnes W, Nossent H, Gonzalez-Gay MA, Garcia-Porrúa C, Bentham GA. Epidemiology of vasculitis in Europe. *Ann Rheum Dis* 2001 Dec; 60(12):1156-7.

9. Guillevin L, Mahr A, Callard P, Godmer P, Pagnoux C, Leray E, Cohen P. Hepatitis B virus-associated polyarteritis nodosa: clinical characteristics, outcome, and impact of treatment in 115 patients. *Medicine (Baltimore)* 2005; 84 (5): 313-22.
10. Lightfoot RW, Jr. Churg-Strauss syndrome and polyarteritis nodosa. *Curr Opin Rheumatol* 1991; 3 (1): 3-7.
11. Ramos-Casals M, Munoz S, Medina F, et al. Systemic autoimmune diseases in patients with hepatitis C virus infection: characterization of 1020 cases (The HISPAMEC Registry). *J Rheumatol* 2009; 36 (7): 1442-8.
12. Hasler P, Kistler H, Gerber H. Vasculitides in hairy cell leukemia. *Semin Arthritis Rheum* 1995; 25 (2): 134-42.
13. Lightfoot RW Jr., Michel BA, Bloch DA, et al. The American College of Rheumatology 1990 criteria for the classification of polyarteritis nodosa. *Arthritis Rheum* 1990; 33 (8): 1088-93.
14. Lanham JG, Elkon KB, Pusey CD, Hughes GR. Systemic vasculitis with asthma and eosinophilia: a clinical approach to the Churg-Strauss syndrome. *Medicine (Baltimore)* 1984; 63 (2): 65-81.
15. Matsumoto T, Homma S, Okada M, et al. The lung in polyarteritis nodosa: a pathologic study of 10 cases. *Hum Pathol* 1993; 24 (7): 717-24.
16. Hakanson E, Konstantinov IE, Fransson SG, Svedjeholm R. Management of life-threatening haemoptysis. *Br J Anaesth* 2002; 88 (2): 291-5.
17. Cogen FC, Mayock RL, Zweiman B. Chronic eosinophilic pneumonia followed by polyarteritis nodosa complicating the course of bronchial asthma. Report of a case. *J Allergy Clin Immunol* 1977; 60 (6): 377-82.
18. Nick J, Tuder R, May R, Fisher J. Polyarteritis nodosa with pulmonary vasculitis. *Am J Respir Crit Care Med* 1996; 153 (1): 450-3.
19. Gayraud M, Guillevin L, le Toumelin P, et al. Long-term followup of polyarteritis nodosa, microscopic polyangiitis, and Churg-Strauss syndrome: analysis of four prospective trials including 278 patients. *Arthritis Rheum* 2001; 44 (3): 666-75.
20. Leib ES, Restivo C, Paulus HE. Immunosuppressive and corticosteroid therapy of polyarteritis nodosa. *Am J Med* 1979; 67 (6): 941-7.