

## SUDDEN DEATH FROM SYSTEMIC SARCOIDOSIS: A CASE OF LEGAL MEDICINE

R. Zoja, S. Andreola, G. Gentile, A. Rancati

Dipartimento di Morfologia Umana e Scienze Biomediche, Sezione di Medicina Legale e delle Assicurazioni, Università degli Studi di Milano, Milano, Italy

**ABSTRACT.** *Introduction:* The sarcoid condition of vital organs such as heart, lungs, liver and brain, may constitute, though rarely, a dangerous situation for survival. In forensic pathology, sudden death related to such disease represents an unusual event occurring in subjects who die unexpectedly in spite of their previous good health, and whose autopsy reveals, mainly, the involvement of heart or the central nervous system (CNS). *The case:* The Authors describe a case of sudden death due to systemic sarcoidosis with atypical presentation in a young South American nulliparous woman showing, as the only symptom, occasional episodes of spotting during the last two months of her life. *Results:* The only noteworthy finding from the autopsy resulted in secondary obstructive hydrocephalus. The subsequent forensic toxicological examination was negative, whereas the histopathological examination, conducted by means of post-fixation techniques and standard coloring methods on the viscera removed during autopsy, revealed useful data to determine the cause of death, consisting of a diffuse inflammatory reaction with giant cells and epithelioid cells of sarcoid type localized in the CNS and in the genitourinary apparatus. *Conclusions:* The case presented, ranking among deaths occurred unexpectedly, is a useful opportunity both for clinical remarks, given its inherent diagnostic difficulties, especially in the presence of atypical symptoms, and for legal medicine ones, given the inclusion of sarcoidosis in cases of sudden death that can give rise to criminal investigations. (*Sarcoidosis Vasc Diffuse Lung Dis* 2012; 29: 62-68)

**KEY WORDS:** systemic sarcoidosis, non caseating granuloma, sudden death, legal medicine, forensic pathology

### INTRODUCTION

Sudden death caused by sarcoidosis is certainly exceptional. In fact, clinical literature includes very few cases that might belong to this category according to clinical and forensic definition. Chronicity of this disease has been well defined since the time of

Hutchinson (1) who described its site on the skin (2) at the end of the nineteenth century and denominated it after a second remark (3). Then the study of skin, lymph nodes and other involved organs biopsies (4) permitted the description of the sarcoid (5, 6). When skin (erythema pernio) (7) and visceral manifestations had been recognized as expressions of the same disease (8), related studies were continued, but precise etiology and clinical features of the disease were not found (9). Thanks to the American Thoracic Society, we have diagnostic and therapeutic protocols (10) of the disease, throughout the world and in every ethnic group, which predominantly affects young people and young adults of both sexes (11) with a 2:1 ratio between males and females (12) and a greater preva-

Received:

Accepted after Revision:

Correspondence: Prof. Riccardo Zoja

Sezione di Medicina Legale, Università degli Studi,

Via Luigi Mangiagalli, 37, 20133 Milano, Italy

Tel. +390250315685

Fax +390250315724

E-mail: riccardo.zoja@unimi.it

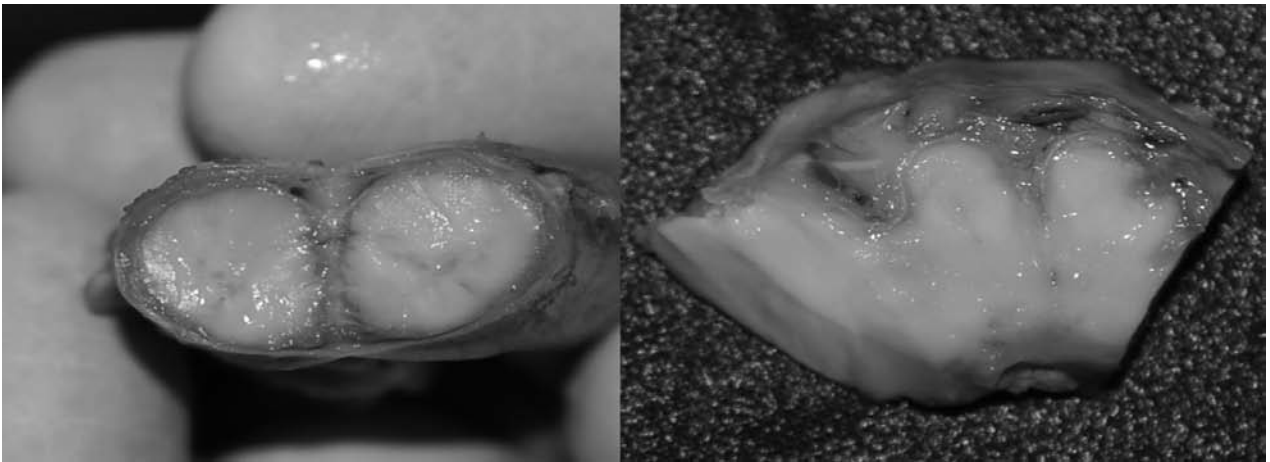
lence in blacks than in whites (13). Its features pertain to a chronic inflammatory disease (14), multisystemic (15), difficult to diagnose and of unknown etiology (16). Skin lesions, consisting of noncaseating granulomas (17), may appear as its only manifestation, as well as morbidity of lymph nodes and lung (18), the latter involved in 75% of cases (19) in bilateral hilar lymphadenopathy and parenchymal infiltration (10). Granulomatous disease may, however, involve other organs (20) and combine with systemic disorders (21), locating on bones (10), skin (16), eyes (22), and lacrimal glands (23), salivary glands (10), heart (23) and muscles (10), peritoneum (23), liver and spleen (18), CNS (10) and the urogenital organs (13). However, the absence of cutaneous manifestations (a noteworthy symptom for a patient) is actually considered to be a possible expression of the disease. The case presented here relates to a story in which the diagnosis of sarcoidosis was made only at the dissecting table, within a paucisymptomatic event despite the advanced state of disease that led to a decease clearly definable as unexpected death.

## THE CASE

A young South American woman aged 24, who had been residing in Italy for about a year since her marriage, was found unconscious at home by her husband when he came back from work in the evening. The couple had left home as usual in the morning. She was rescued and taken to hospital; there, she died shortly after despite resuscitative measures. The medical records presented by her husband showed nothing significant; the girl had never undergone surgical or medical services, was nulliparous, had a regular life style, and she was not taking any medication or alcohol or drugs. She worked as a waitress in a hotel. In the last two months of her life, she complained about occasional episodes of spotting, but she did not undergo any gynecological examination. For about a week before her death, she had been experiencing a deep fatigue and stated that she did not feel like working as requested to. The night before, feeling sick, she had no dinner, and even referred to retching without vomiting. The Court, on suspicion of possible criminal causes, ordered the examination of her corpse at the Institute of Legal Medicine.

## NECROPSY FINDINGS

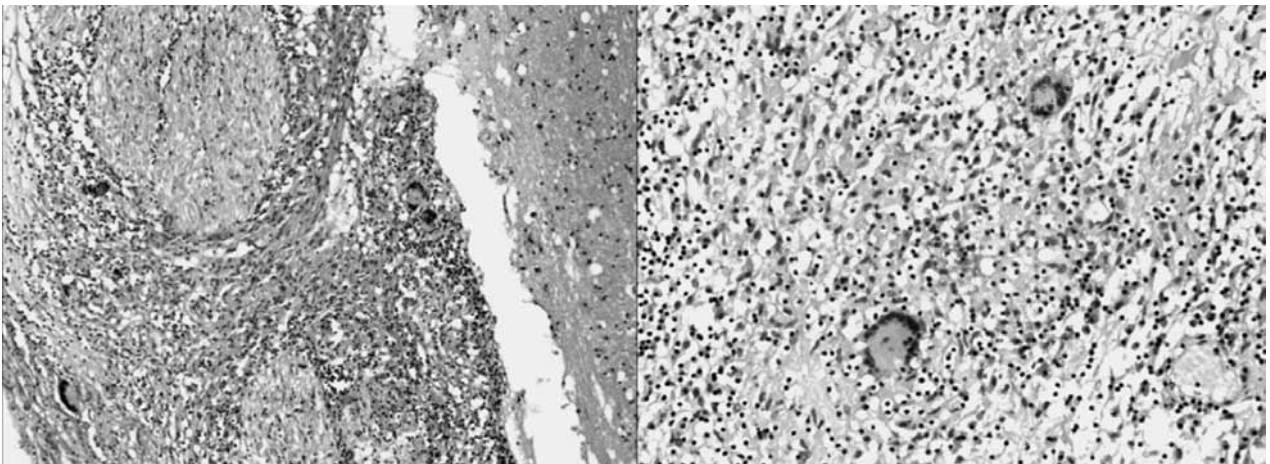
The corpse of the young woman, weighing 54 kg and 158 cm tall, showed a proper nutritional state at the dissecting table and was well-preserved; no signs somehow meaningful or due to any harm were evident to external examination. A detailed observation of the skin did not reveal any pathological aspect on any of its surface. Head dissection evidenced the dura mater firmly adherent to the neurocranium, and thickened and fibrotic leptomeninges, opaqued, in all their entirety (Figure 1). The brain, with flatter convolutions and shallower furrows than usual, showed small areas of discoloration on its surface, thin and atrophic parenchyma with dilated lateral ventricles filled with cerebrospinal fluid, as a result of hydrocephalus. At thorax dissection the lungs, weighing 320 g the left and 370 g the right, appeared homogeneous in their aspect, violaceous and expanded; they showed an increased consistency and an emission of whitish foam at their cut and pressing. The heart, weighing 230 g, of normal shape and volume, showed smooth and bright epicardium, regular parietal and valvular endocardium, pale myocardium with well preserved fascicles and absence of pathologic finding. Abdominal and urogenital viscera appeared, macroscopically, free from injury and corresponded to the age of the victim, with the exception of the bilateral lateral cervical lymph nodes and of the pelvic lymph nodes, all increased in size and showing hard-elastic consistency. After the autopsy, all the parts of the brain, spinal cord, heart and genitals were extracted together with fragments of all the other organs and body fluids, as required by subsequent toxicological and histopathological laboratory investigations. Chemical-toxicological investigations carried out on body fluids and organs at the Division of Forensic Toxicology, University of Milan, were completely negative. From all the pieces of organs, removed and fixed in 10% buffered formalin, histological specimens were prepared by standard methods with 2  $\mu$  thick laminar sections, then stained with Hematoxylin-Eosin. Through observation by optical and transmitted light microscope Leika DM E Microsystem, important findings were highlighted, mostly in the CNS and genital organs. In fact, a widespread inflammatory reaction with giant cells and sarcoid type epithelioids, with leptomeningeal localization, was evident at the bridge,



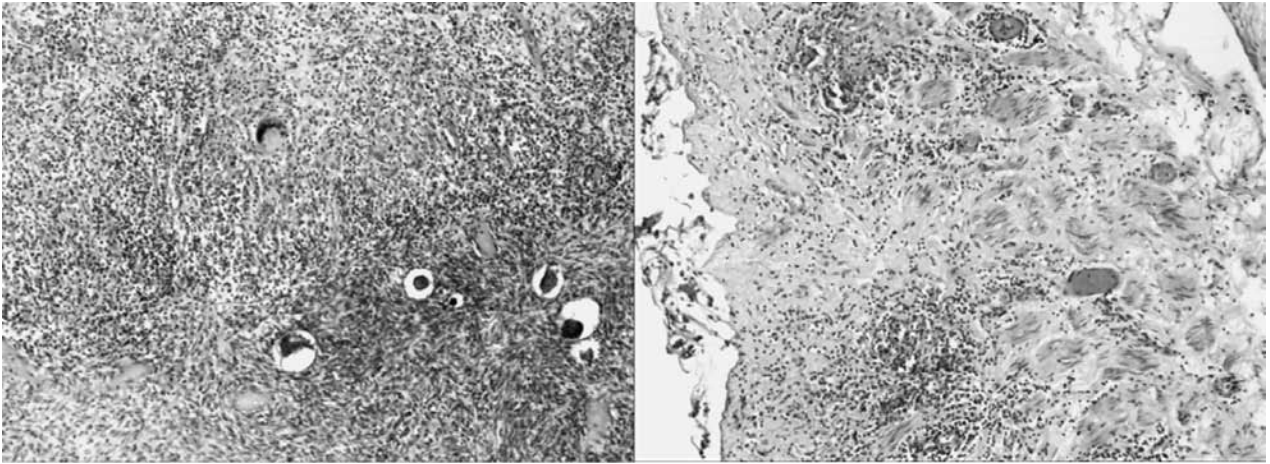
**Fig. 1.** Macroscopic views of sections of spinal cord (left), brain (right) with significant leptomenigeal thickening and clouding

medulla oblongata, cerebellum, optic chiasm, spinal cord (cervical, thoracic and abdominal), the inner wall of the lateral ventricles of the brain, with an initial perivascular distribution to the adjacent brain substance (Figure 2). Other similar granulomas were seen on perianaxial tissue, on ovarian surface, bilaterally, and on uterus (Figure 3). After the death, enzymatic and microbiological investigations aren't useful for the autolytic cell destruction, so histological specimens were also stained with specific histochemical stains to exclude other granulomatous diseases: Ziehl Neelsen (tuberculosis), Warthin Starry (syphilis), Periodic Acid-Schiff and Mucicarmine

(mycosis); they were completely negative. No other organ was found to contain sarcoid nodules to the extent that the disease could be regarded as systemic with nervous and genital involvement. In particular, histopathological laboratory investigations of thoracic viscera proved they weren't affected by sarcoidosis but lungs showed only edema and hematic stasis and heart showed interstitial edema in anterior and posterior walls of left ventricle, intraventricular septum and right ventricle and dissociation of muscle fibers especially in the septum where they appeared more contracted, thin and wavy. The characteristics of the microscopic findings led to a clear



**Fig. 2.** On the left, microscopic visions of medulla oblongata showing granulomas with giant cells and epithelioids clearly located around nerve roots - (Hematoxylin-Eosin, 100X). On the right, of optic chiasm, at higher magnification - (Hematoxylin-Eosin, 200X) -, showing granulomas with plurinucleated giant cells and epithelioids with no evidence of necrosis



**Fig. 3.** On the left, microscopic visions of an ovary with giant-cell and epithelioid granulomas in the parenchyma close to some oocytes - (Hematoxylin-Eosin, 100X). On the right, of the uterus, at higher magnification - (Hematoxylin-Eosin, 100X) - with two small giant-cell and epithelioid granulomas at the outer portion of the uterine wall

diagnosis of polyvisceral sarcoidosis and provided a full explanation of what was observed during the autopsy. The cause of death was therefore identified as sarcoidosis involving the central nervous system and ovaries accompanied by secondary acute hydrocephalus. The results of forensic investigations have ruled out criminal acts in determining the cause of death.

## DISCUSSION

The case under our observation is certainly exceptional as to how it occurred and to its poverty of symptoms in an advanced stage of the disease, which resulted in considering suspect a case of unexpected death caused by sarcoidosis diagnosed only at autopsy. In sarcoidosis, involvement of the CNS occurs rarely (24) and is estimated at 5-10% (25), with a mortality of 10% amounting to more than double the total for sarcoidosis (26). The disease comes in the form of granulomatous infiltration of the spinal meninges in less than 1% of cases (27) or of the brain meninges in 40-60% of cases of neurosarcoidosis (28); it may also be distributed in the spinal cord and in the brain parenchyma preferring basal venues such as optic chiasm and hypothalamus (29). Specific literature enumerates cases of general sarcoid damage with primitive spinal cord manifestation (25), as well as cases of neurological disorders not supported,

however, by a diagnosis of systemic sarcoidosis (30). Neurological sequelae, showing an entity dependent on the affected structures of the neuraxis (31), can cause interpretation (30) and diagnostic (32) problems. Usually, main clinical symptoms include cranial nerve neuropathy, particularly of the facial nerve (30), which causes temporary facial hemiparesis in 50% of cases (33), aseptic meningitis as a non-constant finding (34), and hydrocephalus in 5-7% of cases (35), considered as an uncommon (33) life-threatening (36) complication. Although the latter manifestation could occur as a result of chronic meningitis with flow obstruction of cerebrospinal fluid (37) or of granulomatous infiltration (38) associated with compression of the entire brain ventricular system (39), it can also arise as a primary manifestation of neurosarcoidosis (33). But the main neurosarcoid event (40) is hypothalamic dysfunction (41), due to granulomatous infiltration of the nuclei (42) and to their destruction (40), events having a significant impact on the neuroendocrine system (41) such as diabetes insipidus, polyuria and polydipsia, consequences of an irregular control of the antidiuretic hormone (43), hyperprolactinemia (44) and hypothalamic syndrome (45), excessive sleepiness preceded by insomnia (46), and body temperature dysregulation (47) as well as obesity and deficiency of the growth hormone (48). In the examined case, neurological symptoms were virtually absent and presented no motor or sensory symptoms, no

progressive intracranial hypertension (with the exception of slight symptoms of nausea and the sensation of incipient vomiting experienced the evening before death), and the lethal mechanism manifested in a dramatic way. The absence of any medical examination performed before death, no data can suggest any changes in biochemical parameters for this case: however, given the encephalic sites affected by major sarcoid changes, it is likely that main biochemical indexes underwent no changes. The localization of sarcoidosis is a rare urogenital (49) clinical entity in both sexes (16) occurring in 0.2% of clinically diagnosed cases and 5% of autopsy studies, (13) with a frequency 10 times higher in blacks (50). As to the urological tract, the kidney is the most frequently affected site (13), with clinical manifestations ranging from renal insufficiency due to granulomatous interstitial nephritis to nephrocalcinosis (26). In the case of the genital system, sarcoid granulomas have been reported in males against the epididymis (51), testis (52) and prostate (53) and, more rarely, the spermatic cord (54), scrotum (55) and penis (56). Sarcoid involvement of the female reproductive tract concerns, first, the uterus (14), particularly the endometrium (57) with abnormal bleeding and development of granulomatous endometritis, even in women with systemic sarcoidosis (58). Second, the cervix (15), fallopian tubes (14, 20) even with systemic spread (59), placenta, and vagina (15); less frequently, the disease can affect the vulva (12) and also these cases are characterized as cutaneous manifestations of systemic disease (16). Involvement of the ovary (18) is considered exceptional, especially if localized bilaterally, even when occurring as an isolated finding or as a manifestation of general disorder (60). The case under examination confirmed the common association of uterine and ovarian localization while noting, bilaterally, a prevailing presence of granulomas in the tissue surrounding the ovaries with less involvement of the parenchyma: a situation not frequently observed in the dissemination of the disease that fully justifies the reported gynecological symptoms that are, in practice, the only major event occurred, even though not carefully considered by the patient. For the pathological diagnosis of sarcoidosis is necessary a differential diagnosis with other granulomatous diseases (9), such as tuberculosis, syphilis, lymphogranuloma venereum (16) mycosis (11, 14, 61), parasitosis (62) and lym-

phoma (63). To improve the diagnosis of the specific sarcoidotic granuloma, characterized by central necrosis (64), it is usually necessary the use of appropriate histopathological coloring techniques (15) that optimize research of these lesions (Ziehl-Neelsen, Gomori silver-impregnation, mucicarmine, PAS, Movat's pentachrome). Another frequent histological finding for sarcoidosis is represented by giant cells derived from, macrophages, generated by the fusion of these latter elements into large multinucleated cells (9). However, as demonstrated in the examined case, a careful and appropriate sampling technique, setting, inclusion and preparation, can lead to excellent diagnostic results even by use of more diffused and usual staining (Hematoxylin - Eosin). The case presented here shows how sarcoidosis is a disease with wide variability in symptoms, and confirms how difficult a diagnosis can be in many cases concerning living subjects: although rare, cases in which a diagnosis is reached only by autopsy, are yet a clinical reality. Literature considers as exceptional such situations where sarcoidosis is responsible for a sudden death in which the disease plays an exclusive causal role and not merely incidental (65). Our observation confirms that, in these cases, the CNS is one of the most important sites together with the heart (65-67), with possible lethal development especially due to involvement of the pontine bulb (33) with life-threatening obstructive hydrocephalus (68). The main feature of the case that we observed is precisely the minimal presence of symptoms with exclusively gynecological events consisting in the uterus - ovarian involvement of the disease: this aspect highlights a constant need for careful attention as sarcoidosis represents a disease that must be included often within clinical diagnostic-differential hypotheses because of its ability to manifest itself mainly in a site that is not the one with the highest functional dignity, and to determine the fastest lethal effects.

## BIBLIOGRAFIA

1. Hutchinson J. Case of livid papillary psoriasis. Illustrations of clinical surgery. London: J and A Churchill 1877:42.
2. Young RC, Rachal RE, Cowan CL. Sarcoidosis-the beginning: historical highlights of personalities and their accomplishments during the early years. *Natl Med Assoc* 1984; 76(9): 887-96.
3. Hutchinson J. Cases of Mortimer's malady (lupusvulgaris multiplex, non-ulcerans and non-serpiginous). *Arch Surg* 1898; 9: 307-14.

4. Boeck C. Further observations on multiple benign sarcoidosis of the skin. *Festschr F Kaposi*, 1900; 153-68.
5. Boeck C. Multiple benign sarcoid of the skin. *J Cutan Gen Urin Dys* 1899; 17: 543-50.
6. Boeck C. Multiple benign skin sarcoid. *Norsk Mag Laegevid* 1899; 14: 1321-34.
7. Besnier E. Lupus pernio of the face: Fungoid synovitis, scrofulo-tuberculosis of the upper extremities. *Ann Dermatol Syph* 1889; 10: 333-6.
8. Schaumann J. On Lupus Pernio. Memoirs Presented in November 1914 to the French Society of Dermatology and Syphilology for the Zambaco Prize. Paris: Norstedt and Soner, 1934.
9. Dail DH, Hammar SP. Pulmonary Pathology. Nonneoplastic lung disease. Vol. I. Springer, Third Edition, 2008; 668-94.
10. ATS Hunninghake GW, Costabel U, Ando M, et al. ATS/ERS/WASOG statement on sarcoidosis. American thoracic society/european respiratory society/world association of sarcoidosis and other granulomatous disorder. *Sarcoidosis vasc diffuse lung dis* 1999; 16(2): 149-73.
11. Hillerdal G, Nou E, Osterman K, Schmekel B. Sarcoidosis: epidemiology and prognosis; a 15-year European study. *Am Rev Respir Dis* 1984; 130: 29-32.
12. Ezughah FI, Ghaly AF, Evans A, Green CM. Vulval sarcoid: a systemic presentation of sarcoidosis. *J Obstet Gynaecol* 2005; 25(7): 730-2.
13. Khan SA, Richenberg JL, Fletcher MS. Scrotal swelling in sarcoidosis. *J R Soc Med*. 2004; 97(10): 487-8.
14. Rosenfeld SI, Steck W, Breen JL. Sarcoidosis of the female genital tract: a case presentation and survey of the world literature. *Int J Gynecol Obstet* 1989; 28: 373-80.
15. Allen SL, Judson MA. Vaginal involvement in a patient with sarcoidosis. *Chest* 2010; 137(2): 455-6.
16. Decavalas G, Adonakis G, Androutopoulos G, Gkermepesi M, Kourounis G. Sarcoidosis of the vulva: a case report. *Arch Gynecol Obstet* 2007; 275(3): 203-5.
17. Johns CJ, Michele TM. The clinical management of sarcoidosis. *Medicine* 1999; 78: 65-111.
18. Wuntakal R, Bharathan R, Rockall A, Jeyarajah A. Interesting case of ovarian sarcoidosis: the value of multi disciplinary team working. *World J Surg Oncol* 2007; 29: 5-38.
19. Esser R, Rothenberger KH. Sarcoidosis of the spermatic cord and epididymus. *Aktuelle Urol* 2003; 34(5): 354-5.
20. Chalvardjian A. Sarcoidosis of the female genital tract. *Am J Obstet Gynaecol* 1978; 132: 78-80.
21. Wei H, Friedman KA, Rudikoff D. Multiple indurated papules on penis and scrotum. *J Cutan Med Surg* 2000; 4(4): 202-4.
22. Römer T, Schwesinger G, Foth D. Endometrial sarcoidosis manifesting as recurrent serometra in a postmenopausal woman. *Acta Obstet Gynecol Scand* 2001; 80(5): 482-3.
23. Fuchs F, Le Tohic A, Raynal P, et al. Ovarian and peritoneal sarcoidosis mimicking an ovarian cancer *Gynecol Obstet Fertil* 2007; 35(1): 41-4.
24. Joseph FG, Scolding NJ. Neurosarcoidosis: a study of 30 new cases. *J Neurol Neurosurg Psychiatry* 2009; 80: 297-304.
25. Tsai CF, Yip PK, Yang CC. Neurosarcoidosis Affecting the Spinal Cord-Case report. *J Formos Med Assoc* 2010; 109(9): 676-9.
26. James DG. Life-threatening situations in sarcoidosis. *Sarcoidosis vasc diffuse lung dis*. 1998; 15(2): 134-9.
27. Makino T, Ito S, Mori M, Kuwabara S. Diffuse neurosarcoidosis involving only the leptomeninges of the brainstem and spinal cord. *Intern Med* 2009; 48(21): 1909-13.
28. Smith JK, Mathews MG, Castillo M. Imaging manifestations of neurosarcoidosis. *Am J Roentgenol* 2004; 182: 289-95.
29. Ropper AH, Brown RH. Adams e Victor-Principi di Neurologia-VI-II Edizione 2006. Mc Graw Hill 665-6.
30. Stern BJ, Krumholz A, Johns C, et al. Sarcoidosis and its neurological manifestations. *Arch Neurol* 1985; 42: 909-17.
31. Vargas DL, Stern BJ. Neurosarcoidosis: diagnosis and management. *Semin Respir Crit Care Med*. 2010; 31(4): 419-27.
32. Zajicek JP, Scolding NJ, Foster O, et al. Central nervous system sarcoidosis diagnosis and management. *QJM* 1999; 92: 103-17.
33. Lee CH, Jung YS, Lee SH. Hydrocephalus as a presenting manifestation of neurosarcoidosis: easy to misdiagnose as tuberculosis. *J Korean Neurosurg Soc*. 2010; 48(1): 79-81.
34. Waxman JS, Sher JH. The spectrum of central nervous system sarcoidosis: A clinical and pathologic study. *Mt Sinai J Med* 1979; 46: 309-17.
35. Brouwer MC, de Gans J, Willemsse RB, van de Beek D. Neurological picture. Sarcoidosis presenting with hydrocephalus *J Neurol Neurosurg Psychiatry*. 2009; 80(5): 550-1.
36. Kendall BE, Tatler GLV. Radiological findings in neurosarcoidosis. *Br J Radiol* 1978; 51: 81-92.
37. Delaney P. Neurologic manifestations in sarcoidosis: Review of the literature, with a report of 23 cases. *Ann Intern Med* 1977; 87: 336-45.
38. Whelan MA, Stern J. Sarcoidosis presenting as a posterior fossa mass. *Surg Neurol* 1980; 15: 455-7.
39. Kumpe DA, Krishna Rao CVG, Garcia JH, et al. Intracranial neurosarcoidosis. *J Comput Assist Tomogr* 1979; 3: 324-30.
40. Gleckman AM, Patalas ED, Joseph JT. Sudden unexpected death resulting from hypothalamic sarcoidosis. *Am J Forensic Med Pathol* 2002; 23(1): 48-51.
41. Atwood KS, Winternitz WW. Blindness and hypopituitarism thought to be due to sarcoidosis: A case report. *Ala J Med Sci* 1979; 16: 234-6.
42. Brust JCM, Rhee RS, Plank CR, et al. Sarcoidosis, galactorrhoea, and amenorrhoea: Two autopsy cases, one with Chiari-Frommel syndrome. *Ann Neurol* 1977; 2: 130-7.
43. Stuart C, Neelon F, Lebovitz H. Disordered Control of Thirst In Hypothalamic-Pituitary Sarcoidosis. *N Engl J Med* 1980; 303: 1078-82.
44. Turkington RW, Macindoe JH. Hyperprolactinaemia in Sarcoidosis. *Ann Intern Med* 1972; 76: 545-9.
45. Jawardi MH, Hanson TJ, Schemmel JE, Beck P, Katz FH. Hypothalamic sarcoidosis and hypopituitarism. *Hormone Res* 1980; 12: 1-9.
46. Colover J. Sarcoidosis with involvement of the nervous system. *Brain* 1948; 71: 451-5.
47. Jefferson M. Sarcoidosis of the nervous system. *Brain* 1957; 80: 540-56.
48. Veseky D, Maldonado A, Levey G. Partial Hypopituitarism and Possible Hypothalamic Involvement In Sarcoidosis. *Am J Med* 1977; 62: 425-30.
49. Neumann G, Rasmussen KL, Olesen H. Premenopausal metrorrhagia as a symptom of sarcoidosis. *Ur J Obstet Gynecol Reprod Biol* 2002; 104(2): 171-3.
50. Turk C, Schacht M, Ross L. Diagnosis and Management of Testicular Sarcoidosis. *J Urol* 1986; 135: 380-1.
51. Svetec DA, Waguespack RL, Sabanegh ES. Intermittent azoospermia associated with epididymal sarcoidosis. *Fertil Steril* 1998; 70(4): 777-9.
52. Real V, Loyola GL, Zanoni PE, Real LF. Testicular sarcoidosis: a diagnosis to be considered. *Rev Col Bras Cir* 2011; 38(2): 145-6.
53. Mulpuru SK, Gujja K, Pai VM, Chen CY, Levey RL. A rare and unusual cause of PSA (prostate-specific antigen) elevation: sarcoidosis of the prostate. *Am J Med Sci* 2008; 335(3): 246-8.
54. Gross AJ, Heinzer H, Loy V, Dieckmann KP. Unusual differential diagnosis of testis tumor: intrascrotal sarcoidosis. *Urol* 1992; 147(4): 1112-4.
55. Hassan A, El-Mogy S, Zalata K, Mostafa T. Bilateral epididymal sarcoidosis. *Fertil Steril* 2009; 91(5): 1957. e1-4.

56. Porter N, Beynon HL, Randeve HS. Endocrine and reproductive manifestations of sarcoidosis. *QJM* 2003; 96(8): 553-61.
57. Rosa e Silva JC, de Sá Rosa e Silva AC, Aguiar FM, Poli Neto OB, Candido dos Reis FJ, Nogueira AA. Isolated endometrial polypoid sarcoidosis in a post-menopausal patient: case report. *Maturitas* 2006; 53(4): 489-91.
58. Ho Kh. Sarcoidosis of the uterus. *Hum Pathol* 1979; 20: 219.
59. Boakye K, Omalu B, Thomas L. Fallopian tube and pulmonary sarcoidosis. A case report. *J reprod med* 1977; 42: 533-55.
60. White A, Floris N, Elmer D, Lui R, Famburg BL. Coexistence of mucinous cystadenoma of the ovary and ovarian sarcoidosis. *Am J Obstet Gynecol* 1990; 162: 1284-5.
61. Liang KV, Ryu JH, Matteson EL. Histoplasmosis with tenosynovitis of the hand and hypercalcemia mimicking sarcoidosis. *J Clin Rheumatol* 2004; 10(3): 138-42.
62. Teh LS, Coombes GM, MacDonald RH, Prescott RJ, Dietch DM, Jones AK. Acute sarcoidosis: a difficult diagnosis. *Rheumatology* 2000; 39(6): 683-5.
63. Scully RE, Mark EJ, McNeely WF, Ebeling SH. Case records of the Massachusetts General Hospital. Weekly clinicopathological exercises. A 54-year-old woman with a progressive gait disturbance and painful leg paresthesia. *N Engl J Med* 1998; 339: 1534-41.
64. Ricker W, Clark M. Sarcoidosis; a clinicopathologic review of 300 cases, including 22 autopsies. *Am J Clin Pathol* 1949; 19(8): 725-49.
65. Byard RW, Manton N, Tsokos M. Sarcoidosis and mechanisms of unexpected death. *Forensic Sci.* 2008; 53(2): 460-4.
66. Virmani R, Bures JC, Roberts WC. Cardiac sarcoidosis: A major cause of sudden death in young individuals. *Chest* 1980; 77: 423-8.
67. Perry A, Vuitch F. Causes of death in patients with sarcoidosis: A morphologic study of 38 autopsies with clinicopathologic correlations. *Arch Pathol Lab Med* 1995; 119: 167-72.
68. Maisel JA, Lynam T. Unexpected sudden death in a young pregnant woman: unusual presentation of neurosarcoidosis. *Ann Emerg Med* 1996; 28: 94-7.