

SARCOIDOSIS: VAGINAL WALL AND VULVAR INVOLVEMENT

F. Xu^{1*}, Y. Cheng^{1*}, R. Diao¹, X. Zhou¹, X. Wang¹, Y. Ma², W. Lv², H. Shen¹

¹Department of Respiratory and Critical Care Medicine, and ²Department of Gynecology, Second Affiliated Hospital, Zhejiang University School of Medicine, Hangzhou, China

ABSTRACT. Sarcoidosis is a non-caseous granulomatous disease which could involve numerous organs including lungs, eyes, skin, nervous system, heart, liver. However, the genitourinary tract involvement was rarely reported in sarcoidosis. We report the case of a 45-year-old married woman who presented with 2 months history of a vulval mass as large as a soybean, and did not reveal any remarkable pulmonary signs. Biopsy results showed non-caseous granulomatous inflammation consistent with sarcoidosis in the vulvar lesion. To our knowledge, this is the first reported case of this entity in the world. Based on the related literature, we highlight the possibility of gynecologic involvement in sarcoidosis. (*Sarcoidosis Vasc Diffuse Lung Dis* 2012; 29: 151-154)

KEY WORDS: sarcoidosis, gynecologic involvement

CASE REPORT

A 45-year-old married woman presented with 2 months history of a vulval mass as large as a soybean. There was no swelling, pain, vulval itching or causalgia, and other complaints. Other symptoms such as urinary frequency, cough, chest tightness, shortness of breath, blurred vision and night sweats were not revealed. The patient had regular menstrual cycles and no history of dysmenorrhea. Her menstrual flow was moderate, dark red and without clots. She had one daughter, and no history of cigarette smoking and alcohol abuse. The patient underwent a right ovary oophorectomy 10 years ago and a section

of right Bartholin's cyst 4 months ago. The histopathological results of these two operations showed benign cysts.

On physical examination, we found a firm and unpainful mass (1.5 cm × 1 cm) on the edge of an episiotomy scar in the outside of the left vulva, and a callous nodule (0.5 cm × 0.5 cm) in the left vaginal wall. Other abnormal physical signs were not found.

Baseline blood tests and angiotensin-converting enzyme (ACE) level were normal. The level of serum cancer antigen (CA)-125 was 43.1 U/mL (normal range <35U/mL). The PPD skin test was negative. Her spirometry showed an FVC of 3.46 L (110% predicted), an FEV1 of 2.94 L (108% predicted), an FEV1 /FVC of 0.85, an DLCO SB of 6.63 mmol/min /KPa (79% predicted). The ultrasound images of the vulva showed a low level echo of a nodule under the skin in the left vulva. There was no apparent abnormality seen in the Chest X-ray. The chest enhancement CT revealed reticulonodular infiltrates in bilateral lungs and mildly enlarged mediastinal lymph nodes (Fig. 1). Resections of the vulvar mass and vaginal wall nodule were performed.

Received: 1 December 2011

Accepted after Revision: 11 January 2012

Correspondence: Huahao Shen,
Department of Respiratory and Critical Care Medicine,
Zhejiang University School of Medicine,
88 Jiefang Road, Hangzhou, 31009, China
E-mail: hh_shen@yahoo.com.cn

* Dr. Feng Xu and Dr. Yusheng Cheng equally contribute to this manuscript

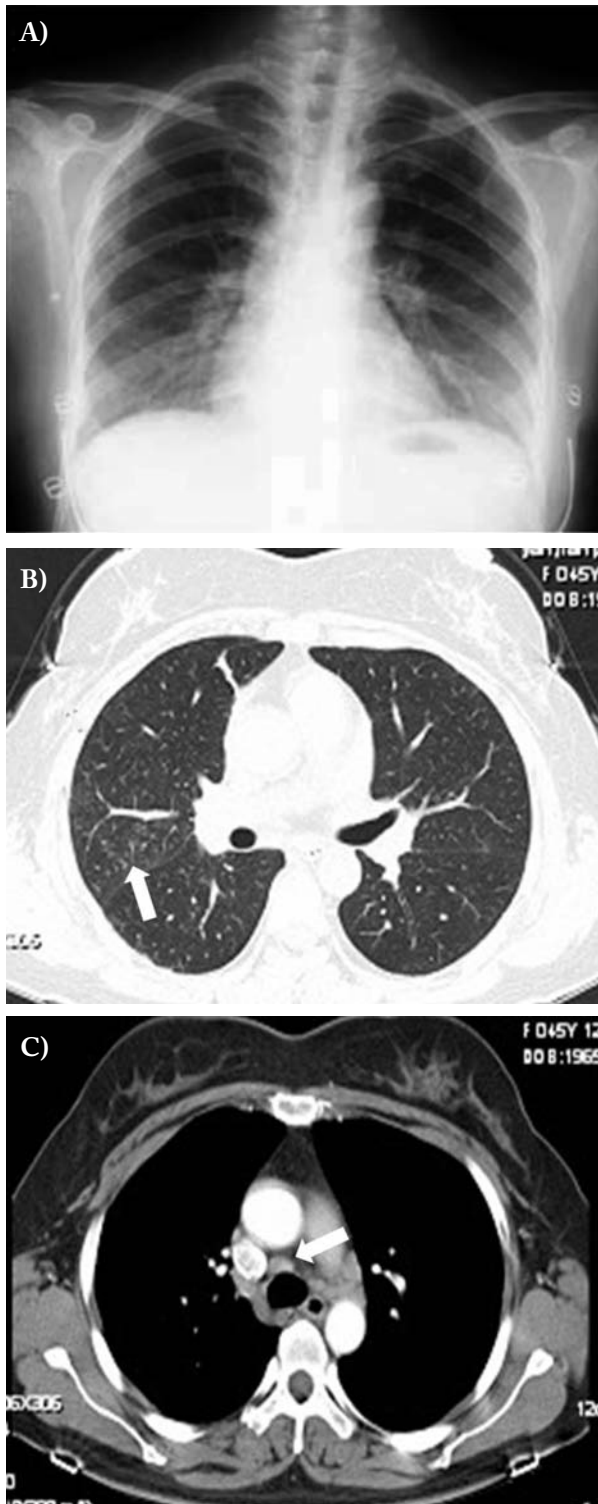


Fig. 1. The chest X-ray (A) showed no apparent abnormality whereas the chest CT scan (B-C) revealed reticulonodular infiltrates of bilateral lungs and mildly enlarged mediastinal lymph nodes (see arrows)

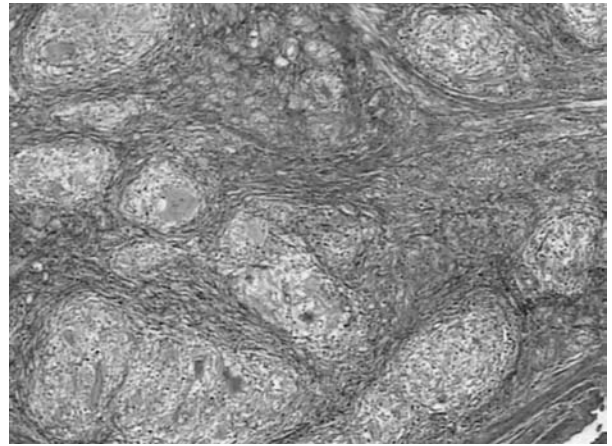


Fig. 2. H&E staining showed non-caseous granulomatous inflammation and necrosis in both the genital masses (magnification 40X)

Pathological examinations showed non-caseous granulomatous inflammation consistent with sarcoidosis in both the genital mass and the vaginal wall nodule (Fig. 2). PAS staining and acid-fast staining were negative for fungi and acid fast bacilli. Consistently, cultures for fungi and mycobacteria were also negative. A diagnosis of vaginal wall and vulval sarcoidosis is made after excluding other potential causes of granulomatous inflammation and cancer. Based on the staging result of the chest radiography (stage 0), glucocorticoid was not used to treat the patient. Presently, the patient is closely followed every 1 month.

DISCUSSION

Sarcoidosis is a multisystem granulomatous disease affecting many organs, mostly the lungs. The pathological features are noncaseous necrotic granuloma, which was first described in 1899 by Hutchinson. (1) The cause of sarcoidosis remains unclear. It may be related to the environment, genetic predisposition and disturbance of immune function for CD4⁺ T cells.

Sarcoidosis is clinically manifested with pulmonary involvement. Other commonly affected organs include eyes, skin, nervous system, heart, and liver. The male patient with sarcoidosis may present with a painless testicular swelling when genitouri-

Table 1. Published sarcoidosis cases involving the vulva or vagina

Cases	First involvement	Other involvements	Chief complaints	Images of lung (CXR or CT)	Diagnosis	Treatment	Follow-up	References
1	Vulva	Peri-anal skin	Papular rash on the vulva	Bilateral hilar lymphadenopathy and nodular shadowing in the lung fields	Vulval sarcoidosis	No record	No record	Tatnall, 1985 (4)
2	Vulva	Lung, facial skin	Pruritic and burning facial and vulval eruption	Normal	Vulval involvement in sarcoidosis	Hydroxy-chloroquine, chloroquine and corticosteroid	The vulval lesions persisted, but improved slightly	Klein, 1998 (5)
3	Vulva	Lung	Persistent itchy papules in the vulva	Hilar adenopathy and a bilateral reticulonodular pattern, bilateral multiple rounded pulmonary nodules	Sarcoidosis	Clobetasol propionate, flurandrenolone	Pulmonary and nodal disease has remained static	Ezugha, 2005 (6)
4	Vulva	Lung	Lesion associated with an scar in the left perineal area	Bilateral hilar lymphadenopathy	Vulval involvement in sarcoidosis	No treatment	Patient was still well, 12 months after operation	Decavalas, 2007 (7)
5	Vagina	Lung	Vaginal itching, irritation cough, wheezing on exertion, and night sweats	Bilateral hilar and mediastinal lymphadenopathy with diffuse multiple nodular opacities	Vaginal involvement in sarcoidosis	Corticosteroids and chloroquine	Clinical symptom improved, but still needed prednisone therapy	Allen, 2010 (3)

nary tract is involved whereas in female patients, sarcoidosis has also been reported with the involvement of fallopian tubes, ovaries, and uterus. (2,3) However, sarcoidosis of the vulva is a rare condition. Until now, only 6 cases of sarcoidosis with vaginal wall or vulval lesions have been reported in the world, and 5 cases published in English (Table 1) (3-7). Among them, actually only one case of sarcoidosis with the vaginal wall involvement has been reported previously. (3) Here we report a rare presentation of biopsy-confirmed sarcoidosis involving the vaginal wall and vulva. To our knowledge, this is the first reported case of this entity in the world.

The mass of sarcoidosis was found in the episiotomy scar of the left vulva in this case, in line with another study showing a skin scar is often involved.

(8) The laboratory examination showed elevated CA-125, a glycoprotein expressed by a variety of tissues of mesothelial origin. It was reported that patients with sarcoidosis in the peritoneum had higher levels of CA-125 than normal. (9)

Sarcoidosis generally has a good prognosis. Sixty percent of patients do not require treatment and the disease may spontaneously regress in some patients. Glucocorticoid and other immunosuppressants have been used to treat sarcoidosis for many years. However, their influence on the natural history of sarcoidosis is unclear. Our case had no bothersome signs and her vital organs were not at risk, therefore aggressive treatment was not adopted for her. After 1 year's follow-up, this patient is still in good condition.

REFERENCES

1. Dempsey OJ, Paterson EW, Kerr KM, Denison AR. Sarcoidosis. *BMJ* 2009; 339: b3206.
2. Vasu TS, Lai RS, Amzuta IG, Nasr MR, Lenox RJ. Sarcoidosis presenting as intrascrotal mass: case report and review. *South Med J* 2006; 99: 995-7.
3. Allen SL, Judson MA. Vaginal involvement in a patient with sarcoidosis. *Chest* 2010; 137: 455-6.
4. Tatnall FM, Barnes HM, Sarkany I. Sarcoidosis of the vulva. *Clin Exp Dermatol* 1985; 10: 384-5.
5. Klein PA, Appel J, Callen JP. Sarcoidosis of the vulva: a rare cutaneous manifestation. *J Am Acad Dermatol* 1998; 39: 281-3.
6. Ezughah FI, Ghaly AF, Evans A, Green CM. Vulval sarcoid: a systemic presentation of sarcoidosis. *J Obstet Gynaecol* 2005; 25: 730-2.
7. Decavalas G, Adonakis G, Androutopoulos G, Gkermepesi M, Kourounis G. Sarcoidosis of the vulva: a case report. *Arch Gynecol Obstet* 2007; 275: 203-5.
8. Veien NK, Stahl D, Brodthagen H. Cutaneous sarcoidosis in Caucasians. *J Am Acad Dermatol* 1987; 16: 534-40.
9. Kalluri M, Judson MA. Sarcoidosis associated with an elevated serum CA 125 level: description of a case and a review of the literature. *Am J Med Sci* 2007; 334: 441-3.