

Silicosis in finishing workers in quartz conglomerates processing

GABRIELLA GUARNIERI¹, SALASNICH MAURO², PAOLO LUCERNONI², MARTA SBARAGLIA³, MARIA GRAZIA PUTZU⁴, PAOLO ZULIANI⁴, FEDERICA ROSSI⁴, STEFANIA VIO⁵, LEONARDO BIANCHI¹, ANDREA MARTINELLI¹, OTTORINO GOTTARDO⁶, ROSANA BIZZOTTO⁶, PIERO MAESTRELLI¹, PAOLA MASON¹, MARIELLA CARRIERI¹

¹Department of Cardiac, Thoracic, Vascular Sciences and Public Health, University of Padua, Padua, Italy

²Respiratory Unit, Ca' Foncello Hospital, Azienda ULSS 2 Marca Trevigiana, Treviso, Italy

³Pathology Unit, Ca' Foncello Hospital, Azienda ULSS 2 Marca Trevigiana, Treviso, Italy

⁴Department of Public Health and Pediatric Sciences, University of Turin, Turin, Italy

⁵Radiology Unit, University Hospital, Padua, Italy

⁶SPISAL, Azienda ULSS6 Euganea, Padua, Italy

KEY WORDS: Silica dust; pneumoconiosis; quartz conglomerates; occupational exposure; artificial stones

PAROLE CHIAVE: Silice; pneumoconiosi; conglomerati di quarzo; esposizione professionale; materiali lapidei artificiali

SUMMARY

Introduction: Outbreaks of silicosis have been recently reported in artificial stone workers. **Aim:** To describe the features of silicosis in quartz conglomerate workers in North-Eastern Italy. **Methods:** Active search of pneumoconiosis was performed in 11 companies of North-Eastern Italy involved in the fabrication of quartz conglomerate countertops. Occupational history, lung function tests, chest X-ray and high resolution computed tomography (HRCT) were performed. In selected cases, trans-bronchial biopsies were taken for histological evaluation and identification of silica crystals in the tissue. Cumulative exposure to crystalline silica was estimated. **Results:** We recruited 45 workers and 24 cases of silicosis were diagnosed. Mean age at diagnosis was 43 years and duration of exposure to quartz conglomerate dust was 3.5 to 20 years. The average silica cumulative exposure was 4.3 mg/m³/y. Abnormal findings were detected in 42% of chest X-rays, in 33% of spirometry and 50% of carbon monoxide lung diffusion (DLco). HRCTs were abnormal in all cases showing well-defined rounded opacities, irregular/linear intralobular opacities and bilateral enlarged mediastinal lymph-nodes. Histological findings consistent with silicosis were observed in 24 cases. Numerous silica particles (diameter 0.1–5 µm) were identified in lung tissue. **Conclusions:** We reported an unexpected high incidence of silicosis in Italian workers exposed to quartz conglomerate dust. The results suggest that chest HRCT is indicated for screening of workers with high exposure to silica and DLco should be added to spirometry in health surveillance. More rigorous application of safety regulations and more effective preventive interventions at work are necessary.

RIASSUNTO

«**Silicosi in lavoratori addetti alla finitura di materiali lapidei artificiali**». **Introduzione:** Sono stati recentemente segnalati dei cluster di silicosi in lavoratori addetti alla lavorazione di materiali lapidei artificiali. **Scopo:** Descrivere le caratteristiche della silicosi nei lavoratori di conglomerati di quarzo nell'Italia Nord-Orientale. **Metodi:** È stata condotta una ricerca attiva dei casi di silicosi in 11 aziende dell'Italia Nord-Orientale coinvolte nella fabbricazione di

Received 20.12.2019 - Revised version 14.2.2020 - Accepted 19.3.2020

Corresponding author: Gabriella Guarnieri, Department of Cardiac, Thoracic, Vascular Sciences and Public Health, University of Padua, Padua, Via Giustiniani, 2 – 35128 Padova, Tel. +049 8212565, E-mail gabriella.guarnieri@unipd.it

piani di lavoro in conglomerati di quarzo. Sono stati eseguiti: anamnesi professionale, test di funzionalità polmonare, radiografia del torace e TC ad alta risoluzione (HRCT). In casi selezionati, sono state prese biopsie trans-bronchiali per la valutazione istologica e l'identificazione dei cristalli di silice nei tessuti. È stata calcolata l'esposizione cumulativa alla silice cristallina. **Risultati:** Abbiamo reclutato 45 lavoratori e sono stati diagnosticati 24 casi di silicosi. L'età media alla diagnosi era di 43 anni e la durata dell'esposizione a polvere di conglomerato di quarzo era compresa tra 3,5 e 20 anni. L'esposizione cumulativa media alla silice è stata di 4,3 mg/m³/anni. Sono stati rilevati risultati anomali nel 42% delle radiografie del torace e nel 33% delle spirometrie. La diffusione polmonare del monossido di carbonio (DLco) è risultata ridotta nel 50% dei casi. Le TAC ad alta risoluzione hanno evidenziato anomalie in tutti i casi mostrando opacità arrotondate ben definite, opacità intralobulari irregolari/lineari e linfonodi mediastinici allargati bilateralmente. Sono stati osservati reperti istologici compatibili con silicosi in 24 casi. Sono state identificate numerose particelle di silice (diametro 0,1-5 μm) nel tessuto polmonare. **Conclusioni:** È stata riscontrata un'incidenza inaspettatamente alta di silicosi nei lavoratori italiani esposti a polvere di conglomerati di quarzo. I risultati suggeriscono che la HRCT del torace è indicata per lo screening di lavoratori con elevata esposizione a silice e che nella sorveglianza sanitaria la misura della DLco dovrebbe essere aggiunta alla spirometria. Sono altresì necessari un'applicazione più rigorosa delle norme di sicurezza e interventi preventivi più efficaci sul lavoro.

BACKGROUND

Silicosis is one of the oldest occupational diseases known to humankind and is caused by inhalation of crystalline silica dust. This progressive disease induces pulmonary fibrosis, causing disability and even death, and has no treatment. In Israel there was a dramatic increase in the number of patients with silicosis, who underwent lung transplantation (6, 20). For this reason, strict control of workplace conditions, effective personal protective equipment and early detection are essential to modify or mitigate the clinical course. Despite this, however, clusters of silicosis cases related to the fabrication of quartz conglomerates, a new high-silica content artificial stone for kitchen and bathroom countertops, have been recently described in Israel, Spain, Australia, Belgium and the USA (5, 6, 11, 13, 17-22). Quartz conglomerates are based on polyester or acrylic resins bound with a high (70-90%) silica content, with the addition of metallic pigments. The exact pathogenic mechanism of silica particles remains one of the main issues in toxicology. Recent developments in the surface chemistry of silica, cell biology and toxicology have provided new data regarding the variable reactivity of silica particles due to surface configuration and chemical characteristics (16, 23). No data on workplace dust levels were available from most of the previous studies on quartz conglomerates, except the case report of Paolucci et al. and in our previous study (4, 15). The studies report-

ed levels of airborne crystalline silica 10 to 30 times higher than the threshold limit value according to the American Conference of Governmental Industrial Hygienists (ACGIH) (0.025 mg/m³) or 5 to 15 times higher than the limit of 0.05 mg/m³ proposed more recently by the Scientific Committee on Occupational Exposure Limits (SCOEL).

The main objective of this study was to describe the incidence and clinical, functional, and radiological characteristics of silicosis detected in North-Eastern Italy in workers involved in the fabrication of quartz conglomerate countertops.

METHODS

Study Design

Between September 2016 and July 2019 an active search of pneumoconiosis was performed by the Local Authorities for Occupational Health within their Prevention Programs in the companies of North-Eastern Italy involved in the fabrication of quartz conglomerate countertops. The search for local companies was carried out using a specific identification code from the National Register. The only criterion for the inclusion of workers in the study was an occupational exposure to dust of quartz conglomerates in the finishing departments. In all subjects, we registered occupational history, respiratory symptoms (especially dyspnea measured by the modified Medical Research Council scale), spirom-

etry, carbon monoxide lung diffusion (DLco) and chest X-ray (classified according to ILO classification) (8). In subjects with abnormal spirometry or DLco or chest X-ray, chest HRCT was performed and classified according to International Classification of HRCT for Occupational and Environmental Respiratory Diseases (7). In subjects with radiological signs indicative of silicosis, trans-bronchial biopsies were taken for histological evaluation and identification of silica crystals in the tissues, using phase contrast polarizing light microscopy and scanning electron microscopy and energy dispersive spectroscopy. The diagnosis of silicosis was based on the relevant cumulative exposure to silica dust and chest HRCT characteristic findings.

Silica dust measurements

Levels of airborne crystalline silica during activity in the finishing departments were assessed by X-ray diffractometric analysis carried out on respirable dust according to NIOSH 7500:2003 method. Individual cumulative exposure was then calculated by multiplying the time weighted average level of airborne silica dust for the years of exposure.

Lung Function

Spirometry and lung diffusing capacity were performed according to the recommendations of ATS/ERS (10). Vital Capacity (VC), Forced Expiratory Volume at the first second (FEV₁), Residual Volume (RV) and Total Lung Capacity (TLC) were measured with a spirometer (ESS system; Biomedin, Padova, Italy). The predicted normal values of the Communauté Européenne du Charbon et de l'Acier (CECA) were used (1). Diffusing capacity of the lung was measured by using single-breath carbon monoxide (CO) uptake (ESS system; Biomedin). The predicted normal values of Cotes et al. were used (2).

RESULTS

We recruited 45 subjects, working in the finishing departments of eleven ornamental stone companies; eight of them were family/artisan companies

and 3 bigger factories with at least 200 employees. Their duties consisted of dry cutting and polishing kitchen countertops in most companies; wet finishing was also organized in two big companies. In all companies the finishing departments had exhaust ventilation on the wall. In general, quartz conglomerates had been extensively used since 2008. The data of the industrial surveys carried out until 2016 and provided by the companies showed similar levels of airborne crystalline silica during activity in the finishing lines. The 8-hour weighted average values were in the range 0.260-0.744 mg/m³. Subsequently the exposure levels decreased at less than 0.1 mg/m³ because of the preventive measures introduced (extension of wet finishing, increasing of exhaust ventilation, use of PPE). The work shift was about 8 hours and, in some companies, longer (from 9 to 10 hours).

A diagnosis of silicosis was made in twenty-four cases (Silicosis+ group), while the investigations led to exclude this disease in the remaining workers (Silicosis- group). The cases of silicosis came from 7 out of the 11 factories. The characteristics of the two groups are shown in Table 1. All subjects were men with mean age at diagnosis of 43 years in Silicosis+

Table 1 - Characteristics of subjects and their work exposure history

Tabella 1 - Caratteristiche dei soggetti e la loro anamnesi lavorativa

Parameters*	Silicosis+ (No.= 24)	Silicosis- (No.= 21)
Age at diagnosis (y)	43 (25-57)	45 (33-54)
BMI	26 (21-34)	29 (25-34)
Respiratory symptoms (No.; %)	7 (29%)	7 (33%)
Duration of exposure to quartz conglomerates (y)	9.4 (3.5-20)	11.6 (8-15)
Smoking history (yes/no/ former) (No.)	9/7/9	11/5/5
Previous exposure to natural stones (No.; %)	13 (54%)	16 (76%)
Accelerated silicosis (No.; %)	18 (75)	-
Silica cumulative dose (mg/m ³ /y)	4.3 (1.7-5.4)	2.2** (0.1-5.4)

* Data are represented as number (%) or mean (range),

** Wilcoxon Signed Rank test p= 0.046

group and 45 years Silicosis- group. Duration of exposure to quartz conglomerate dust was similar in the two groups (mean 9.4 vs 11.6 y, respectively), and ranged from 3.5 to 20 years in Silicosis+ group. The silica cumulative exposure was significantly higher in Silicosis+ group than in Silicosis- group (4.3 vs 2.2 mg/m³/y, p=0.046). Accelerated silicosis was diagnosed according to NIOSH 2002 classification (duration of exposure to silica dust between 5 and 10 years) and was evaluated in 75% of the cases (12). The duration of exposure and the cumulative exposure to silica dusts were on average 13.2 years and 2.2 mg/m³/y respectively in chronic silicosis compared to 8.6 years and 3.6 mg/m³/y in accelerated silicosis. Inadequate collective prevention measures were reported in 75% of Silicosis+ group cases and in 33% of Silicosis- group. Seventy nine percent of silicosis cases did not use personal protective equipment (PPE) in comparison to 45% in Silicosis- group.

All 45 workers followed a Health Surveillance Programs based on annual medical examination and spirometry. In Silicosis+ group, a chest X-ray was performed every three years in 14% of cases, only at first examination in 25% of cases, and it had never been performed in the remaining cases. In Silicosis- group, a chest X-ray was taken every three years in 50% of cases, in the remaining workers it was made at first observation.

In Silicosis+ group, more than two thirds of the subjects were asymptomatic and had a normal physical examination of the chest. Seven subjects reported dyspnea on exertion (MRC scale I), and also cough in two cases, while none of them had chronic bronchitis. One third of Silicosis- group subjects were symptomatic, with cough predominantly (Table 1).

Figure 1 shows the percentages of abnormal lung parameters (defined values below the lower limit of normality for VC, FEV1/CV, TLC, DLco or above higher for RV) in subjects with and without silicosis. In Silicosis+ group the most common alteration was a restrictive pattern based on TLC and an impairment of DLco. In contrast, in Silicosis- group the predominant alteration was an obstructive pattern.

Chest X-ray were abnormal in 9 subjects of Silicosis+ group and in 4 of Silicosis- group. Small round p and irregular s/t opacities according to ILO classification were prevalently detected in chest X-ray of Silicosis+ group (p 26%, q 10%, r 0%; s/t 6% respectively). Although in Silicosis- group some small round opacities were observed (p 12%, q 4%, r 1%), the subsequent evaluation with HRCT excluded the presence of silicosis.

Figure 2 shows representative radiological findings in a 33-year-old worker with accelerated silicosis. Chest HRCT was performed in all 45 subjects and was indicative of silicosis in 24 cases. In the 21

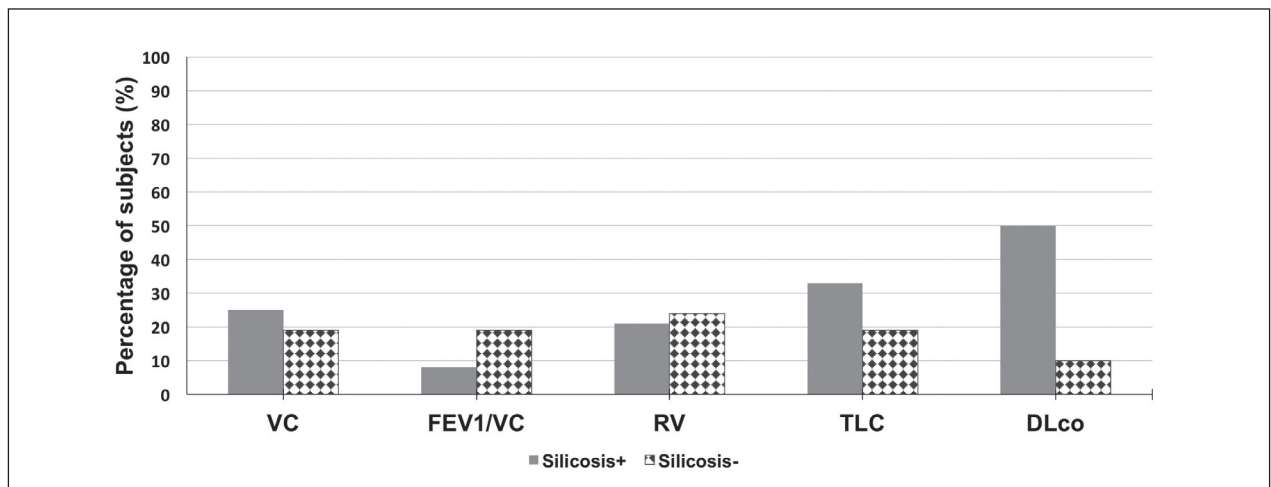


Figure 1 - Percentages of subjects with silicosis (Silicosis+, No.= 24) and without silicosis (Silicosis-, No.= 21) with abnormal lung function parameters.

Figura 1 - Percentuale di soggetti con silicosi (silicosi+, n = 24) e senza silicosi (silicosi-, n = 21) con parametri di funzionalità respiratoria alterati

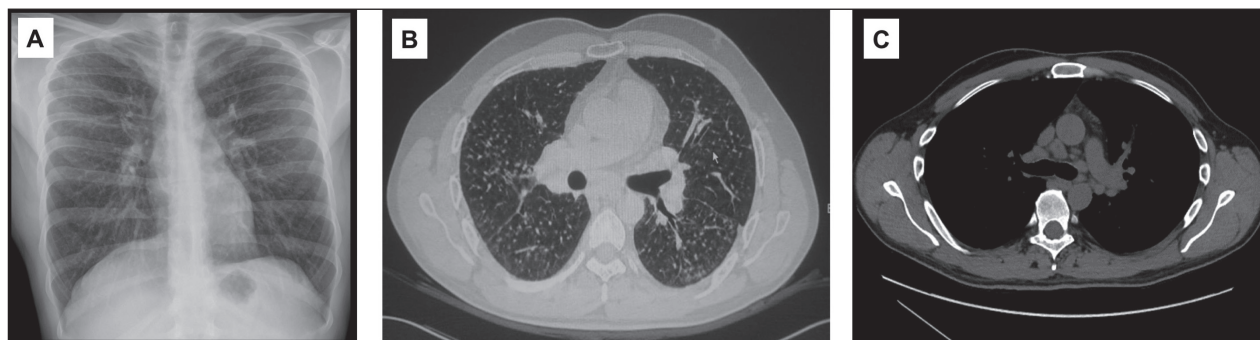


Figure 2 - Radiological findings of a worker with silicosis. A. Chest X-ray: diffuse bilateral interstitial micronodular pattern. ILO: p/q, profusion 2/2; B. Chest HRCT ICOERD: prevalent well-defined rounded grade 2 opacities, predominantly size p, profusion 14 and irregular/linear opacities, grade 2 and predominantly intralobular; C. Chest HRCT: multiple bilateral enlarged hilar lymph nodes

Figura 2 - *Reperti radiologici di un lavoratore con silicosi. A. Radiografia del torace: interstiziopatia micronodulare bilaterale diffusa. ILO: p/q, profusione 2/2; B. HRCT torace ICOERD: opacità prevalenti arrotondate ben definite di grado 2, prevalentemente dimensione p, profusione 14 e opacità irregolari/lineari, grado 2 e prevalentemente intralobulari; C. Torace HRCT: linfonodi ilari allargati bilaterali multipli*

subjects of Silicosis- group, solitary nodules were detected in 3 cases, slight emphysema signs in 6 cases, and normal HRCT in the remaining cases. The chest HRCT of Silicosis+ group showed predominant well-defined rounded opacities (size p) and irregular/linear intra-lobular opacities (Table 2). The mean grade of profusion was 15 for round and 12 for irregular small opacities. In addition, HRCTs detected large opacities in 44% of silicotic cases. In 5 subjects, a progressive massive fibrosis (PMF) was diagnosed at presentation. Furthermore, frequent sub-pleural involvement was observed, lymph nodes were more often numerous than enlarged, and generally slightly iperdense. In addition, HRCTs detected a high prevalence of “ground glass pattern” (80%) with significant profusion and inhomogeneous attenuation was present in 72% of cases. These abnormalities are related to decreased air in the airspaces and lumen of airways and to increased soft tissue structures. Lung biopsies were performed in twenty silicotic subjects. Histological findings consistent with silicosis were observed in all cases and numerous particles of crystalline silica (diameter 0.1-5 μm) were identified in lung tissue by optical and electron microscopy analyses.

DISCUSSION

This study reports an unexpected high incidence of silicosis in Italian workers exposed to quartz con-

glomerates dust with a high silica content. We detected mainly cases of accelerated silicosis in young workers often with few respiratory symptoms and normal lung functions, but in advanced disease stage. Indeed, five subjects had a radiographic features indicative of progressive massive fibrosis.

In Italy, silicosis incidence has been declining over the last years. Data reported by the Italian National Assurance Institute for Occupational Disease showed a gradual decrease of claims for silicosis from 2014 (240 cases) to 2017 (140 cases). However, we expect a slowdown of this decrease or perhaps even an increase of cases, due to the contribution of the present 24 cases and of those that might be detected in the coming years, considering that quartz conglomerates are increasingly used in Italian specialized companies and our investigation has promoted an alert in occupational and respiratory physicians.

In the studied companies, the almost prevalent use of quartz conglomerates for countertops has occurred since 2008. The average silica content of this material is 85-90%, but there are also resins and pigments. Therefore, the possibility that different components may increase the toxicity of the dust in this process should be considered. In addition, freshly fractured silica, generated during abrasive blasting, may exhibit increased toxicity than aged silica, due to the elevated redox potential of crystal surface (9). Crystallinity, until now considered to be responsi-

Table 2 - Prevalence of abnormalities, different from small opacities, detected in chest HRCT, classified according to ICOERD, in subjects with silicosis (No.= 24)

Tabella 2 - Prevalenza di anomalie, diverse dalle piccole opacità, rilevata nella HRCT toracica, classificata secondo ICOERD, in soggetti con silicosi (n = 24)

Variables	Prevalence (%)
Small opacities	
Round	
P	84
Q	16
R	0
Grade of profusion (score)	
0-6	0
7-12	31
13-18	69
Irregular	
Intralobular	92
Interlobular	8
Grade of profusion (score)	
0-6	13
7-12	37
13-18	50
<i>Ground glass pattern</i>	80
Grade of profusion (mean No.; range)	15 (2-18)
Large opacities	
A	13
B	25
C	6
<i>Lymphadenopathies (diameter>1cm)</i>	28
<i>Emphysema</i>	40
<i>Inhomogenous attenuation</i>	72
<i>Subpleural nodes</i>	68

ble for the adverse effects of silica, does not seem *per se* related to toxicity. Instead, the chemical characteristics (for example silanols and siloxanes) and the surface configuration of the silica would be the trigger of toxic responses (16, 23). It has also been demonstrated that the dust originated by quartz conglomerates had a wide variability. Di Benedetto F et al. showed that dry polishing of artificial stones induces a contamination determined by the working-tools composition (special steels), while the wet processed materials include several elements com-

patible with the ion content of the water, especially calcium (3). The authors also observed a persistence of the resin after the processing. They suggested that the resin, by coating the respirable crystalline silica particles, can protect surface radicals for a certain time during interaction with the lung lining fluid. This mechanism could then determine the greater toxicity of the artificial stones dusts compared to the natural stones, whose uncoated radicals can be readily neutralized in the airspaces before reaching the lung.

No data on workplace dust levels were available from most of the previous studies on quartz conglomerates processing (5, 6, 11, 13, 17-22) except the case report of Paolucci et al. and our previous study (4, 15). The data in the finishing department showed an average crystalline silica concentration 10 to 30 times higher than the threshold limit value proposed by ACGIH (or 5-15 times higher than SCOEL limits). These levels of exposure to silica are similar to those measured in the workplace of the workers of this study. We have succeeded in quantifying the cumulative silica exposure in the study subjects and such high levels seem to reasonably explain the high incidence of silicosis, especially of the accelerated type. Although Silicosis+ group exhibited higher silica cumulative exposure than Silicosis-group, we observed an overlap of exposure to silica dust among the subjects with silicosis and without silicosis. Therefore, other factors in addition to the high level of silica dust exposure must be implicated in the development of silicosis, including different ways of performing the tasks among workers, wearing PPE or different individual susceptibility to developing the disease. In a 29-year cohort study performed in automobile foundry workers, Zhang M. et al. (24) showed a relationship between cumulative exposure and silicosis incidence. The risk of silicosis increased by 4.38 folds with an increase of 1 mg/m³/y of cumulative exposure to silica. The predicted incidence of silicosis for 50-y-old granite workers with cumulative exposure to respirable quartz dust of approximately 2 mg/m³/y was 6% (14). Higher incidences were calculated by the National Institute for Occupational Safety and Health (NIOSH 2002) for gold miners, ranging from 10 to 13% for cumulative exposure to silica of 2.25 mg/m³/y and

from 47 to 70% for exposures to 4.5 mg/m³/y (12). Whereas NIOSH modeled the cumulative exposure over a 45-y working lifetime, the present population exhibited similar cumulative exposure with only 10 years duration of work with quartz conglomerates. The strong exposure levels over a relative short working time, can explain the high percentage of accelerated silicosis in this cohort. This is in agreement with what was highlighted by Hoy RF et al. (5) in Australia, even if the number of cases they described was smaller (7 cases). Our findings differ from those reported in Spanish workers by Pérez-Alonso A et al. (17) and Martínez González C et al. (11), where the percentages of accelerated silicosis were respectively 26% and 10%. The discrepancy may be explained not only by different silica exposure levels, but also by the fact that our cases have been identified through an active search related to health surveillance program. However, our findings must be taken with caution given the cross-sectional nature of the investigation.

We showed that respiratory symptoms have low sensitivity and specificity, in fact they were present in both groups with and without silicosis in similar percentages. Also Spirometry test results had low sensitivity and specificity, while a reduction in DLco was the most frequent functional abnormality in subjects with silicosis. Therefore, DLco seemed to be more sensitive and specific than spirometry. Chest X-ray exhibited low sensitivity and specificity too. The most sensitive diagnostic tool for the detection of silicosis was the chest HRCT. Moreover, chest HRCT allowed to highlight other abnormalities in addition to rounded opacities, such as the presence of ground glass patterns with moderate grade of profusion and in-homogenous attenuation.

The silicotic cases we examined seemed to have histological and radiological features similar to those recently described by Martínez González C et al. (11). Moreover, the detection of silica particles in lung transbronchial biopsy of 20 cases helped us to make a confident diagnosis of silicosis and to exclude sarcoidosis.

We observed that the occupational risk has been underestimated, and in some circumstances probably disregarded. Personal and collective preventive interventions were not present or not sufficiently

effective and Health Surveillance Programs were inadequate in most cases. These evidences emphasize the relevance of a strict environmental control of exposure to crystalline silica and targeted health surveillance programs in these workers.

CONCLUSIONS

We reported an unexpected high incidence of silicosis in Italian workers exposed to quartz conglomerates dust with a high silica content. We observed an overlap of cumulative exposure to silica dust between the cases with silicosis and without silicosis. This finding could depend on the different ways of performing tasks and use of personal protective device among workers, or on the different individual susceptibility to develop the disease. Respiratory symptoms, spirometry and chest X-ray did not result sufficiently sensitive. Instead, chest HRCT was the most sensitive diagnostic tool for the detection of silicosis, while reduction of DLco was the most frequent functional abnormality in the affected subjects. The results suggest that DLco should be added to spirometry for health surveillance and chest HRCT is indicated for screening of workers with high cumulative exposure to silica. General practitioners and physicians should have a heightened awareness of this newly described occupational hazard. In addition, a more rigorous application of safety regulations and more effective preventive interventions at work are extremely necessary to prevent future adverse events related to the fabrication of quartz conglomerates.

NO POTENTIAL CONFLICT OF INTEREST RELEVANT TO THIS ARTICLE WAS REPORTED BY THE AUTHORS

References

1. Commission Des Communautés Européennes (CECA). Table de Reference pour les Examens Spirometriques. Luxembourg; Office des Publications Officielles des Communautés Européennes; 1971
2. Cotes JE, Chinn DJ, Quanjer PH, et al: Standardization of the measurement of transfer factor (diffusing capacity). *Eur Respir J* 1993; 6 Suppl 16: 41-52
3. Di Benedetto F, Giaccherini A, Montegrossi G, et al:

- Chemical variability of artificial stone powders in relation to their health effects. *Sci Rep* 2019; 9: 6531
4. Guarnieri G, Bizzotto R, Gottardo O, et al: Multiorgan accelerated silicosis misdiagnosed as sarcoidosis in two workers exposed to quartz conglomerate dust. *Occup Environ Med* 2019; 76: 178-180
 5. Hoy RF, Baird T, Hammerschlag G, et al: Artificial stone-associated silicosis: a rapidly emerging occupational lung disease. *Occup Environ Med* 2018; 75: 3-5
 6. Kramer MR, Blanc PD, Fireman E, et al: Artificial stone silicosis [corrected]: disease resurgence among artificial stone workers. *Chest* 2012; 142: 419-424
 7. Kusaka Y, Hering K, Parker J: *International Classification of HRCT for Occupational and Environmental Respiratory Diseases*, Springer-Verlag, Tokyo, 2005
 8. International Labour Office: *Guidelines for the use of the ILO International Classification of Radiographs of Pneumoconioses*, Revised edition 2011. Occupational Safety and Health Series No. 22. Office, Geneva 2011
 9. Leung CC, Yu ITS, Chen W. Silicosis. *The Lancet* 2012; 379: 2008-2018
 10. Macintyre N, Crapo RO, Viegi G, et al: Standardisation of the single-breath determination of carbon monoxide uptake in the lung. *Eur Respir J* 2005 ; 26: 720-735
 11. Martínez González C, Prieto González A, García Alfonso L, et al: Silicosis in Artificial Quartz Conglomerate Workers. *Arch Bronconeumol.* 2019; 55: 459-464
 12. National Institute for Occupational Safety and Health. *Health Effects of Occupational Exposure to Respirable Crystalline Silica*. DHHS (NIOSH) Publication No. 2002-129: April 2002
 13. Newbiggin K, Parsons R, Deller D, et al: Stonemasons with silicosis: Preliminary findings and a warning message from Australia. *Respirology.* 2019 Aug 12. doi: 10.1111/resp.13672. 11
 14. Ng TP, Chan SL: Quantitative relations between silica exposure and development of radiological small opacities in granite workers. *Ann Occup Hyg* 1994; 38(Suppl 1): 857-863
 15. Paolucci V, Romeo R, Sisinni AG, et al: Silicosis in workers exposed to artificial quartz conglomerates: does it differ from chronic simple silicosis? *Arch Bronconeumol* 2015; 51: e57-60
 16. Pavan C, Delle Piane M, Gullo M, et al: The puzzling issue of silica toxicity: are silanols bridging the gaps between surface states and pathogenicity? *Part Fibre Toxicol.* 2019; 16: 32
 17. Pérez-Alonso A, Córdoba-Doña JA, Millares-Lorenzo JL, et al: Outbreak of silicosis in Spanish quartz conglomerate workers. *Int J Occup Environ Health* 2014; 20: 26-32
 18. Pérez-Alonso A, Córdoba-Doña JA, León-Jiménez A: Silicosis Caused by Artificial Quartz Conglomerates: Keys to Controlling an Emerging Disease. *Arch Bronconeumol.* 2019; 55: 394-395
 19. Rose C, Heinzerling A, Patel K, et al: Severe Silicosis in Engineered Stone Fabrication Workers - California, Colorado, Texas, and Washington, 2017-2019. *MMWR Morb Mortal Wkly Rep* 2019; 68: 813-818
 20. Rosengarten D, Fox BD, Fireman E, et al: Survival following lung transplantation for artificial stone silicosis relative to idiopathic pulmonary fibrosis. *Am J Ind Med* 2017; 60: 248-254
 21. Ronsmans S, Decoster L, Keirsbilck S, et al: Artificial stone-associated silicosis in Belgium. *Occup Environ Med* 2019; 76: 133-134
 22. Seneviratne M, Shankar K, Cantrell P, et al: Respirable crystalline exposure (rCs); Monitoring, Health surveillance and hazard communication among stone workers. *Occup Environ Med* 2018; 75: A441
 23. Turci F, Pavan C, Leinardi R, et al: Revisiting the paradigm of silica pathogenicity with synthetic quartz crystals: the role of crystallinity and surface disorder. *Part Fibre Toxicol.* 2016; 13: 32
 24. Zhang M, Zheng YD, Du XY, et al: Silicosis in automobile foundry workers: a 29-year cohort study. *Biomed Environ Sci* 2010; 23: 121-129