

Clinical-histological and immunohistochemical comparisons of vitiligo skin before and after a complex treatment using cell technologies

Vladimir Tsepko¹, Kateryna Karpenko²

¹MD, Professor of the Shupyk National Healthcare University of Ukraine, Department of Dermatovenereology, Allergology, Clinical and Laboratory Immunology, Kyiv, Ukraine; dermatovenerologist, Ukrainian Institute of Plastic Surgery and Cosmetology «Virtus» Sudostroitel'naya 1a, Odessa, Ukraine; ²MD, graduate student of the Shupyk National Healthcare University of Ukraine; Department of Dermatovenereology, Allergology, Clinical and Laboratory Immunology, Kyiv, Ukraine; dermatovenerologist, Ukrainian Institute of Plastic Surgery and Cosmetology «Virtus» Sudostroitel'naya 1a, Odessa, Ukraine

Abstract. *Background:* Vitiligo is an idiopathic disease characterized by the presence of depigmented patches as a result of a progressive melanocyte loss. Vitiligo is a significant psychological and social problem that can lead to a serious impairment of the patient's quality of life. To develop a comprehensive treatment method, we conducted clinical, immunological, and biochemical studies. The developed treatment method involved traditional therapy and UVB phototherapy, as well as cell technology methods such as melanocyte-keratinocyte suspension (MKS) and automezozoconcentrate (AMC). The objective of the study was to analyze the histological and immune-histochemical changes in the affected skin of vitiligo patients before and after the treatment and identify any differences based on gender. *Methods:* An open comparative randomized clinical trial included 107 patients with ages 19–65, consisting of 45 men and 62 women. Morphological, immunohistochemical, and morphometric studies were performed on the affected skin. The patients were divided into two groups: the main group (56 patients) received a treatment according to the developed method, and the comparison group (51 patients) received the traditional treatment. *Results:* The use of MKS and AMC in the treatment of vitiligo resulted in a decrease in the severity of epidermal dystrophic changes, recovery of melanocytes, and the reduction of dermal inflammatory infiltrate, as well as positive clinical results. *Conclusions:* The comparative analysis of histological changes before and after the treatment showed that the use of MKS and AMC significantly expanded the possibilities and increased the effectiveness of vitiligo treatment strategies.

Key words: vitiligo, melanocytes, keratinocytes, immunohistochemistry, phototherapy, epidermis

Introduction

Vitiligo is a chronic skin condition that falls under the category of dyschromias, characterized by white depigmented patches of varying sizes and shapes. Its prevalence is estimated to be between 1 and 4%, but these numbers may not accurately represent its true incidence as they are based on treatment in dermatological centers rather than preventative surveys. There has

been a recent increase in both adult and child patients with vitiligo¹⁻³.

The condition affects individuals from diverse ethnic groups and regions, and its impact on the patients' psychosocial well-being and the lack of effective treatments highlight the need for new therapies.

Treatment protocols for vitiligo consider factors such as the severity, location of the patches, activity of dermatosis⁴⁻⁶. Traditional therapies include vitamin

therapy, hyposensitizers, hepatoprotectors, and in severe cases, systemic corticosteroid hormones, topical steroids, and calcineurin inhibitors⁶. Phototherapy is commonly used, including psoralen and UVA and narrowband UVB 311nm, although it is not always effective. The Long-term use of UVB phototherapy shows that only half of the patients can achieve a 75% repigmentation^{5,6}.

Considering the torpidity of vitiligo in response to traditional therapy, in the last decade the treatment of patients frequently involved widely used regenerative technologies of tissue grafting (epidermal blister grafting, punch grafting of the entire thickness of the skin, thin dermoepidermal split-grafts, follicular grafting) or cell grafting (cultured or non-cultured suspensions of melanocytes and keratinocytes)^{6,7}.

The results of clinical-instrumental, immunological and biochemical studies served as a basis for the development of a comprehensive method of treatment of vitiligo patients using, along with traditional therapy and UVB 311nm phototherapy, methods of cell technology - melanocyte-keratinocyte suspension (MKS) and automezoconcentrate (AMC)⁸.

In combination with UVB 311 nm phototherapy have shown significant results with reduced numbers of injected cells, making the treatment more financially feasible for a widespread implementation⁹⁻¹¹.

The aim of this study is to analyze the histological and immune-histochemical alterations in the impacted skin of patients affected with vitiligo in therapeutic cohorts, both before and after treatment, and to ascertain any gender-related characteristics.

Materials and methods. During our open comparative randomized clinical trial, we observed a total of 107 patients with vitiligo, with ages ranging from 19 to 65 and classified as Fitzpatrick phototypes I-IV. Of these patients, 45 (42.06%) were male and 62 (57.94%) were female. According to generally accepted recommendations¹, we categorized the patients in two forms of vitiligo: focal, observed in 29 (27.1%) patients, and generalized, observed in 78 (72.9%) patients. We also classified the patients into three stages based on the disease's activity: progressive, stable and in the stage of repigmentation. At the time of inclusion in the study, most of our patients were at the stable stage (98; 91.6%), whereas 9 (8.4%) patients in the stage of repi-

gmentation. Prior to participating in the study, all the patients signed an Informed Consent. Approval was obtained on the 23.12.2019 from the local ethics committee Shupyk National Healthcare University.

The treatment plan for vitiligo patients consisted of two stages. During the first stage, we addressed any detected endocrine and/or somatic pathology. The second stage involved both the traditional dermatological treatment and the treatment relying on the developed method.

We carried out the dermatological traditional therapy for patients in accordance to generally accepted methods⁴. This included the use of hepatoprotectors, vitamins, antioxidants, UVB phototherapy and topical anti-inflammatory therapy.

UVB phototherapy was administered using a 3 Series device (Daavlin, USA) with a specific phototherapy regimen. The starting dose was 70% of the minimum erythema dose (MED), and the subsequent dose ranged from 100 to 400 mJ/cm², depending on the patient's skin phototype. The step increase was 50 mJ/cm², and patients underwent three procedures per week for a total course of 30-35 procedures. The total course dose ranged from 25000 mJ/cm² to 35000 mJ/cm², depending on the patient's skin phototype. Topically, we used calcineurin inhibitors (0.1% tacrolimus ointment), which patients applied daily in the evening for a month. Afterwards, patients continued a more proactive therapy, applying the ointment once a day in the evening, 2 times a week for up to 6-8 months.

Our developed method of MKS administration involved several steps (Figure 1). Firstly, we induced the pigmentation of the autologous donor skin using UVB 311 nm, with 5-7 sessions a day, starting at 70% MED and increasing the dose of each session by 20%. Next, we performed a punch biopsy (3-5 mm in diameter) on the donor skin under local infiltration anesthesia (2% lidocaine after the previous test). The biopsy was then sent to the biotechnology laboratory to cultivate and manufacture an individualized melanocyte-keratinocyte suspension - MKS. Afterward, we injected the MKS into the skin, at a rate of 1 million cells per 1 cm² of depigmented areas of skin (in vitiligo areas) that were previously anesthetized with "Emla" cream. Starting from the second day after the introduction of the MKS, patients underwent UVB 311 nm phototherapy every other day, with an increase

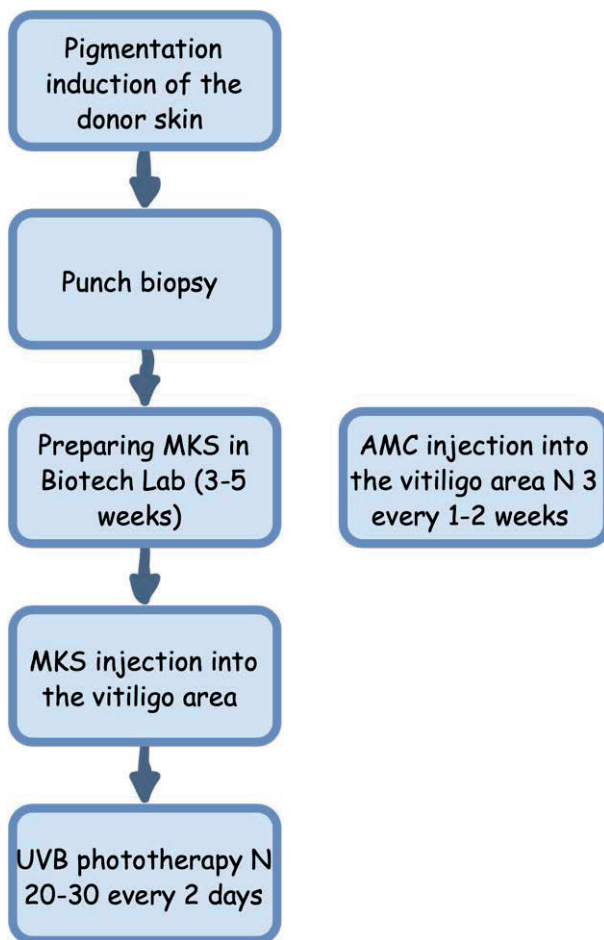


Figure 1 - Developed method of vitiligo treatment with the use of MKS and AMC.

in the dose of each subsequent procedure by 20%, for an overall course of 20-30 procedures.

AMC injections are carried out before the MKS injections in the same vitiligo areas. To administer AMC, we followed a specific method. Firstly, we mixed the patient's blood with an anticoagulant (sodium citrate or glucose citrate) at a ratio of 9:1 and centrifuged it twice. After the first centrifugation, we separated the plasma from erythrocytes and leukocytes. After the second centrifugation, we removed the precipitate of the platelet pool from the platelet-poor plasma, filtered it, and collected it in test-tubes containing growth factors when it reached about 1×10^9 platelets/ml. Before use, we defrosted the lysate product at 37°C , centrifuged it for the first time at 2500 turns/min for 10 minutes, removed the precipitated fibrin, and centrifuged it for the second time at 3200

turns/min for 3 minutes. We then resuspended the concentrate of growth factors in a buffer solution and injected it subcutaneously into the vitiligo area (using application anesthesia) once every 1-2 weeks. The density of injections was 1.5-5 mm, and the procedure was performed three times¹¹.

To compare the effectiveness of the developed method with the traditional treatment, patients were randomly divided into two representative groups based on the goals and objectives of the study. The main group consisted of 56 patients who received the developed method treatment whereas the comparison group consisted of 51 patients who received the traditional treatment.

For morphological, immunohistochemical (IHC), and morphometric studies, all patients underwent 3.5 mm punch biopsies of the vitiligo area, in compliance with ethical standards, followed by a histological examination.

Punch biopsies were fixed in 10% buffered formalin and embedded in paraffin. On the precision rotary microtome HM 3600 ("MICROM Laborgerate GmbH" - Germany), we made serial standard sections with a thickness of 4 microns. These sections were placed on ordinary slides to review pathohistological staining or on adhesive slides "SUPER FROST PLUS" by the company "DAKO" (Denmark) for immunohistochemical studies.

We determined the general pathological changes in the skin, as well as the presence of inflammatory infiltrate in the dermis, by examining micropreparations stained with hematoxylin and eosin. We used a microscope ERMA Inc. (Model: EZ 122, Japan) at magnifications of x10 and x40 for this purpose.

We performed IHC studies in paraffin sections using monoclonal and polyclonal antibodies. We evaluated the results of the IHC reaction under the microscope ERMA Inc. (Model: EZ 122, Japan) and documented them using the digital camera Camedia C5060WZ by Olympus, Japan.

Our immunohistochemical study included the determination of CD3 (DAKO, polyclonal), CD4 (DAKO, clone 4B12), CD8 (DAKO, clone C8 / 144B), S100 (DAKO, polyclonal), and Melan A (DAKO, clone A103). We conducted these studies before treatment and 16 weeks after.

We performed a statistical analysis using the R programming language (version R-3.6.3 for Windows, under the GNU General Public License). We presented the data as the number (n) and percentage (%) of patients. To analyze the qualitative data, we used Fisher's exact test. The significance level for all tests was set at 0.05.

Results

Morphological, immunohistochemical, and morphometric studies were conducted on skin affected by vitiligo in 107 patients.

Prior to the treatment, the skin in all the samples exhibited typical characteristics.

Hyperkeratosis of varying degrees was observed in 58 (54.2%) cases, consisting of 24 (53.3%) men and 34 (54.8%) women. Orthokeratosis was observed in 49 (45.8%) patients, including 21 (46.7%) men and 28 (45.2%) women. Focal hypergranulosis was detected in 36 (33.6%) cases, including 16 (35.5%) men and 20 (32.3%) women. Mild acanthosis of the epidermis was observed in 31 (29%) biopsies, including 12 (26.7%) men and 19 (30.6%) women. Epidermal spongiosis was observed in 95 (88.8%) patients, including 39 (86.7%) men and 56 (90.3%) women, mainly manifesting as vacuolar degeneration of basal keratinocytes. An Intact epidermis was present in 39 (36.4%) cases,

including 17 (37.8%) men and 22 (35.5%) women. However, there were no significant gender differences in hyperkeratosis ($p = 1$), granulosis ($p = 0.836$), acanthosis ($p = 0.673$), and spongiosis ($p = 0.554$).

The dermo-epidermal border was preserved in all the samples. In the underlying dermis, an increase in the number of microcirculatory vessels was observed in 52 (48.6%) patients, with no significant difference between men and women. Weak or poorly defined perivascular lymphocytic infiltrates were present in all the examined samples (*Table 1*).

In terms of gender differences, a higher percentage of women showed spongiosis (90.3%) and moderate lymphocytic infiltrate (37.1%) compared to men (86.7% and 33.3%, respectively). However, there was no significant difference in the number of microcirculatory vessels ($p = 0.845$) or the incidence of lymphocytic infiltrate ($p = 0.838$) between men and women.

CD3 staining showed only a few perivascular T-lymphocytes with a positive reaction, and similar areas showed positive reactions for CD4 and CD8 T-lymphocytes, with $CD4 > CD8$. CD3 staining showed positive reactions in almost all lymphocytes of the dermal infiltrate. CD4 staining showed positive responses in most infiltrate lymphocytes, while CD8 staining showed positive responses in only a few cells of the dermal infiltrate.

S100 staining showed positive reactions in Langerhans cells located in the perivascular infiltrate

Table 1 - Histological parameters in vitiligo patients in the study group.

Parameter	All patients (n=107)		Men (n=45)		Women (n=62)		p-value
	abs.	%	abs.	%	abs.	%	
Hyperkeratosis	58	54,2	24	53,3	34	54,8	1
Granulosis	36	33,6	16	35,5	20	32,3	0,836
Acanthosis	31	29,0	12	26,7	19	30,6	0,673
Spongiosis	95	88,8	39	86,7	56	90,3	0,554
Enlargement of the vessels of the dermis microcirculatory tract	52	48,6	21	46,7	31	50,0	0,845
Lymphocytic infiltrate							0,838
· absent	0	0	0	0	0	0	
· weakly expressed	69	64,5	30	66,7	39	62,9	
· moderate expressed	38	35,5	15	33,3	23	37,1	
· sharply expressed	0	0	0	0	0	0	

Table 2 - Immunohistochemical parameters in vitiligo patients in the study group

Parameter	All patients (n=107)		Men (n=45)		Women (n=62)		p-value
	abs.	%	abs.	%	abs.	%	
CD3 (DAKO, polyclonal)	102	95,3	43	95,6	59	95,2	1
CD4 (DAKO, clone 4B12)	87	81,3	36	80,0	51	82,3	0,805
CD8 (DAKO, clone C8 / 144B)	69	64,5	28	62,2	41	66,1	0,688
S100 (DAKO, polyclonal)	34	31,8	13	28,9	21	33,9	0,676
Melan A (DAKO, clone A103)	0	0	0	0	0	0	0

of the dermis and in single cells of subcutaneous fat infiltrate, but no similar cells were found in the epidermis. Melanocytes were not detected in any of the 107 vitiligo patient samples during routine hematoxylin-eosin staining. Melan-A staining revealed the complete absence of melanocytes in the basal layer of the epidermis in all observations, including both men (n=45) and women (n=62). Dendritic cells in the dermis showed a positive reaction to S100 staining in 34 (31.8%) patients, including 13 (28.9%) men and 21 (33.9%) women (Table 2).

During a gender-specific immunohistochemical analysis, it was observed that the CD3 positive reaction did not differ significantly between men and women. The CD4 positive response was found in 36 (80.0%) men and 51 (82.3%) women. The CD8 positive response was more prevalent in women with 41 cases (66.1%) compared to men with 28 (62.2%). A similar trend was observed in S100 staining, which was found in 21 (33.9%) women and only 13 (28.9%) men. However, no significant gender differences were found in the amounts of CD3 ($p = 1$), CD4 ($p = 0.805$), CD8 ($p = 0.688$), and S100 ($p = 0.676$) between men and women.

The results of these complex histological and immunohistochemical studies indicate that patients with vitiligo display mild epidermal changes such as hyperkeratosis, acanthosis, and focal granulosis, whereas dermal changes include moderate vascular reactions and an increased number of vessels in the microcirculatory tract, as well as focal lymphocytic infiltrates mainly around the blood vessels. The infiltrates were characterized by a significant number of CD3 cells, with a predominance of CD4 cells over CD8 cells. Gender differences were observed, but they were not significant.

The absence of melanocytes in the epidermis and

the presence of single Langerhans cells in the dermal infiltrate were detected in all cases of vitiligo using specific staining (Melan A, S100). This highlights the main feature of vitiligo. Additionally, the disturbance in the CD4/CD8 ratio in the perivascular dermal infiltrate reflects the importance of immunological disorders in the development of vitiligo.

Changes in the epidermis were observed after 16 weeks of therapy, even with hematoxylin-eosin staining. Hyperkeratosis decreased from 58 (54.2%) to 32 (29.9%), granulosis decreased from 36 (33.6%) to 22 (20.6%), and acanthosis decreased from 31 (29%) to 18 (16.8%). Notably, spongiosis changes were particularly significant, decreasing from 95 (88.8%) patients before treatment to 33 (30.8%) patients after treatment.

Similarly, the assessment of dermal microcirculatory vessels showed pronounced changes. The number of patients with increased vessels decreased from 52 (48.6%) to 27 (25.2%) after treatment.

The number of patients with severe dermal lymphocytic infiltrate decreased from 38 (35.5%) to 19 (16.8%), and mild infiltrate decreased from 69 (64.5%) to 39 (36.4%) after treatment. Additionally, 49 (45.8%) patients showed no dermal lymphocytic infiltrate after treatment, whereas before the treatment, all the patients had some degree of infiltrate (Figures 2, 3).

The most significant changes observed in this study were detected through immunohistochemical reactions. Staining with S100 (DAKO, polyclonal) showed a positive reaction in all dendritic cells in both the dermis and epidermis, while Melan A staining (DAKO, clone A103) showed a negative reaction. CD3 staining revealed a positive reaction in perivascular T-lymphocytes, a positive reaction for CD4 and CD8 T-lymphocytes, with CD4 > CD8.

Comparing immunohistochemical parameters in vitiligo patients before and after the treatment, there was a significant decrease in the number of patients showing a positive response to CD3 cells - from 102 (95.3%) to 81 (75.7%) patients, respectively.

A similar trend was observed in the detection of CD4: before the treatment the patients were 87 (81.3%), and after the therapy the number of patients decreased to 52 (48.6%).

CD8 cells were detected before treatment in 69 (64.5%) patients, and in only 37 (34.6%) patients after treatment.

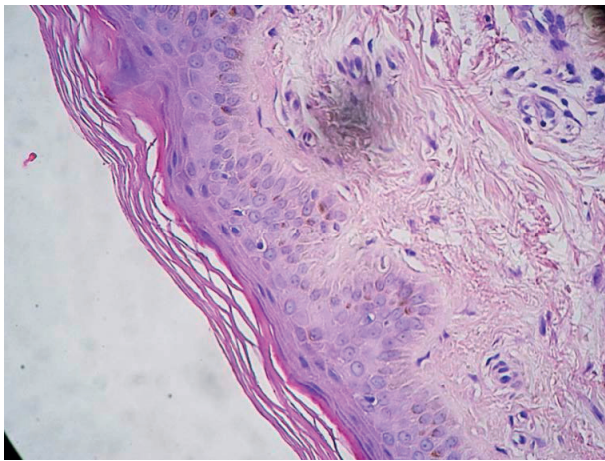


Figure 2 - Patient A., 38 y.o. After 16 weeks of therapy: hyperkeratosis is persisted in epidermis, there is a granulosis, vacuolation and spongiosis decrease. Weak lymphocytic infiltration in epidermis persists. Hematoxylin-eosin staining, X20.

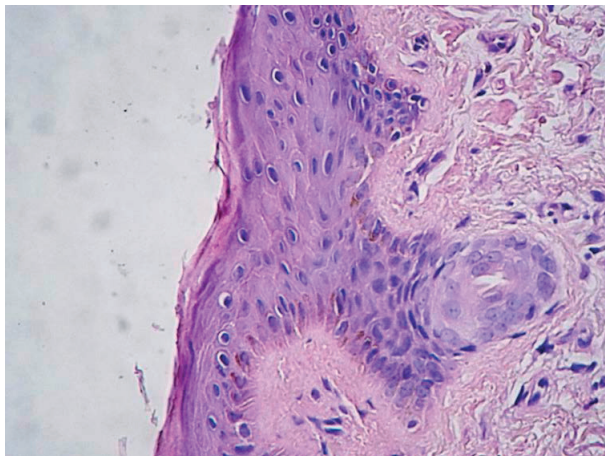


Figure 3 - Patient C., 59 y.o. After 16 weeks of therapy: hyperkeratosis in epidermis regressed, hypergranulosis is absent, a significant decrease in vacuolation and spongiosis. Weak lymphocytic infiltration persists. Hematoxylin-eosin staining, X20.

It is essential to notice the increase in the number of patients showing a positive response to S100 and Melan A staining after 16 weeks of therapy. Before treatment, only 34 (31.8%) patients showed a positive reaction to S100 staining, while after treatment, this number increased to 71 (66.4%) patients. Similarly, Melan A staining was not detected in any of the 107 patients before treatment, but after 16 weeks of therapy, 45 (42.1%) patients showed a positive reaction. (Figure 4).

To assess the effectiveness of the developed treatment method, a comparative histological and immunohistochemical studies were performed in two patient groups, including the main one, in which patients received the treatment which followed the developed method using a melanocyte-keratinocyte suspension (MKS) and automezoconcentrate (AMC) and a comparison group in which patients received the traditional treatment (Tables 1, 2).

The Analysis of epidermal and dermal changes in both groups showed significant differences. Hyperkeratosis persisted after treatment in 21 (41.2%) patients in the comparison group, instead in the main group, only 11 (19.6%) patients had persistent hyperkeratosis. Granulosis was observed in 15 (29.4%) patients in the comparison group and only 7 (12.5%) patients in the main group, while acanthosis was present in 13 (25.5%) patients in the comparison group and only 5 (8.9%) patients in the main group.

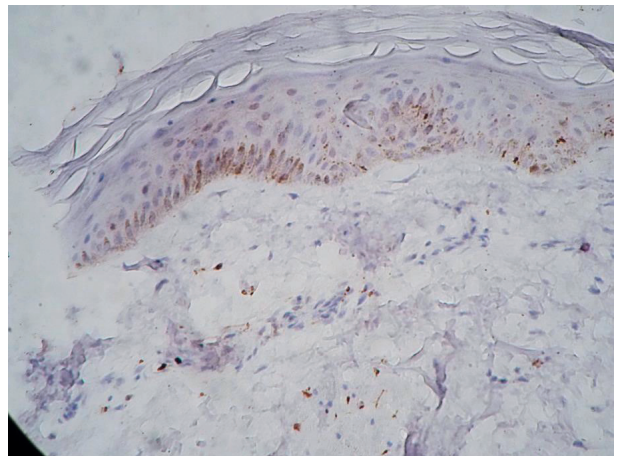


Figure 4 - Patient M., 39 y.o. After 16 weeks of therapy there is a significant number of melanocytes in the epidermis with staining S-100. X10.

Table 3 - Histological parameters in vitiligo patients in the study group after 16 weeks of therapy

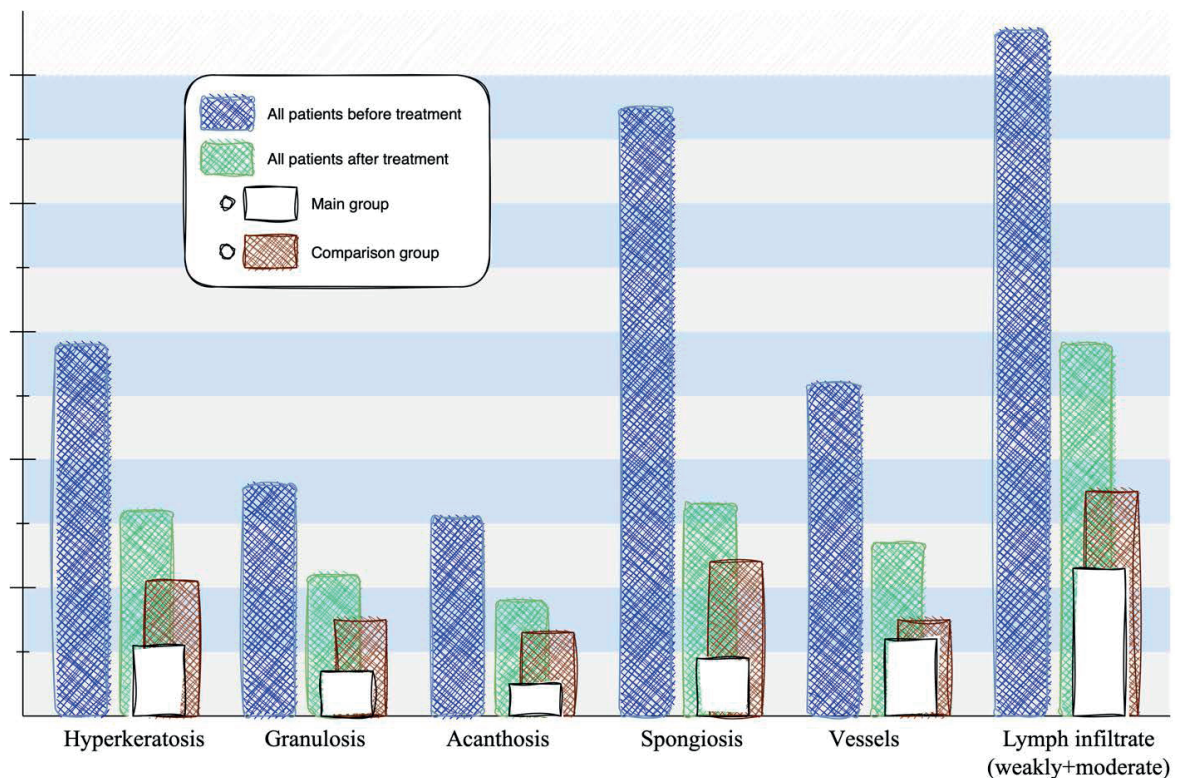
Parameter	All patients (n=107)		Main group (n=56)		Comparison group (n=51)		p-value
	abs.	%	abs.	%	abs.	%	
Hyperkeratosis	32	29,9	11	19,6	21	41,2	0,020
Granulosis	22	20,6	7	12,5	15	29,4	0,034
Acanthosis	18	16,8	5	8,9	13	25,5	0,037
Spongiosis	33	30,8	9	16,1	24	47,1	<0,001
Enlargement of the vessels of the dermal microcirculatory tract	27	25,2	12	21,4	15	29,4	0,379
Lymphocytic infiltrate							0,017
· absent	49	45,8	33	58,9	16	31,4	
· weakly expressed	39	36,4	16	28,6	23	45,1	
· moderate expressed	19	16,8	7	12,5	12	23,5	
· sharply expressed	0	0	0	0	0	0	

A similar trend can be observed in spongiosis, which persisted in every second patient in the comparison group - 24 (47.1%) patients - and was detected in only 9 (16%) patients from the main group.

Enlarged vessels of the dermis microcirculatory tract after 16 weeks of treatment were preserved in 15

(29.4%) patients in the comparison group and only in 12 (21.4%) patients of the main group.

The dermal lymphocytic infiltrate remained prominent in 12 (23.5%) patients in the comparison group and only in 7 (12.5%) patients in the main group. Notably, after 16 weeks of treatment, the der-



Histogram 1 - Histological parameters in vitiligo patients in the study group before and after the treatment.

mal lymphocytic infiltrate was absent in 33 (58.9%) patients who received the developed method using KS and AMC, while only 16 (31.4%) patients in the comparison group showed this improvement.

There were significant differences between the main and comparison groups in the presence of hyperkeratosis ($p = 0.020$), granulosis ($p = 0.034$), acanthosis ($p = 0.037$), spongiosis ($p < 0.001$), and the incidence of lymphocytic infiltrate ($p = 0.017$). However, there was no significant difference in the increase in the number of microcirculatory tract vessels ($p = 0.379$) between the two groups (Table 3).

Schematically, this data can be represented by the following histogram, which indicates the frequency of occurrence of the described histological features before and after the treatment. Moreover, after the treatment, the main and comparison groups are also indicated separately (Histogram 1). To make the information easier to understand, we have combined weakly and moderate expressed lymphocytic infiltrates into one histological parameter.

Upon a comparative analysis of the immunohistochemical parameters, the developed treatment method using KS and AMC was found to be highly effective. The number of patients showing a positive response to CD3 decreased to 42 (75%) in the main group after treatment, and to 39 (76.5%) in the comparison group. In the main group, after 16 weeks of treatment, CD4 was detected in 24 patients (42.9%), and in the comparison group it was detected in 28 patients (54.9%).

A more significant trend was observed in the analysis of CD8, which was detected in 24 patients (47.1%) in the comparison group after 16 weeks of

treatment, compared to only 13 patients (23.2%) in the main group. The Analysis of the number of patients showing a positive response to S100 after the treatment revealed that in the main group, 44 (78.6%) patients had a positive response, compared to only 27 (52.9%) patients in the comparison group.

The analysis of Melan A was particularly remarkable, as it was not detected in any of the 107 patients before the treatment. After the treatment, Melan A was detected in 51.8% of patients in the main group, treated with the developed method, and only in 31.4% of patients in the comparison group.

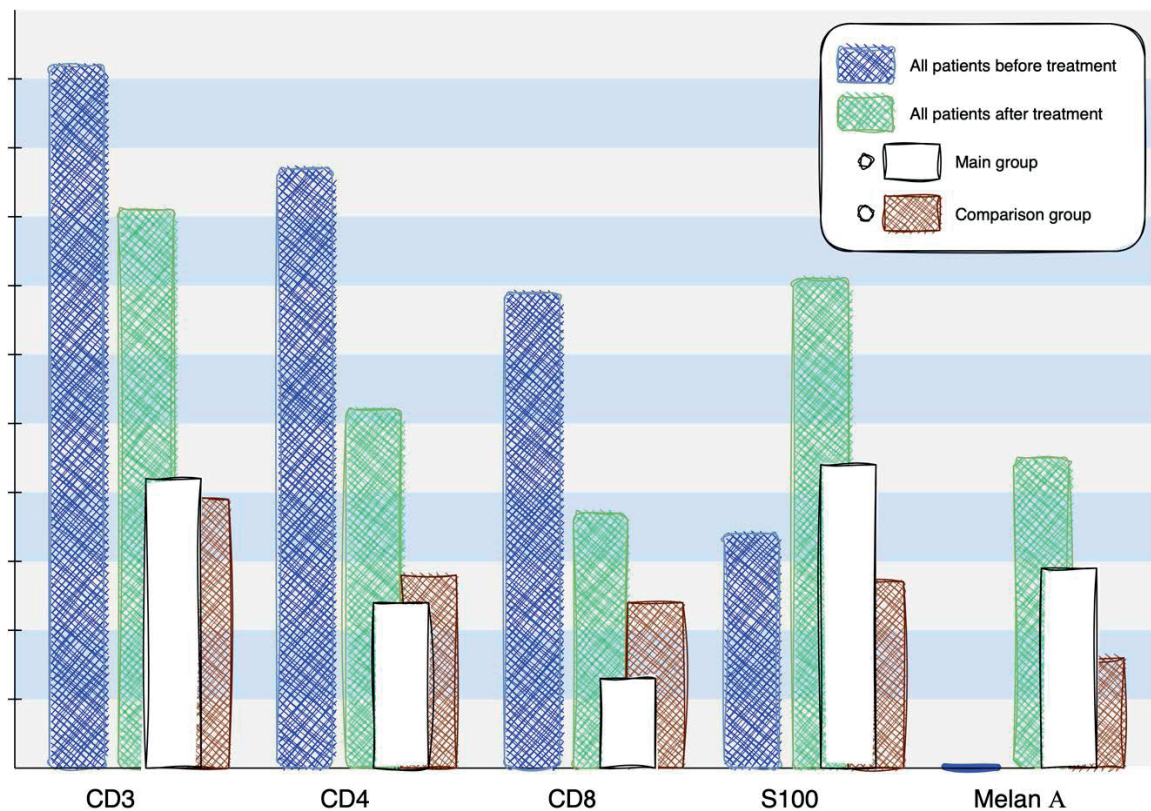
The study results showed no significant difference in the amount of CD3 ($p=1$) and CD4 ($p=0.248$) between the main group and the comparison group. However, a significant difference was observed in the amount of CD8 ($p=0.014$), S100 ($p=0.008$), and Melan A ($p=0.032$) between the two groups (Table 4).

These immunohistochemical parameters before and after treatment also represented at histogram, and after the treatment, the main and comparison groups are also indicated separately (Histogram 2).

Summarizing our comprehensive histological and immunohistochemical studies, it can be noted that the epidermis revealed varying degrees of hyperkeratosis, granulosis, spongiosis and basal keratinocytes vacuolation, accompanied by the absence of Melan A positive and S100 positive melanocytes, that is, the absence of melanocytes; in the dermis, along with a moderate vascular reaction, perivascular lymphocytic infiltrates were detected, which showed a positive reaction to CD3 T-lymphocytes, a positive reaction to CD4 and CD8 cells, with $CD4 > CD8$.

Table 4 - Immunohistochemical parameters in vitiligo patients in the study group after 16 weeks of therapy

Parameter	All patients (n=107)		Main group (n=56)		Comparison group (n=51)		p-value
	abs.	%	abs.	%	abs.	%	
CD3 (DAKO, polyclonal)	81	75,7	42	75,0	39	76,5	1
CD4 (DAKO, clone 4B12)	52	48,6	24	42,9	28	54,9	0,248
CD8 (DAKO, clone C8 / 144B)	37	34,6	13	23,2	24	47,1	0,014
S100 (DAKO, polyclonal)	71	66,4	44	78,6	27	52,9	0,008
Melan A (DAKO, clone A103)	45	42,1	29	51,8	16	31,4	0,032



Histogram 2. Immunohistochemical parameters in vitiligo patients in the study group before and after the treatment.

Discussion and Conclusions. CD8 cells showed a more significant decrease after the treatment, especially in the group that received treatment according to the developed method. It is believed that a more intense CD8 cell response is characteristic of the more active stage of vitiligo, and a decrease in the number of these cells in UVB phototherapy precedes the first manifestations of repigmentation [12; 13;14].

In summary, the comprehensive clinical-histological and immunohistochemical studies revealed the absence or insufficient number of melanocytes in the affected skin and dystrophic changes in keratinocytes that are necessary for the regulation of melanocyte growth and differentiation. These identified changes justified the use in the treatment of vitiligo patients cell techniques aimed at filling the insufficient number of melanocytes in the affected skin, and restoring the normal functioning of keratinocytes.

The developed method of treating vitiligo patients

using MKS and AMC resulted in positive clinical outcomes and a decrease in the severity of dystrophic changes in the epidermis. Melanocyte recovery and reduction/regression of dermal lymphocytic inflammatory infiltrate were also observed, with greater improvements in the main group of patients.

Thus, in the main group of patients treated according to the developed method, there was a more pronounced tendency to restore the epidermal changes of the stratum corneum, epidermal granular layers, restore the epidermal thickness, spongiosis regression, restoration of the microcirculatory vessels number, lymphocytic infiltrate resorption.

The Immunohistochemical analysis showed an increase in the number of melanocytes and dendritic cells with positive markers S100 (DAKO, polyclonal) and Melan A (DAKO, clone A103), with the most significant improvements observed in patients who received a combination of traditional therapy, MKS, and AMC.

Summarizing the comparative analysis of histological changes before and after treatment and pathomorphological changes in therapeutic comparison groups, we can conclude that the use of MKS and AMC has significantly expanded the possibilities and increase the effectiveness of therapeutic strategies in vitiligo.

Conclusions

1. After 16 weeks of therapy, significant changes in the epidermis were observed via hematoxylin-eosin staining: the number of patients with hyperkeratosis decreased from 58 (54.2%) to 32 (29.9%), granulosis - from 36 (33.6%) to 22 (20.6%), acanthosis - from 31 (29%) to 18 (16.8%), spongiosis - from 95 (88.8%) to 33 (30.8%) patients, an increase in the dermal microcirculatory vessels - from 52 (48.6%) to 27 (25.2%), severe dermal lymphocytic infiltrate - from 38 (35.5%) to 19 (16.8%) patients, mild dermal lymphocytic infiltrate - from 69 (64.5%) to 39 (36.4%) patients. Prior to treatment, there were no patients without dermal lymphocytic infiltrate, and after treatment, 49 (45.8%) patients were noted.
2. When comparing immunohistochemical parameters in vitiligo patients before and after treatment, the significant decrease in the number of patients who showed a positive response to CD3 cells - from 102 (95.3%) to 81 (75.7%) patients, respectively, CD4 cells - from 87 (81.3%) to 52 (48.6%), CD8 cells - from 69 (64.5%) to 37 (34.6%) patients. Comparisons in S100 staining, which were detected before the treatment in only 34 (31.8%) patients, and after 16 weeks of therapy - in 71 (66.4%) patients and Melan A, which before treatment were not detected in any of the 107 observations, and after 16 weeks of therapy - in 45 (42.1%) patients, were particularly significant.
3. In the main group of patients treated according to the developed method, there was a more pronounced tendency to restore epidermal changes of the stratum corneum, granular layers of the epidermis, restore the epidermal thickness, spongiosis regression, restoration of dermal microcirculatory vessels, lymphocytic infiltrate resorption. Particularly pronounced positive dynamics was found from the immunohistochemical analysis, which showed an increase in the number of melanocytes and dendritic cells with positive markers S100 (DAKO, polyclonal) and Melan A (DAKO, clone A103), most pronounced in patients of the main group.
4. Comparisons of clinical-histological and immunohistochemical features of the affected skin in vitiligo patients in the comparison groups confirmed the advantages of the developed treatment method using MKS and AMC.

Conflict of interest: none.

References

1. Bologna JL, Schaffer JV, Cerroni L. Vitiligo and other disorders of hypopigmentation. *Dermatology*, 4th edition. 2018: 1250-61.
2. Salzes C, Abadie S, Seneschal J, et al. The Vitiligo Impact Patient Scale (VIPs): Development and Validation of a Vitiligo Burden Assessment Tool. *J Invest Dermatol*. 2016; 136(1):52-8.
3. Zhang Y, Cai Y, Shi M, et al. The Prevalence of Vitiligo: A Meta-Analysis. *PLoS One*. 2016; 11(9):e0163806.
4. Lomonosov KM, Gereichanova LG. Algoritm lecheniya vitiligo. *Russian Journal of Skin and Venereal Diseases*. 2016; 19(3):167-169.
5. Nargis Khan N, Sharique AA, Parveen N. The intricacies of vitiligo with reference to recent updates in treatment modalities. *European journal of pharmaceutical and medical research*. 2018; 5(02): 187-196.
6. Iannella G, Greco A, Didona D. et al. Vitiligo: Pathogenesis, clinical variants and treatment approaches. *Autoimmun Rev*. 2016; 15(4):335-43.
7. Mohammad TF, Hamzavi IH. Surgical Therapies for Vitiligo. *Dermatol Clin*. 2017; 35(2):193-203.
8. Mutalik S, Shah S, Sidwadkar V, Khoja M. Efficacy of Cyclosporine After Autologous Noncultured Melanocyte Transplantation in Localized Stable Vitiligo - A Pilot, Open Label, Comparative Study. *Dermatol Surg*. 2017; 43(11):1339-1347.
9. Tsepikolenko V, Karpenko K. Combined treatment of stable vitiligo using cell technologies. 24th World Congress of Dermatology, Milan, Italy: 2019 (poster presentation and abstract).
10. Tsepikolenko V, Karpenko K. Combined treatment of stable vitiligo treatment using autologous cultured mel-

- anocytes and keratinocytes suspension. 28th Congress of the European Academy of Dermatology and Venereology, Madrid, Spain: 2019 (poster presentation and abstract).
11. Sposib otrimannya kriolizatu trombocitiv ludini: patent 112536 Ukraine: MPK C12M 1/02, A61K 35/19, A61P 7/02. No u 2016 05254; claim. 16.05.2016; publ. 26.12.2016, Bul. No 24.
 12. Lahiri K, Malakar S. The concept of stability of vitiligo: a reappraisal. *Indian J Dermatol.* 2012; 57(2):83–9.
 13. Benzekri L, Gauthier Y, Hamada S, Hassam B. Clinical features and histological findings are potential indicators of activity in lesions of common vitiligo. *Br J Dermatol.* 2012; 168(2):265–271.
 14. Ezzedine K, Lim HW, Suzuki T, et al. Revised classification / nomenclature of vitiligo and related issues: the Vitiligo Global Issues Consensus Conference. *Pigment Cell Melanoma Res.* 2012; 25(3):1–13.

Received: 10 December 2021

Accepted: 27 March 2023

Corresponding author:

Kateryna Karpenko

Phone: +380503363028

e-mail: katerina@karpenko.od.ua