

R E V I E W

Predictive factors of volumetric reduction in lumbar disc herniation treated by O₂-O₃ chemiodiscolysis

Alberto Negro^{1,2}, Aldo Paolucci³, Camilla Russo⁴, Martina Di Stasi⁴, Pasquale Guerriero⁵, Francesco Arrigoni⁶, Federico Bruno⁶, Francesco Pagnini⁷, Salvatore Alessio Angileri⁸, Pierpaolo Palumbo⁶, Carlo Masciocchi⁶, Gianfranco Puoti⁹, Fabio Tortora⁴, Ferdinando Caranci¹⁰

¹ Ospedale del Mare – ASL NA1, Neuroradiology Unit, Naples, Italy; ² Dipartimento di Scienze Mediche, Chirurgiche, Neurologiche, Metaboliche e dell'invecchiamento, University of Campania "Luigi Vanvitelli", Naples, Italy; ³ Ospedale Maggiore Policlinico Milano, Milan, Italy; ⁴ Advanced Biomedical Sciences Department University of Naples "Federico II", Napoli, Italy; ⁵ Department of Medicine and Health Sciences "V. Tiberio", University of Molise, Campobasso, Italy; ⁶ Department of Biotechnology and Applied Clinical Sciences, University of L'Aquila, L'Aquila, Italy; ⁷ Department of Medicine and Surgery, Unit of Radiology, University of Parma, Parma, Italy; ⁸ Operative Unit of Radiology, Fondazione IRCCS Ca' Granda Ospedale Maggiore Policlinico di Milano, Milan University, Via Francesco Sforza, 35, 20122, Milan, Italy; ⁹ Second Division of Neurology, Department of Advanced Medical and Surgical Sciences, University of Campania "Luigi Vanvitelli", Naples, Italy; ¹⁰ Department of Precision Medicine, University of Campania Luigi Vanvitelli, Naples, Italy

Summary. *Purpose:* Aim of this study is to assess the effectiveness of O₂-O₃ percutaneous chemiodiscolysis by evaluating volumetric changes in lumbar disc herniation on magnetic resonance imaging, in order to identify possible pre-treatment factors affecting such changes. *Methods:* Between January 2014 and December 2017, a total of 87 patients with low back pain and 103 lumbar disc herniations with MRI confirmation were considered for O₂-O₃ chemiodiscolysis. The volume of each herniated disc was determined before and after the treatment. *Results:* Multiple linear regression analysis showed a strong correlation between post-treatment LDH volume percent change and both pre-treatment LDH volume and pre-treatment EQ-VAS ($p < 0.05$), while age showed only a weak positive correlation with post-treatment LDH volume percent change ($p < 0.1$). No association was found for other factors, such as sex and herniation disc level. *Conclusions:* In conclusion, age, baseline LDH volume and self-assessed disease severity score could represent three easy accessible outcome predictive parameters to consider when intradiscal O₂-O₃ chemiodiscolysis is envisaged. Better results after intradiscal O₂-O₃ chemiodiscolysis were obtained in older patients with higher pre-treatment LDH volume and low-moderate pre-treatment EQ-VAS. (www.actabiomedica.it)

Keywords: Lumbar Disc Herniation, Magnetic Resonance Imaging, Chemiodiscolysis, Minimally Invasive Surgery, Oxygen-Ozone Therapy

Abbreviations

Lumbar Disc Herniation = LDH; Magnetic Resonance Imaging = MRI; EuroQol Visual Analogue Scale = EQ-VAS; Cross Sectional Area = CSA; Diffusion-Weighted Imaging = DWI; Apparent Diffusion Coefficient = ADC.

Introduction

Degenerative disease of the intervertebral disc presenting as symptomatic lumbar disc herniation represents one of the most frequent causes of low back pain and functional limitation in adult population, with variable onset (ranging from acute to chronic) and symptoms intensity. Magnetic resonance imag-

ing is one of the most largely used imaging tool in many diagnostic and interventional settings thanks to its intrinsic excellent soft tissue contrast and the absence of ionizing radiation compared to CT (1-9).

Despite disc herniation can resorb spontaneously and associated symptoms can be relieved by conservative therapy, indications for surgical approach should be considered in case of drug-resistant persistent pain. At present the most appropriate surgical choice remains unclear, with recent evidences suggesting that minimally invasive techniques can be adopted prior to invasive surgery. Among these techniques, percutaneous intradiscal ozone injection has successfully and safely been used, with encouraging results in different clinical trials on large and representative populations (10, 11). Indeed ozone, a gas normally present in the atmosphere, can be used in combination with oxygen (O_2-O_3) at low concentrations for chemiodiscolysis; its main indication is low back pain (independently from radicular pain) refractory to 4-6 weeks of conservative therapy, in absence of motor deficits. Percutaneous CT-guided intradiscal injection is performed with thin needle (18-22gauge), and it is usually complemented by peri-ganglionic injection of corticosteroids and anaesthetics (12). This combination ensures immediate pain relief and allows for ozone to display its beneficial effects, including reversion of local venous stasis, anti-inflammatory effect and anti-nociceptor analgesic activity. O_2-O_3 chemiodiscolysis is a cost-effective procedure, with low complication rate and the possibility of being repeated in the same patient without precluding recourse to different surgical techniques in case of failure. However, despite its many advantages, O_2-O_3 chemiodiscolysis still raises some concerns in patients' selection and outcome optimization. Aim of this study is to assess the effectiveness of O_2-O_3 percutaneous chemiodiscolysis by evaluating volumetric changes in lumbar disc herniation (LDH) on magnetic resonance imaging (MRI), in order to identify possible pre-treatment factors affecting such changes.

Materials and Methods

Patients' selection

Between January 2014 and December 2017 we

prospectively recruited 146 patients (86 males, 58,9%; 60 females, 41,1%; mean age 54,6y, $DS\pm 13,9y$, range 24-83y) with low back pain following a dermatomal distribution and MRI confirmation of single- or multiple-level LDH, who were considered for O_2-O_3 chemiodiscolysis; 14 patients presented with disc herniation at two levels, while 3 patients at three levels. Patients referred to our department for well-discriminated persistent dermatomal pain with positive Lasègue test. The inclusion criteria were: single- or multiple-level LDH at MRI examination; 3-months long conservative treatment failure; age >18y and <85y. Exclusion criteria were: significant structural deformity of the spine, severe vertebral osteoarthritis, fractures or calcified hernias (13); neurological motor deficit or cauda equina syndrome; infectious, inflammatory or neoplastic bone lesions (14-16); former contraindications to undergo MRI examination; absolute contraindications to CT-guided procedure, including allergy to proposed drugs and pregnancy (17). The presence of bleeding disorders, glucose-6-phosphate dehydrogenase deficiency, hyperthyroidism, severe anaemia, myasthenia, recent myocardial infarction and history of mental disorders were considered relative contraindications, therefore evaluated on a case-by-case basis. Finally, 87 patients (48 males, 55,2%; 39 females, 44,8%; mean age 53,7y, $DS\pm 13,1y$, range 24-83y) were eligible for chemiodiscolysis, and a total number of 103 LDH were considered for statistical purposes (L5 n=25; L4 n=56; L3 n=15; L2 n=7). Before minimally invasive treatment, each patient was asked to rate disease severity by using the self-reported EuroQol Visual Analogue Scale (EQ-VAS) for pain intensity measurement. After therapy, all patients undergone chemiodiscolysis performed a follow-up lumbar spine MRI examination within 6 months from treatment (mean interval 19,7w; $DS\pm 7,2w$; range 10-29w). The study was formerly approved by local Institutional Board, and written informed consent was preliminarily obtained from each patient.

Intradiscal O_2-O_3 chemiodiscolysis

Intradiscal O_2-O_3 chemiodiscolysis is carried out in a one-day surgery regimen; preliminary CT examination is performed to identify the infiltration

point and measure the distance from the conjugate foramen. The patient is placed on the imaging bed in prone position, with a cushion to reduce the physiological lumbar lordosis. CT scans are focused on the level to be treated and the entry point is marked with demographic pencil; the needle is introduced with an angle of 45° from the skin plane under CT guidance. Treatment consisted of 15ml O₂-O₃ injection (concentration: 30µg/ml), partly injected directly into the herniated disc (3-4ml) and partly in the periradicular/paravertebral soft tissues (11-12ml); using the same needle, the procedure is concluded with intraforaminal injection of corticosteroid (1mL, 40mg methylprednisolone) and local anaesthetic (1mL, 0.5% marcaine). A final CT scan to check gas distribution was also performed in order to exclude possible complications.

MRI examination and volume changes assessment

Pre- and post-operative lumbar spine MRI examinations carried on a 1.5T scanner included a sagittal TSE-T2w sequence (TE=100ms; TR=3000ms; NA=3; FA=90; slice thickness=3mm; spacing between slices=0), along with other axial and sagittal conventional T1w and T2w sequences. Two experienced neuroradiologists in consensus, different from the ones of team that performed the chemiodiscolysis, provided

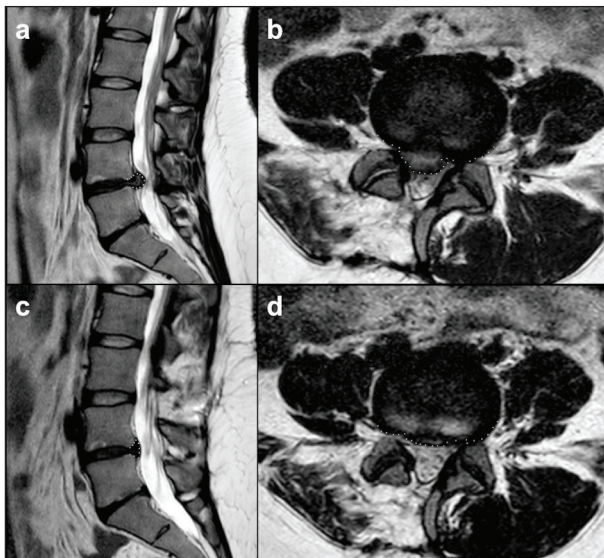


Figure 1 Sagittal and axial TSE-T2w MRI images on the most representative level, showing an example of LDH measurements before (a-b) and after (c-d) intradiscal O₂-O₃ chemiodiscolysis.

LDH measurements on raw MRI images. Lateral insertion positions of LDH were defined as the points showing the greatest contrast between the structures, while intervertebral disc height was defined as the distance between the middle portions of each endplate at the level of the affected disc. The contained affected disc was defined as the material located in the intervertebral space behind the intervertebral height line; conversely, the outer disc herniation was included until its borders became visually indistinguishable. Disc signal intensity and type of disc herniation (protruded, contained, extruded, sequestered, free fragment and migrated disc herniation) were also considered. For both time-points (pre- and post-operative MRI examination), LDH volume was assessed by hand-drawing height and cross sectional area (CSA) of the herniated disc located between the lateral margins of the vertebral pedicles (18), and computed by using the OsiriX “Compute Volume Tool”. An example of LDH measurements before and after intradiscal O₂-O₃ chemiodiscolysis is shown in **Figure 1**.

Statistical analysis

Multiple linear regression analysis was used to describe the relationship between LDH volume variation after intradiscal O₂-O₃ chemiodiscolysis and independent variables including age, sex, disc level, LDH volume at MRI diagnosis and pre-treatment self-assessed score of disease severity (EQ-VAS). To explain variation in treatment response that can be attributed to each explanatory variable, linear regression analysis was then applied; goodness of fit of regression was analysed using R² along with *p*-value. All statistical analysis was performed using XLSTAT software v.2019.1 (Addinsoft).

Results

LDH mean volume before treatment at baseline MRI examination was 0,58cm³(DS±0,29cm³), versus 0,43cm³(DS±0,23cm³) after treatment at MRI follow-up (mean variation -0,15±0,19; -20,4%, DS±44,6%); in 87,2% cases a reduction in LDH volumes was computed, in 10,9% cases there was a slight

increase in LDH size, while in the remaining 1,9% cases no significant variation was observed. Concerning self clinical assessment, mean EQ-VAS at baseline was 23,4 (DS±18,1), versus 59,2 (DS±25,1) after treatment (mean difference +35,7±30,9); 81,4% patients experiences an improvement in perception of disease severity, 9,7% patients complained a worsening in clinical symptoms, while the remaining 8,9% patients did not referred significant variation.

Multiple linear regression analysis showed a strong correlation between post-treatment LDH volume percent change and both pre-treatment LDH volume and pre-treatment EQ-VAS ($p < 0.05$), while age showed only a weak positive correlation with post-treatment LDH volume percent change ($p < 0.1$). Adjusted R^2 was 0.114 for the regression equation “ $Y = -0.112810 - 0.392345X_1 + 0.00580527X_2$ ” (with Y =volume percent change; X_1 = pre-treatment LDH volume; X_2 = pre-treatment EQ-VAS). No correlation was found for sex and herniation disc level. Multiple linear regression analysis results are shown in **Table 1**. Linear correlation for bivariate data showed a significant negative correlation between post-treatment LDH volume percent change and pre-treatment LDH volume ($p = 0.013$), as well as a significant positive correlation between post-treatment LDH volume percent change and pre-treatment EQ-VAS ($p = 0.021$). Bivariate lin-

ear correlation analysis results are resumed in **Table 2**, and plotted in **Figure 2**.

Discussion

Back pain is one of the most common health problems affecting western population (19), and can be attributed to a wide range of disorders recognizing different aetiologies (8, 20-23). Among the possible aetiologies, LDH represents the most common cause (up to half cases of low back pain associated to sciatic symptoms are generated by disc herniation) (13, 16). The mechanism underlying low back radicular pain is multifactorial. Beyond the clinical evaluation, imaging plays a fundamental role in the initial assessment and cost-effective patient management; CT and MR imaging are considered the modality of choice, as in the study of other pathologies (24-34).

Indeed, LDH determine both variable direct compression of nerve root/dorsal root ganglion and indirect compression on perineural vessels, causing local venous stasis and ischemia. Moreover the injured herniated disc determines focal inflammation with subsequent involvement of facet capsule, epidural tissue surrounding nerve root and nerve root itself; the subsequent inflammatory cascade sensitizes neural no-

Table 1 Multiple linear regression analysis results of patients' variables (pre-treatment LDH volume, age and pre-treatment EQ-VAS, respectively) with post-treatment LDH volume percent change ($p < 0.05$)

Patients' variables	b	p-value	Post-treatment LDH volume percent change	
			Lower limit	Upper limit
			95% CI	
Pre-treatment LDH volume	-0.394368	0.008 ($p < 0.05$)	-0.682803	-0.105933
Age	-0.00551925	0.088 ($p > 0.05$)	-0.0118802	0.000841720
Pre-treatment EQ-VAS	0.00526179	0.026 ($p < 0.05$)	0.000651827	0.00987176

Legend: LDH=lumbar disc herniation; b=regression coefficient; CI=confidence interval; EQ-VAS=EuroQol Visual Analogue Scale.

Table 2 Bivariate linear correlation analysis results of patients' pre-treatment variables with post-treatment LDH volume percent change ($p < 0.05$).

Patients' variables	r	R2	Post-treatment LDH volume percent change
			p-value
Pre-treatment LDH volume	-0.243	0.059	0.013
Age	-0.187	0.035	0.057
Pre-treatment EQ-VAS	0.226	0.051	0.021

Legend: LDH=lumbar disc herniation; r=correlation coefficient; R2=R-squared; EQ-VAS=EuroQol Visual Analogue Scale.

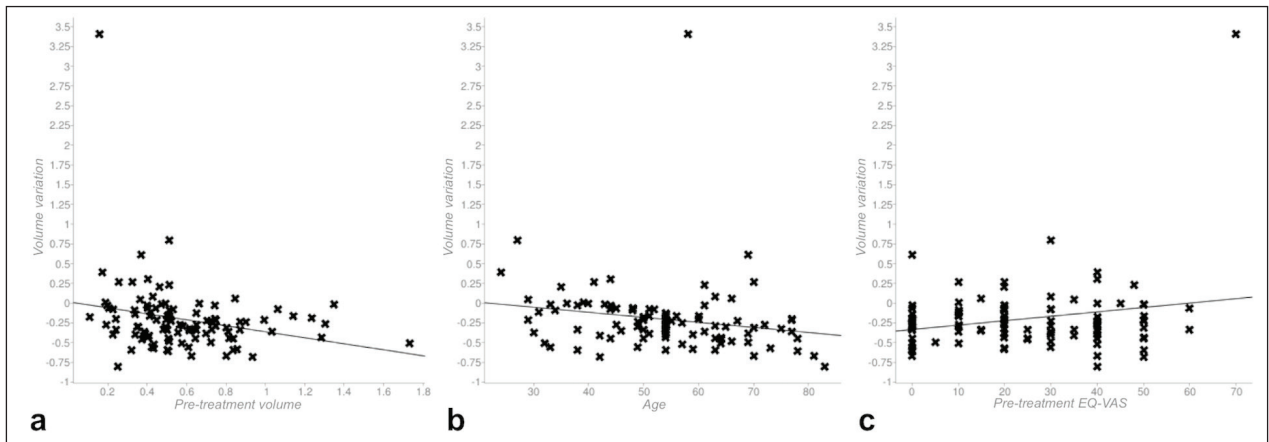


Figure 2 Bivariate linear correlation showing: (a) significant inverse correlation between post-treatment LDH volume percent change and pre-treatment LDH volume; (b) lack of significant association between post-treatment LDH volume percent change and patients' age; (c) significant positive correlation between post-treatment LDH volume percent change and pre-treatment EQ-VAS.

ciceptors and reduces pressure pain threshold (14, 16, 35).

LDH natural history is variable, and it is well known that disc herniation can resorb spontaneously and associated symptoms can be relieved by conservative therapy only (18). Therefore indications for surgical approach should be considered in case of drug-resistant persistent pain, when symptoms of LDH are refractory to initial conservative management (36, 37). However, before resorting to invasive surgery, minimally invasive approaches are often envisaged as a viable alternative to the more conventional open surgical techniques as they offer patients several benefits (including minor tissue trauma, reduced pain, and prompt recovery). Among these techniques, intradiscal O₂-O₃ chemiodiscolysis is one of the most used due to the beneficial antiseptic, immunomodulating, analgesic and anti-inflammatory ozone properties (38). However at present literature evidences from O₂-O₃ chemiodiscolysis compared to conventional surgical techniques are still controversial, with surgical treatment providing faster and greater relief from back pain in patients with LDH (despite no significant difference in results stability over time was observed at mid-term and long-term follow-up) (37). This variability in O₂-O₃ therapy outcome can be at least in part attributed to a challenging patient selection (39).

In this study we analysed potentially predictive factors of LDH volumetric reduction in order to improve patient selection and intradiscal O₂-O₃

chemiodiscolysis results, highlighting the possible role of age, baseline LDH volume and EQ-VAS score in predicting treatment outcome.

On the one hand, our results showed a strong correlation between post-treatment LDH volume percent change and both pre-treatment LDH volume and pre-treatment EQ-VAS ($p < 0.05$). Inverse correlation between post-treatment LDH volume percent change and pre-treatment LDH volume suggest that O₂-O₃ chemiodiscolysis is more effective on larger disc herniation, probably when trans-ligamentous extension and posterior longitudinal ligament disruption makes unlikely an eventual spontaneous reduction (40). At the same time, positive correlation between post-treatment LDH volume percent change and pre-treatment EQ-VAS suggest that O₂-O₃ chemiodiscolysis should be preferred in case of mild clinical symptoms and moderate functional limitations, reserving more invasive approaches to patients with higher disease severity who experiment only limited benefits from minimally-invasive strategies. However it should always be considered that self-rating scales underlie some possible limitations regarding the interpretation of the results, which are mainly related to difficulties in determining how large a change in a certain score should be before it can be considered relevant for the patient.

On the other hand, age showed only a weak positive correlation with post-treatment LDH volume percent change ($p < 0.1$). In recent times age was proposed as one of the factors influencing LDH resorption (41);

indeed herniated disc in older patients is supposed to be more fibrotic and dehydrated compared to the one of younger patients, negatively influencing spontaneous resorption. It is already known that, when considering acute disc herniation typical of younger patients, disc material is hyperintense on T2w sequences in more than 70% cases, with higher tendency to resolution (16). Conversely, when acute symptoms appear in a context of chronic disc herniation, inflammatory response is more involved as chronically damaged disc tissue elicits intense inflammatory changes when exposed to epidural fat/vasculature (42). According to this finding, in our sample the large majority of LDHs in older patients showed a low T2w-hyperintensity (presumably related to poor water content) (14, 15). Probably due to this difference, the LDH volume percent change after intradiscal O₂-O₃ chemiodiscolysis was more satisfying in older patients, where analgesic and anti-inflammatory ozone properties played a prominent role over direct disc dehydration.

Our experience further confirms the pivotal role of MRI in providing crucial data regarding pre-treatment patients' stratification based on LDH morphological features, thus not limiting this technique to simple diagnostic purposes. To this purpose recent evidences also suggested a possible role for diffusion-weighted imaging (DWI) and relative apparent diffusion coefficient (ADC) maps, already commonly used in different clinical settings to predict disease evolution and clinical outcome of various central nervous system disorders (43-45). In particular, LDH with lower ADC values were associated to poor improvement in clinical symptoms after O₂-O₃ chemiodiscolysis (30, 46). However DWI sequences were not available for our patients, therefore further studies are required to assess the possible role of pre-treatment ADC values for patients' selection. Some more limitations to the study should also be considered. First the results are referring to a 6-months long follow-up, and LDH volume reduction stability over time should be monitored on a mid/long-term follow-up; moreover, some additional risk factors that could somehow influence symptoms relapse (including for example weight fluctuations or work/professional activity) should also be considered in future analysis. Finally, it would be useful to assess the reproducibility of the presented results with differ-

ent minimally invasive therapies other than intradiscal O₂-O₃ chemiodiscolysis.

In conclusion the flourishing of non-surgical therapeutic strategies for LDH should benefit of a more precise patients' selection based on clinical data and imaging features, in order to optimize treatment results. Age, baseline LDH volume and self-assessed disease severity score could represent three easy and rapidly accessible outcome predictive parameters to consider when intradiscal O₂-O₃ chemiodiscolysis is envisaged, with better outcome after intradiscal O₂-O₃ chemiodiscolysis in older patients with higher pre-treatment LDH volume and low-moderate pre-treatment EQ-VAS.

Conflict of interest: Authors declare that they have no commercial associations (e.g. consultancies, stock ownership, equity interest, patent/licensing arrangement etc.) that might pose a conflict of interest in connection with the submitted article.

References

1. Arrigoni F, Bruno F, Zugaro L, et al. Developments in the management of bone metastases with interventional radiology. *Acta Biomed* 2018; 89: 166-74.
2. Masciocchi C, Arrigoni F, La Marra A, Mariani S, Zugaro L, Barile A. Treatment of focal benign lesions of the bone: MRgFUS and RFA. *The British journal of radiology* 2016; 89: 20150356-56.
3. Tortora F, Cirillo M, Belfiore MP, et al. Spontaneous regression of dilated Virchow-Robin spaces. A case report. *Neuroradiol J* 2012; 25: 40-4.
4. Giordano AV, Arrigoni F, Bruno F, et al. Interventional Radiology Management of a Ruptured Lumbar Artery Pseudoaneurysm after Cryoablation and Vertebroplasty of a Lumbar Metastasis. *Cardiovasc Intervent Radiol* 2017; 40: 776-79.
5. Michelini G, Corridore A, Torlone S, et al. Dynamic MRI in the evaluation of the spine: state of the art. *Acta Biomed* 2018; 89: 89-101.
6. Cazzato RL, Arrigoni F, Boatta E, et al. Percutaneous management of bone metastases: state of the art, interventional strategies and joint position statement of the Italian College of MSK Radiology (ICoMSKR) and the Italian College of Interventional Radiology (ICIR). *Radiol Med* 2019; 124: 34-49.
7. Perri M, Grattacaso G, di Tunno V, et al. T2 shine-through phenomena in diffusion-weighted MR imaging of lumbar discs after oxygen-ozone discolysis: a randomized, double-blind trial with steroid and O₂-O₃ discolysis versus steroid only. *Radiol Med* 2015; 120: 941-50.

8. de Divitiis O, Elefante A. Cervical spinal brucellosis: a diagnostic and surgical challenge. *World Neurosurg* 2012; 78: 257-9.
9. Carrafiello G, Fontana F, Mangini M, et al. Initial experience with percutaneous biopsies of bone lesions using Xper-Guide cone-beam CT (CBCT): technical note. *Radiol Med* 2012; 117: 1386-97.
10. Giurazza F, Guarnieri G, Murphy KJ, Muto M. Intradiscal O₂O₃: Rationale, Injection Technique, Short- and Longterm Outcomes for the Treatment of Low Back Pain Due to Disc Herniation. *Can Assoc Radiol J* 2017; 68: 171-77.
11. Murphy K, Muto M, Stepan J, Meaders T, Boxley C. Treatment of Contained Herniated Lumbar Discs With Ozone and Corticosteroid: A Pilot Clinical Study. *Can Assoc Radiol J* 2015; 66: 377-84.
12. Shanthanna H, Busse JW, Thabane L, et al. Local anesthetic injections with or without steroid for chronic non-cancer pain: a protocol for a systematic review and meta-analysis of randomized controlled trials. *Syst Rev* 2016; 5: 18.
13. Kelsey JL, White AA, 3rd. Epidemiology and impact of low-back pain. *Spine (Phila Pa 1976)* 1980; 5: 133-42.
14. Bozzao A, Gallucci M, Masciocchi C, Aprile I, Barile A, Passariello R. Lumbar disk herniation: MR imaging assessment of natural history in patients treated without surgery. *Radiology* 1992; 185: 135-41.
15. Yasuma T, Arai K, Yamauchi Y. The histology of lumbar intervertebral disc herniation. The significance of small blood vessels in the extruded tissue. *Spine (Phila Pa 1976)* 1993; 18: 1761-5.
16. Matsubara Y, Kato F, Mimatsu K, Kajino G, Nakamura S, Nitta H. Serial changes on MRI in lumbar disc herniations treated conservatively. *Neuroradiology* 1995; 37: 378-83.
17. Teplick JG, Haskin ME. Spontaneous regression of herniated nucleus pulposus. *AJR Am J Roentgenol* 1985; 145: 371-5.
18. Seo JY, Roh YH, Kim YH, Ha KY. Three-dimensional analysis of volumetric changes in herniated discs of the lumbar spine: does spontaneous resorption of herniated discs always occur? *Eur Spine J* 2016; 25: 1393-402.
19. Patrick N, Emanski E, Knaub MA. Acute and chronic low back pain. *Med Clin North Am* 2014; 98: 777-89, xii.
20. Shah MK, Stewart GW. Sacral stress fractures: an unusual cause of low back pain in an athlete. *Spine (Phila Pa 1976)* 2002; 27: E104-8.
21. Demir MK, Yilmaz B, Toktas ZO, Akakin A, Eksi MS, Konya D. An unusual cause of low back pain in a young adult: myxopapillary ependymoma of the filum terminale. *Spine J* 2016; 16: e321-2.
22. Leon Salinas JP, Albertz Arevalo N, Belloch Ramos E, Guerrero Espejo A. An unusual cause of low back pain in a patient with sepsis. *Enferm Infecc Microbiol Clin* 2017; 35: 538-40.
23. Elefante A, Caranci F, Del Basso De Caro ML, et al. Paravertebral high cervical chordoma. A case report. *Neuroradiol J* 2013; 26: 227-32.
24. Bruno F, Arrigoni F, Palumbo P, et al. New advances in MRI diagnosis of degenerative osteoarthropathy of the peripheral joints. *Radiol Med* 2019; 124: 1121-27.
25. Arrigoni F, Napoli A, Bazzocchi A, et al. Magnetic-resonance-guided focused ultrasound treatment of non-spinal osteoid osteoma in children: multicentre experience. *Pediatr Radiol* 2019; 49: 1209-16.
26. Cortellini A, Bozzetti F, Palumbo P, et al. Weighing the role of skeletal muscle mass and muscle density in cancer patients receiving PD-1/PD-L1 checkpoint inhibitors: a multicenter real-life study. *Sci Rep* 2020; 10: 1456.
27. Carrafiello G, Lagana D, Pellegrino C, et al. Ablation of painful metastatic bone tumors: a systematic review. *Int J Surg* 2008; 6 Suppl 1: S47-52.
28. Reginelli A, Silvestro G, Fontanella G, et al. Validation of DWI in assessment of radiotreated bone metastases in elderly patients. *International Journal of Surgery* 2016; 33: S148-S53.
29. Splendiani A, D'Orazio F, Patriarca L, et al. Imaging of post-operative spine in intervertebral disc pathology. *Musculoskelet Surg* 2017; 101: 75-84.
30. Perri M, Grattacaso G, Di Tunno V, et al. MRI DWI/ADC signal predicts shrinkage of lumbar disc herniation after O₂-O₃ discolysis. *Neuroradiol J* 2015; 28: 198-204.
31. Bruno F, Smaldone F, Varrassi M, et al. MRI findings in lumbar spine following O₂-O₃ chemiodiscolysis: A longterm follow-up. *Interv Neuroradiol* 2017; 23: 444-50.
32. Patriarca L, Letteriello M, Di Cesare E, Barile A, Gallucci M, Splendiani A. Does evaluator experience have an impact on the diagnosis of lumbar spine instability in dynamic MRI? Interobserver agreement study. *Neuroradiol J* 2015; 28: 341-6.
33. Splendiani A, Bruno F, Patriarca L, et al. Thoracic spine trauma: advanced imaging modality. *Radiol Med* 2016; 121: 780-92.
34. Barile A, Arrigoni F, Bruno F, et al. Present role and future perspectives of interventional radiology in the treatment of painful bone lesions. *Future Oncol* 2018; 14: 2945-55.
35. Weinstein JN, Lurie JD, Tosteson TD, et al. Surgical vs nonoperative treatment for lumbar disk herniation: the Spine Patient Outcomes Research Trial (SPORT) observational cohort. *JAMA* 2006; 296: 2451-59.
36. Chen BL, Guo JB, Zhang HW, et al. Surgical versus non-operative treatment for lumbar disc herniation: a systematic review and meta-analysis. *Clin Rehabil* 2018; 32: 146-60.
37. Gugliotta M, da Costa BR, Dabis E, et al. Surgical versus conservative treatment for lumbar disc herniation: a prospective cohort study. *BMJ Open* 2016; 6: e012938.
38. Boos N, Weissbach S, Rohrbach H, Weiler C, Spratt KF, Nerlich AG. Classification of age-related changes in lumbar intervertebral discs: 2002 Volvo Award in basic science. *Spine (Phila Pa 1976)* 2002; 27: 2631-44.
39. Dall'Olio M, Princiotta C, Cirillo L, et al. Oxygen-ozone therapy for herniated lumbar disc in patients with subacute partial motor weakness due to nerve root compression. *Interv Neuroradiol* 2014; 20: 547-54.

40. Ahn SH, Ahn MW, Byun WM. Effect of the transligamentous extension of lumbar disc herniations on their regression and the clinical outcome of sciatica. *Spine (Phila Pa 1976)* 2000; 25: 475-80.
41. Lee J, Kim J, Shin JS, et al. Long-Term Course to Lumbar Disc Resorption Patients and Predictive Factors Associated with Disc Resorption. *Evid Based Complement Alternat Med* 2017; 2017: 2147408.
42. Jinkins, Whittemore AR, Bradley WG. The anatomic basis of vertebrogenic pain and the autonomic syndrome associated with lumbar disk extrusion. *American Journal of Roentgenology* 1989; 152: 1277-89.
43. van Veluw SJ, Lauer A, Charidimou A, et al. Evolution of DWI lesions in cerebral amyloid angiopathy: Evidence for ischemia. *Neurology* 2017; 89: 2136-42.
44. Elefante A, Cavaliere M, Russo C, et al. Diffusion weighted MR imaging of primary and recurrent middle ear cholesteatoma: an assessment by readers with different expertise. *Biomed Res Int* 2015; 2015: 597896.
45. Rapalino O, Mullins ME. Intracranial Infectious and Inflammatory Diseases Presenting as Neurosurgical Pathologies. *Neurosurgery* 2017; 81: 10-28.
46. Niu X-K, Bhetuwal A, Yang H-F. Diffusion-Weighted Imaging for Pretreatment Evaluation and Prediction of Treatment Effect in Patients Undergoing CT-Guided Injection for Lumbar Disc Herniation. *Korean journal of radiology* 2015; 16: 874-80.

Received: 20 May 2020

Accepted: 10 June 2020

Correspondence:

Fabio Tortora, MD, Associate Professor
Advanced Biomedical Sciences Department
Università degli Studi di Napoli "Federico II"
Via Sergio Pansini 5 – 80131 Napoli
Tel. 0039 081 74623001
Office: +39 071 5964085
E-mail: fabio.tortora@unina.it

