

## Italian Consensus Conference on Guidelines for preoperative treatment in acetabular fractures

*Alessandro Aprato<sup>1</sup>, Michele Nardi<sup>1</sup>, Mario Arduini<sup>2</sup>, Federico Bove<sup>3</sup>, Luigi Branca Vergano<sup>4</sup>, Dario Capitani<sup>3</sup>, Alessandro Casiraghi<sup>5</sup>, Matteo Cavanna<sup>6</sup>, Gabriele Cominetti<sup>1</sup>, Matteo Commessatti<sup>7</sup>, Marco Favuto<sup>1</sup>, Alberto Ferrelì<sup>8</sup>, Alberto Fino<sup>1</sup>, Stefano Gulli<sup>9</sup>, Federico Lamponi<sup>10</sup>, Alessandro Massè<sup>1</sup>, Umberto Mezzadri<sup>3</sup>, Mauro Monesi<sup>11</sup>, Antonello Pannella<sup>12</sup>, Giovanni Pesenti<sup>3</sup>, Michel Orasnky<sup>13</sup>, Federico Santolini<sup>14</sup>, Marco Stella<sup>15</sup>, Domenico Tigani<sup>7</sup>, Kristijan Zoccola<sup>16</sup>, Guido Rocca<sup>17</sup>*

<sup>1</sup>Azienda Ospedaliero Universitaria Città della Salute e della Scienza, Torino, Italy; <sup>2</sup>Ospedale Sant'Eugenio di Roma, Roma, Italy; <sup>3</sup>Ospedale Niguarda Ca' Granda, Milano, Italy; <sup>4</sup>Ospedali di Trento e Borgo Valsugana, Trento, Italy; <sup>5</sup>Spedali Civili di Brescia, Brescia; <sup>6</sup>Humanitas Reseach Hospital, Rozzano, Italy; <sup>7</sup> Ospedale Maggiore, Bologna, Italy; <sup>8</sup>Ospedali Sirai di Carbonia, Sirai, Italy; <sup>9</sup>Ospedale Maggiore di Trieste, Italy; <sup>10</sup>Ospedale Infermi, Rimini, Italy; <sup>11</sup> Ospedale M. Bufalini, Cesena, Italy; <sup>12</sup>Ospedale Policlinico, Bari, Italy; <sup>13</sup>Aurelia Hospital, Roma, Italy; <sup>14</sup>Ospedale Policlinico San Martino, Genova, Italy; <sup>15</sup>Ente ospedaliero ospedali Galliera, Genova, Italy; <sup>16</sup>Ospedale Civile Santi Antonio e Biagio e Cesare Arrigo, Alessandria; <sup>17</sup>Ospedale di Camposampiero, Camposampiero PD, Italy.

**Abstract.** Preoperative management of acetabular fracture is a major problem and no consensus has been reached in literature on the optimal treatment of this problem. We present the results of the First Italian Consensus Conference on Acetabular fracture. An extensive review of the literature has been undertaken by the organizing committee and forwarded to the panel. Members were appointed by surgical experience with acetabular fractures. From November 2017 to January 2018, the organizing committee undertook the critical revision and prepared the presentation to the Panel on the day of the Conference. Then 11 recommendations were presented according to the 11 submitted questions. The Panel voted the recommendations after discussion and amendments with the audience. Later on, a second debate took place in September 2018 to reach a unanimous consent. We present results of the following questions: does hip dislocation require reduction? Should hip reduction be performed as soon as possible? In case of unsuccessful reduction of the dislocation after attempts in the emergency department, how should it be treated? If there is any tendency toward renewed dislocation, how should it be treated? Should Computed Tomography (CT) scan be performed before reduction? Should traction be used? How can we treat the pain? Is preoperative ultrasound exam to rule out vein thrombosis always necessary? Is tranexamic acid intravenous (IV) preoperatively recommended? Which antibiotic prophylactic protocols should be used? Is any preoperative heterotopic ossification prophylaxis suggested? In this article we present the indications of the First Italian Consensus Conference: a hip dislocation should be reduced as soon as possible. If unsuccessful, surgeon may repeat the attempts optimizing the technique. Preoperative CT scan is not mandatory before reduction. Skeletal traction is not indicated in most of the acetabular fracture. Standard pain and antibiotic prophylactic protocols for trauma patient should be used. Preoperative ultrasound exam is not recommended in all acetabular fracture. Tranexamic acid should be preoperatively used. There is no indication for preoperative heterotopic ossification. ([www.actabiomedica.it](http://www.actabiomedica.it))

**Keywords:** Acetabular fracture, hip dislocation, hip reduction, fracture management, preoperative management

## Background

Acetabular fractures are rare injuries in heterogeneous patient groups, making it difficult to develop adequately powered prospective studies. In the last decades literature has been able to describe epidemiology, fracture classifications, experience based protocols of surgical treatment and outcomes but, despite the strong interest of clinicians and researchers in this topic, there is still no evidence to guide the preoperative management of those fractures. At the moment there is no consensus about reduction of the femoral head in case of dislocations, timing of reduction, algorithm in case of unsuccessful reduction and/or instability after reduction, timing of preoperative CT scan, indication for skeletal traction, pain management and antibiotic prophylactic protocols, screening with vein sonography to rule out vein thrombosis, use of tranexamic acid in acetabular fracture and the preoperative heterotopic ossification prophylaxis.

### Background of the Italian consensus conference on guidelines for preoperative treatment of acetabular fractures

The first “Italian Consensus Conference on Guidelines for preoperative treatment in acetabular fractures” was organized by the Italian Pelvic Club in Turin, on February 2th 2018, with the participation of 21 national experts. The selection was based on their Hirsch index, the number of publications concerning Acetabular fractures and experience in the clinical evaluation, medical treatment and rehabilitation of those injuries. Furthermore, the experts were not representing any organization. All experts who participated in the Consensus Conference are included as the authors of this report. This paper represents the synthesis of the Italian Consensus Conference on Guidelines for Preoperative Treatment of acetabular fractures.

## Methods

An Organizing Committee (OC) from the Turin Trauma Center (Italy) was established to organize a

National Consensus Conference on preoperative management of acetabular fractures. Regulations in order to conduct the Consensus Conference (CC) were adopted from “The Methodological Manual – How to Organize a Consensus Conference” (1). Levels of evidence (LoE) come from Oxford Centre for Evidence-based Medicine (2).

Eleven specific questions were addressed regarding the main problems related preoperative treatment of acetabular fracture:

1. Does hip dislocation requires reduction?
2. Should hip reduction be performed as soon as possible?
3. In case of unsuccessful reduction of the dislocation after attempts in the emergency department, how should it be treated?
4. If there is any tendency toward renewed dislocation, how should it be treated?
5. Should Computed Tomography (CT) scan be performed before reduction?
6. Should traction be used?
7. How can we treat the pain?
8. Is preoperative ultrasound exam to rule out vein thrombosis always necessary?
9. Is tranexamic acid intravenous (IV) preoperatively recommended?
10. Which antibiotic prophylactic protocols should be used?
11. Is any preoperative heterotopic ossification prophylaxis suggested?

Prior to the Consensus Conference, two authors (AA and MN) independently performed a Higher Health Institute systematic literature review according to PRISMA statements (3).

Medical Subject Headings (MeSH) terms were used with the search string: “Acetabular” and (“Fracture” “hip dislocation” or “hip reduction” or “Computed Tomography” or “traction” or “pain” or “vein thrombosis” or “Tranexemic acid” or “antibiotic” or “heterotopic ossification”). These terms were sequentially searched using the following databases: MEDLINE, PubMed, EMBASE, Scopus, and Cochrane Database of Systematic Reviews. Databases were accessed through CTO hospital in Turin, Italy.

Inclusion criteria consisted of Published studies pertinent to our research question between the years 1991 and 2017. We limited our results to humans and to papers published in the English language.

Study designs consisting of clinical trials, case control studies; retrospective observational studies, systematic review, prospective study, Cochrane database systematic review and case series were included.

Exclusion criteria were: publication in other languages, conferences, abstracts, thesis, unpublished reports and commercial advertisements were excluded.

Initially titles of article which met the inclusion criteria, were screened for primary inclusion and exclusion. All the abstracts obtained were further evaluated for acceptability. The full texts of articles, which met the relevance and inclusion criteria, were obtained and reviewed, paying particular attention to relevance to our research questions. Manual cross – reference search of relevant studies was performed and the related relevant papers were also retrieved. The acquisition of articles is summarized in the flow diagram (Figure. 1).

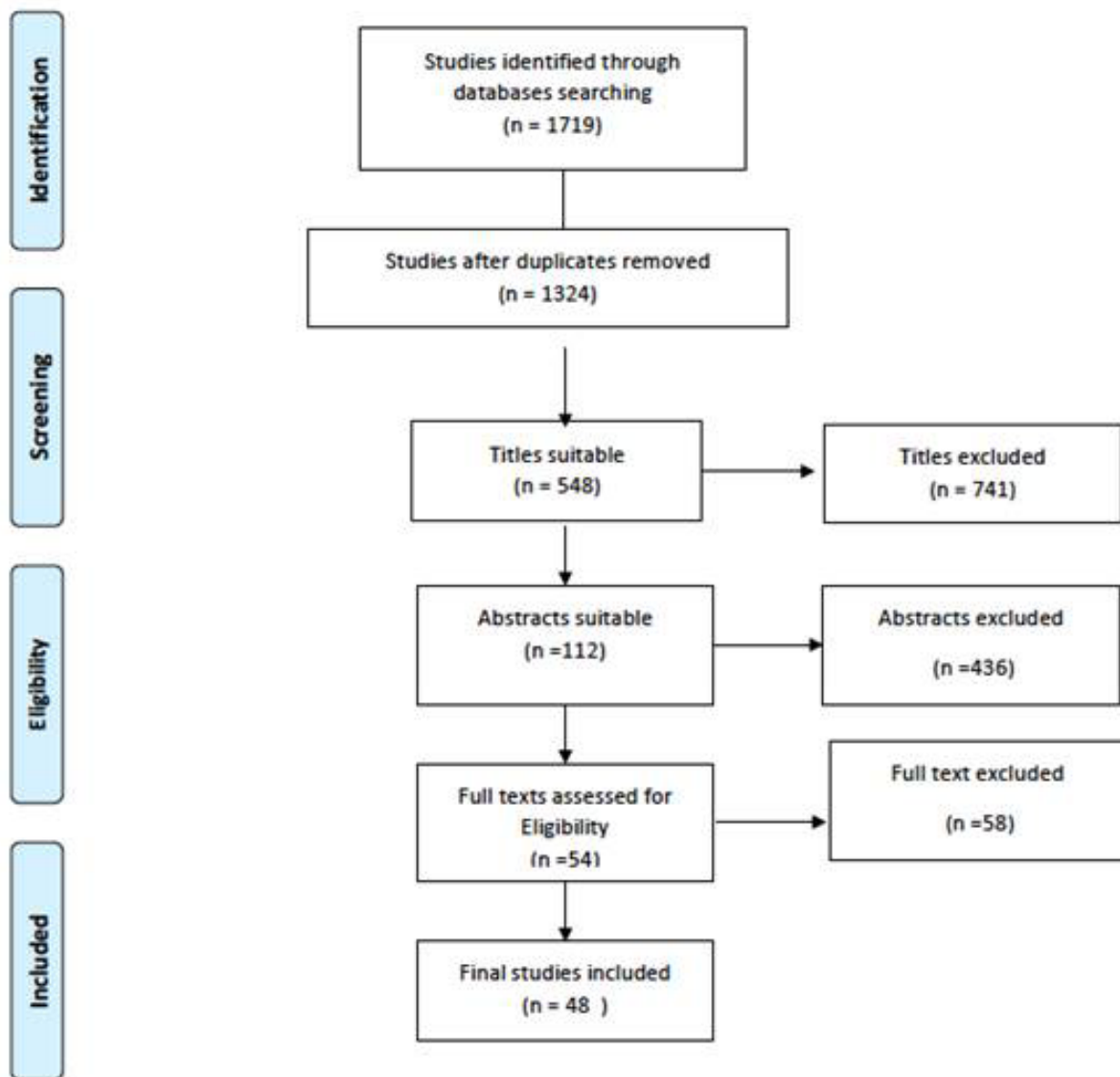


Figure 1. PRISMA flow diagram

After the literature searches, the authors provided a comprehensive summary document divided into 11 sections:

1. Reduction of dislocation
2. Timing of reduction
3. Unsuccessful reduction
4. Instability after reduction
5. CT timing
6. Skeletal traction
7. Pain management
8. Ultrasound exam to rule out vein thrombosis
9. Tranexamic acid in acetabular fracture
10. Antibiotic prophylactic protocols
11. Heterotopic ossification prophylaxis

This document was delivered in advance (15 days) to each expert participating at the CC and was considered as a starting point for the discussion. Two authors had the role of facilitator (MN) and chairman (AA) during the CC.

During the discussion, each document was initially presented by the facilitator (MN); followed by a plenary discussion guided by the chairman (AA) and finally approved by a vote.

The CC participants voted for each document, utilizing a Likert scale of 0–10, where 0 reflected complete disagreement, 5 neither agreement nor disagreement and 10 complete agreement. The discussions continued until a mean score of >7.5 was reached and the voting process enabled the chairman to interrupt the discussion if in his opinion final decision could not be reached.

The third and the sixth documents required respectively four and three separate discussions of subparts and voting rounds. During the discussions, the document was modified and then the final version was voted on. When reached, the consensus has been reached in all cases at the end of each discussion phase, where the majority of participants reached an agreement (i.e. when a mean score of >7.5 was reached). The voting results for each document are shown in Table 1. Later on, a second debate took place to reach a unanimous consent on the text of the present manuscript.

**Table 1.** Level of evidence and voting results for each question.

Question number	Level of Evidence	Voting score
1	III	10 +- 0
2	III	10 +- 0
3.1	IV	10 +- 0
3.2	IV	10 +- 0
3.3	IV	8+- 1
4	IV	5 +- 2
5	IV	10 +- 0
6.1	IV	10 +- 0
6.2	IV	10 +- 0
6.3	IV	10 +- 0
7	II	10 +- 0
8	II	10 +- 0
9	I	10 +- 0
10	II	10 +- 0
11	II	10 +- 0

### Section 1 Reduction of dislocation

Acetabular fractures occur in 70% of patients with traumatic hip dislocations. Anterior and posterior dislocations are present in respectively in 10 % and 90 % of acetabular fractures (4). Several authors demonstrated that reduction in the emergency department might reduce the risk of avascular necrosis (AVN) of femoral head and sciatic nerve injury.

*Recommendation: hip dislocations are orthopedic emergencies and require prompt reduction*

Footnote: all the authors agreed that acetabular fractures associated with central (medial) dislocation of the femoral head do not benefit from reduction

### Section 2 Timing of reduction

An increased length of time before reduction of a simple hip dislocation (without acetabular fracture) has been associated with an increased incidence of avascular necrosis (5, 6). The reason for the difference

between the effect of timing of reduction between a simple hip dislocation and hip dislocation with acetabular fracture is unclear (7, 8). Previous studies have documented an osteonecrosis rate of 4.8% in patients who were reduced in less than 6 hours, whereas a 52.9% rate was seen in hips reduced after 6 hours from injury (9). In contrast, it has also been hypothesized that the incidence of AVN is independent from the time of reduction, but is the consequence of the severity of the initial injury (8).

*Recommendation: reduce anterior or posterior hip dislocations as soon as possible*

### Section 3 Unsuccessful reduction

Roughly 2% to 15% of hip traumatic dislocations are irreducible. The reasons for irreducible dislocation include inadequate sedation, buttonholing through the joint capsule, and interposition of muscle or bone fragments (5, 10).

In these cases, several options are proposed in literature: the surgeon may repeat attempts at closed reductions, may perform an open reduction without definitive fixation, may use a skeletal traction or a bridging external fixator or he may consider open reduction and internal fixation as definitive treatment.

Repeating the attempt optimizing the technique may be the first choice and three suggestions have been made in literature. A deeper sedation of the patient may facilitate the reduction; reduction under control of image intensifier may be easier. The use of Schanz screw placed in the proximal femur may increase the force of the reduction manoeuvre.

Repeated attempts may damage the articular surface further because there is often a large exposed raw cancellous bone surface at the intact ilium, which may injure the cartilage on the femoral head further. Furthermore repeated attempts to reduce the hip can result in additional lesion to the articular surface of the femoral head. Furthermore repeated attempts at close reduction can lead to greater displacement of the acetabular fracture, or can cause more bleeding in case of associated pelvic injuries.

All those improvement of the reduction technique are not evidence based.

Even open reduction without fixation, skeletal traction and bridging external fixator can be recommended on the base of literature (5, 11).

Eventually, early definitive management with internal fixation has been advocated by some authors but this suggestion contrasts with the necessity of these fractures to be treated by selected centers experienced in acetabular fracture.

*Recommendation:*

*If hip reduction is not successful in the emergency department,*

1. *Surgeon may repeat attempts at closed reductions optimizing the technique (under general anesthesia, under image intensifier, using Schanz screw)*
2. *Open reduction without definitive fixation should be avoided*
3. *In case of unsuccessful reduction in the hip reduction skeletal traction is not useful*
4. *Surgeon can consider early definitive management with fixation and restoration of acetabular stability*

Footnote: the authors agreed that repeating reduction attempts present a low rate of complications and are necessary in complex cases.

### Section 4 Instability after reduction

After reduction of fracture-dislocation, the hip can be unstable. The most common reason is a large posterior wall fracture or a superior posterior wall fragment or both. In such cases, femoral skeletal traction or bridge external fixation have been proposed (12).

However, there isn't any evidence that support the use of these two techniques. Furthermore indications and contraindications of the external fixator for acetabular fractures have not yet been established in clinical practice (13).

*Recommendation: the authors were not able to find a consensus about treatment in case of severe instability after reduction. Otherwise the authors suggested treating these types of injuries as early as possible.*

### Section 5 Timing of CT scan

CT scan is without any doubt the gold standard for detecting fractures not visible at standard x-ray, especially in acetabular fracture (14).

The utility of the CT scan is to identify any posterior wall acetabular fractures, anterior or posterior or acetabular lip fractures, intra-articular loose bodies, or a nonconcentric reduction.

Several studies demonstrate the importance of CT imaging in the evaluation of patients requiring surgery for acetabular fracture (operative vs. non-operative; Open Reduction Internal Fixation (ORIF) vs. Total Hip Arthroplasty) (14). CT imaging is superior to plain radiographs in detecting significant findings (10).

In acetabular fracture dislocation, if possible, Judet views, inlet and outlet views of the pelvis, and a CT scan should precede the reduction procedure to identify concomitant bony injury and possible obstacles (bony fragments) to reduction (15).

Some authors (16, 17) suggested to perform a CT pre and post reduction to better study the presence of intrarticular fragments but those protocols presents also the advantages of either a major radiologic exposure either they require more time.

*Recommendation: preoperative CT scan is not mandatory before reduction*

### Section 6 Skeletal traction

Optimal preoperative management of acetabular fractures is a matter of debate and skeletal traction is still often performed in major orthopedic centers despite the lack of scientific value for this treatment. The goals (and the possible advantages) of this procedure are decreasing pain and avoiding further displacement of a fracture's fragments. Furthermore, this procedure may reduce intra-articular pressure thus preventing articular cartilage and femoral head necrosis (5, 7). Notwithstanding, Handoll et al conducted

an important meta-analysis showing how traction does not present better results in patients with fracture of the proximal femur compared to an abstention treatment (18). Up to date, no studies have ever evaluated the efficacy of pre-operative traction on acetabular fractures.

*Recommendation:*

1. *Skeletal traction is not necessary in all acetabular fracture*
2. *Traction is not necessary after reduction of a fracture dislocation*
3. *Traction may be helpful in case of poor pain control*

### Section 7 Pain management

To our knowledge, no evidence-based protocols or guidelines have been published so far, addressing effectiveness and safety issues of pain management in acetabular fractures (19).

*Recommendation: Pain management protocols for long bone fractures may be used also for acetabular fracture*

### Section 8 Ultrasound exam for Thromboembolism prophylaxis

Pelvic and acetabular fractures have been identified as risk factors for deep venous thrombosis (DVT) and thromboembolic complications. The incidence varies from 6 percent to as high as 54 percent (20, 21).

For major trauma patients, the American College of Chest Physicians (ACCP) authors recommend the routine use of Low-molecular-weight heparin (LMWH) (grade 1A) or the use of mechanical prophylaxis alone if LMWH is contraindicated (grade 1B).

They recommend against the routine use of duplex ultrasound for screening for asymptomatic DVT (grade 1B); however, screening of high-risk patients (including pelvic fractures) who had received suboptimal or no prophylaxis received a grade 1C recommendation.

They also recommend against the use of inferior vena cava (IVC) filters as a method of prophylaxis (grade 1C).

Early medicaments prophylaxis can prevent deep vein thrombosis after pelvic trauma (22). Delayed applications due to pelvic operations are risk factors. In such cases duplex scanning should be performed routinely and postoperative medicaments prophylaxis should be increased. (23, 24)

Prophylaxis for DVT is effective but there is no evidence-based proof that it is also effective in reducing the risk of fatal pulmonary embolism.

It is appropriate to consider screening the pelvic veins with duplex ultrasound, magnetic resonance venography or contrast enhanced CT scans on high-risk patients, and to delay surgery when findings are positive (24).

*Recommendation: preoperative ultrasound exam is not recommended in all acetabular fracture to prevent DVT and PE*

Footnote: the authors agreed that a standard DVT prophylaxis should be given to patient with acetabular fractures.

### Section 9 Tranexamic acid in acetabular fracture

Although there is a strong evidence for the use of antifibrinolytic drugs for acute traumatic injury, we are able to find only one recent paper studying their use in acetabular fractures:

the MATTERS study showed a lower mortality in the treatment group (patients who received tranexamic acid) despite patients being more severely injured. This benefit was not observed until after 48 h (25).

In long bone fractures, there was no evidence of an increased risk of vascular occlusive events. However, benefits were seen primarily if tranexamic acid was administered in the first 3 h after trauma and these agents are most effective within the first hour. In this early phase the risk of death due to bleeding can be decrease from 7.7 to 5.3 % (25).

Elements of their use that have yet to be fully defined included the dose regime, which lacked heterogeneity in the above studies, as well as the optimal timing of administration of agents (26).

The authors of the MATTERS study concluded that “the routine use of these agents with regard to pelvic and acetabular fracture surgery cannot be endorsed at this time” but “these agents remain a viable option in a multimodal approach to blood conservation in orthopedic surgery and there use may be considered on a case-specific basis by the operating surgeon and anesthetist” (27).

*Recommendation: tranexamic acid is useful for reduction of blood loss in acetabular fracture*

### Section 10 Antibiotic prophylactic protocols

Suzuki et al. study showed 5.2% surgical site infection (SSI) in patients following acetabular fracture open reduction and internal fixation (including 10 deep infections and 7 superficial infections). Staphylococcus aureus was the most common causative pathogens in 9 patients, and was Methicillin-resistant in 3 patients. Enterococcus faecalis was found in 6 patients, Staphylococcus epidermidis in 3 patients, and Pseudomonas aeruginosa and Enterobacter cloacae in 2 patients each (28).

Fourteen of 17 patients developed their infection within 4 weeks after the fixation.

In Faizan Iqbal et al. study, the prevalence of SSI following fixation of acetabular fractures is 5.6%, which is comparable to other studies. Mayo founded the infection rate after acetabular fracture fixation of 4%. The most common organism found in these studies was Staphylococcus aureus, which was consistent with prior findings followed by S Staphylococcus epidermidis (29).

Compared with placebo or no antibiotics prophylactic antibiotics (both single-dose preoperatively and multi-dose perioperatively) are more effective at reducing the risk of postoperative deep wound infections and reducing the risk of superficial infections, urinary tract infections and respiratory infection (moderate quality evidence).

Many different antimicrobials were studied (all active against Staphylococcus aureus). Aside from short-acting single-dose regimens, indirect and direct comparisons show similar effectiveness of single- and multiple-dose regimens.

Operative-day (less than 24 hours) compared with longer-duration multiple-dose antibiotic regimens of less than 24 hours' duration given on the day of operation and multiple-dose regimens in which antibiotics are given for more than 24 hours seem equally effective at reducing the risk of overall wound infections and deep wound infections in people having hip surgery (30).

*Recommendation: antibiotic prophylactic protocols for long bone fracture may be used for acetabular fracture*

### Section 11 Heterotopic ossification prophylaxis

The occurrence of heterotopic ossification has been reported in as many as 80% of patients with acetabular fractures fixed through a posterior approach. Well-established risk factors for the development of heterotopic ossification include posterior or extensile approaches to the acetabulum, T-type acetabular fractures, a high Injury Severity Score (ISS), a delay to surgery, a closed head injury, male sex, and trauma to the chest or abdomen (31, 32)

Two prophylactic modalities are accepted:  
anti-inflammatory drugs  
irradiation.

Especially in the elderly population treatment with anti-inflammatory drugs like indomethacin or ibuprofen might be associated with undesirable effects like gastritis, bleeding, or renal damage (32).

Radiation therapy has been shown to be effective in reducing the risk of developing heterotopic ossification after open reduction and internal fixation of the acetabulum.

In comparing preoperative radiation therapy to postoperative radiation therapy, there is no difference in the frequency and severity of heterotopic ossification for patients with acetabular fracture (33).

Although postoperative prophylaxis is recommended in acetabular fracture presenting one or more risk factors, up to date there is no evidence to support the use of preoperative heterotopic ossification prophylaxis in acetabular fractures.

*Recommendation: preoperative heterotopic ossification prophylaxis is not effective in acetabular fracture*

Footnote: all the authors agreed that heterotopic ossification prophylaxis is recommended after fixation.

### Conclusions

According to the consensus, the authors strongly suggest that anterior and posterior hip dislocation even in presence of acetabular fracture should be reduced as soon as possible. If unsuccessful, surgeon may repeat the attempts optimizing the technique (deeper anesthesia, Schanz screw, image intensifier). This consensus was not able to give suggestion about treatment in case of instability after dislocation reduction. According to the authors, preoperative CT scan is not mandatory before reduction and skeletal traction is not indicated in most of the acetabular fracture; standard pain and antibiotic prophylactic protocols for long bone fractures should be used; preoperative ultrasound exam is not recommended in all acetabular fracture; tranexamic acid should be preoperatively used while there is no indication for preoperative ossification prophylaxis.

**Abbreviations.** OC: Organizing Committee, CC: Consensus Conference, CT: Computed Tomography, IV: Intravenous, AVN: Avascular Necrosis, ORIF: Open Reduction Internal Fixation, DVT: Deep Venous Thrombosis, ACCP: American College of Chest Physicians, LMWH: Low-molecular-weight Heparin, IVC: Inferior Vena Cava, SSI: Surgical Site Infection, ISS: Injury Severity Score

**Conflicts of interest:** Each author declares that he or she has no commercial associations (e.g. consultancies, stock ownership, equity interest, patent/licensing arrangement etc.) that might pose a conflict of interest in connection with the submitted article.

**Authors' contribution:** AA study conception and design, bibliography analysis, manuscript writing and revision, supervision. MN, MA, FB, LBV, DC, AC, GC, MC, MC, MF, AFB, AF, FL, UM, MM, AP, GP, MO, FS, MST, DT, KZ, AM, GR, MC and SG manuscript conception, writing the manuscript and contribute with important scientific knowledge giving the final approval.



## References

- Candiani G, Colombo C, Daghini R, Magrini N, Mosconi P, Nonino F, Satolli R. The Methodological Manual – How to Organize a Consensus Conference. 2012 . Accessed at <http://www.snlg-iss.it>.
- Oxford Centre for Evidence-based Medicine. Levels of Evidence. 2009. Accessed at <http://www.cebm.net/ocebml-levels-of-evidence/>
- Moher D, Liberati A, Tetzlaff J, Altman DG, Group P. Preferred reporting items for systematic reviews and meta-analyses: the PRISMA Statement. *Open Med.* 2009;3:e123–30
- Holt GE, McCarty EC. Anterior hip dislocation with an associated vascular injury requiring amputation. *J Trauma* 2003;55(1):135–8.
- Kregor PJ, Templeman D. Associated injuries complicating the management of acetabular fractures. *Orthopedic clinics of north America.* 2002; 33:1.
- Epstein HC. Posterior fracture-dislocation of the hip: Long term follow-up. *J Bone Joint Surg Am* 1974; 56 (6):1103–27.
- Letournel E, Judet R. *Fractures of the Acetabulum.* New York, Springer, 1993.
- Matta JM. Fractures of the acetabulum: Accuracy of reduction and clinical results in patients managed operatively within three weeks after the injury. *J Bone Joint Surg Am.* 1996; 78:1632–45.
- Cash DJW, Nolan JF. Avascular necrosis of the femoral head 8 years after posterior hip dislocation. *Injury* 2007;38:865–7.
- Jaskolka DN, Di Primio GA, Sheikh AM, Schweitzer ME. CT of preoperative and postoperative acetabular fractures revisited. *J Comput Assist Tomogr.* 2014; 38(3):344–7.
- Halvorson JJ, Lamothe J, Martin CR, Grose A, Asprinio DE, Wellman D, Helfet DL. Combined Acetabulum and Pelvic Ring Injuries. *J Am Acad Orthop Surg* 2014;22:304–14.
- Lu-Yao GL, Keller RB, Littenberg B, Wennberg JE. Outcomes after displaced fractures of the femoral neck: A metaanalysis of one hundred and six published reports. *J Bone Joint Surg Am.* 1994; 76:15–25.
- Frank M, Dzupa V, Smejkal K, Baca V, Dedek T. Crossover external fixator for acetabular fractures: a cadaver study. *J Trauma Emerg Surg.* 2014; 40:601–606.
- Pagenkopf E, Grose A, Partal G, Helfet DL. Acetabular Fractures in the Elderly: Treatment Recommendations. *HSSJ.* 2006; 2: 161–71.
- Sanders S, Tejwani N, Egol KA. Traumatic Hip Dislocation. A Review. *Bulletin of the NYU Hospital for Joint Diseases.* 2010;68(2):91–6.
- Clegg TE, Roberts CS, Greene JW, Prather BA. Hip dislocations--epidemiology, treatment, and outcomes. *Injury.* 2010;41(4):329–34.
- Mitsionis GI, Lykissas MG, Motsis E, Mitsiou D, Gkiatas I, Xenakis TA, Beris AE. Surgical management of posterior hip dislocations associated with posterior wall acetabular fracture: a study with a minimum follow-up of 15 years. *J Orthop Trauma.* 2012 Aug;26(8):460–5.
- Handoll HH, Queally JM, Parker MJ. Pre-operative traction for hip fractures in adults. *Cochrane Database Syst Rev.* 2011;(12):CD000168.
- Dijkstra BM, Berben SA, van Dongen RT, Schoonhoven L. Review on pharmacological pain management in trauma patients in (pre-hospital) emergency medicine in the Netherlands. *Eur J Pain.* 2014 ;18(1):3–19.
- White RH, Zhou H, Romano PS. Incidence of symptomatic venous thromboembolism after different elective or urgent surgical procedures. *Thromb Haemost.* 2003;90:446–455.
- Montgomery KD, Potter HG, Helfet DL. The detection and management of proximal deep venous thrombosis in patients with acute acetabular fractures: a follow-up report. *J Orthop Trauma.* 1997;11:330–336.
- Slobogean GP, Lefaivre KA, Nicolaou S, O'Brien PJ. A systematic review of thromboprophylaxis for pelvic and acetabular fractures. *J Orthop Trauma.* 2009; 23 (5):379–84.
- Morgan SJ, Jeray KJ, Phieffer LS, Grigsby JH, Bosse MJ, Kellam JF. Attitudes of Orthopaedic Trauma Surgeons Regarding Current Controversies in the Management of Pelvic and Acetabular Fractures. *Journal of Orthopaedic Trauma.* 2001; 15 (7): 526–32.
- Böhme J1, Müller J, Fröhlich S, Tiemann AH, Josten C. Fatal risk thrombosis? A prospective study for the incidence of deep vein thrombosis in pelvic fractures. *Z Orthop Unfall.* 2009 ;147(3):293–7.
- Morrison JJ, Dubose JJ, Rasmussen TE, Midwinter MJ. Military application of tranexamic acid in trauma emergency resuscitation (MATTERs) study. *Arch Surg.* 2012; 147(2):113–19.
- R. P. Piggott, M. Leonard. Is there a role for antifibrinolytics in pelvic and acetabular fracture surgery? *Ir J Med Sci.* 2016; 185:29–34.
- Roberts I, Shakur H, Ker K, Coats T. Antifibrinolytic drugs for acute traumatic injury. *Cochrane Database Syst Rev.* 2012; (12):CD004896.
- Suzuki T, Morgan SJ, Smith WR, Stahel PF, Gillani SA, Hak DJ. Postoperative surgical site infection following acetabular fracture fixation. *Injury.* 2010 ;41(4):396–9.
- Iqbal F, Younus S, Asmatullah, Zia OB, Khan N. Surgical Site Infection Following Fixation of Acetabular Fractures. *Hip Pelvis.* 2017; 29(3): 176–81.
- Oliver D, Griffiths R, Roche J, Sahota O. Hip fracture. *BMJ Clin Evid.* 2007; 10: 1110 .
- Tornetta P. Displaced Acetabular Fractures: Indications for Operative and Nonoperative Management. *J of the American Academy of Orthopaedic Surgeons.* 2001; 9 (1): 18–28.
- Hanschen M, Pesch S, Huber-Wagner S, Biberthaler P. Management of acetabular fractures in the geriatric patient. *SICOT J.* 2017; 3: 37.

33. Archdeacon MT, D'Heurle M, Nemeth N, Budde B. Is Pre-operative Radiation Therapy as Effective as Postoperative Radiation Therapy for Heterotopic Ossification Prevention in Acetabular Fractures? *Clin Orthop Relat Res.* 2014; 472:3389–94.

---

**Correspondence:**

Received: 1 May 2020

Accepted: 30 May 2020

Alessandro Aprato

Viale 25 aprile 137 int 6 10133 Torino, Italy

E-mail: ale\_aprato@hotmail.com