

The Empty Nose Syndrome: a pragmatic classification in clinical practice

Desiderio Passali¹, Rosario La Rosa², Giulio Cesare Passali³, Giorgio Ciprandi⁴

¹Former President and Board Member, International Federation ORL Societies (IFOS), Rome, Italy; ²ENT Clinic, Casa di Cura Villalba, Bologna, Italy; ³ENT Department, University of Sacred Heart, Rome, Italy; ⁴Allergy Clinic, Casa di Cura Villa Montallegro, Genoa, Italy

To the Editor,

Empty Nose Syndrome (ENS) encompasses multiple pathological forms that are characterized by different anatomy and different clinical pictures. Eugene Kern and Monika Stenkvis initially coined the term ENS in 1994 as a rare but debilitating clinical syndrome that typically occurred after surgical therapy (1). The main symptom is a paradoxical perception of nasal obstruction, despite normal nasal patency (2). Other troublesome complaints include nasal crusting, dryness, nasal discharge, and facial pain (3). Patients with severe ENS may also experience bothered sleep, impaired mental concentration, and choking (4). Psychiatric symptoms may also occur until a suicide attempt (4) as well as neurological dysfunction (5).

From a pathophysiological point of view, ENS follows on from functional interventions on the nasal cavities sometimes performed with too much guilty aggression. Moreover, ENS could also be included in the umbrella definition of secondary atrophic rhinitis. Anyone of the procedures for reducing the turbinate volume, to alleviate nasal breathing obstruction, may induce the ENS, yielding and producing secondary atrophic rhinitis, which may not occur instantaneously but only materialize years following the initial surgical trauma.

The correct nasal physiology, mainly concerning the function of heating and moistening the inspired air, resides in the lower, middle, and upper turbinates fundamental elements whose conservation must always be considered indispensable. When the nasal physiology,

especially in the ventilatory function, is upset by irreversible hypertrophy of the turbinates, it is necessary to proceed with the intervention that must prefer, among the dozens of methods proposed in the literature, that or those useful for unclogging but the most conservative as possible at least respecting the mucosa.

Since anatomical and clinical pictures can be very different, there is the need to define a shared and scientifically-based common language for performing comparisons and statistics. Therefore, it seems to be appropriate to propose a classification of ENS that can, at least in general, differentiates post-surgical situations due to the different clinical pictures.

Here is our proposal; it derives from hundreds of interventions performed by us in a suitable, safe, and secure environment. This classification is based on endoscopic objectivity and considers five grades (with sub-grades) according to macroscopic features.

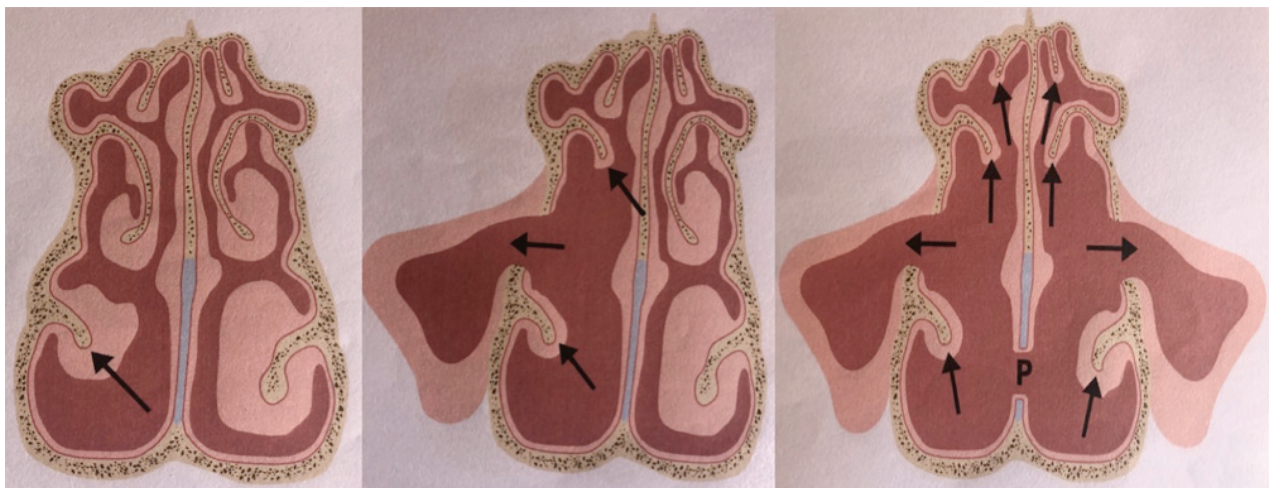
Table 1 shows different characteristics. Figure 1 describes the different grades according to the type of turbinate surgery.

Each picture can correspond to a symptom severity ranging from the annoying comes to be unbearable that can even indicate extreme solutions.

The diversity of symptom characteristics requires differentiation of the term Empty Nose Syndrome so far unable to fully define how important it is to know nor to define the border with the most common Atrophic Rhinitis of different origins. Every grade corresponds to different symptoms. In this regard, a study is ongoing to define the clinical features characterizing the different ENS grades.

Table 1. Classification of Empty Nose Syndrome based on grades

Grade	Characteristics
I A	Single-sided resection of the inferior turbinate
I B	Bilateral resection of the inferior turbinates
II A	Unilateral resection of the inferior and middle turbinates
II B	Bilateral resection of the inferior and middle turbinates
II C	Unilateral resection of the inferior and middle turbinates with ipsilateral meatotomy
II D	Bilateral resection of the inferior and middle turbinates with bilateral meatotomy
III A	Ipsilateral resection of all turbinates
III B	Bilateral resection of all turbinates
III C	Unilateral resection of all turbinates with ipsilateral meatotomy
III D	Bilateral resection of all turbinates with bilateral meatotomy
IV	Resection of all turbinates with the removal of mucosa
V	Resection of all turbinates with septum perforation

**Figure 1.** Left panel corresponding to grade I; middle panel corresponding to grade II; right panel corresponding to grades III-V. The arrows indicate the sites of surgical turbinate resection.

From a clinical point of view; it is clinically relevant to phenotyping patients with ENS to personalize the more appropriate treatment. Lubricants, moisturizing, cytoprotective agents could restore the perception of physiological breathing.

In conclusion, ENS is a complex disorder that challenges the rhinologist. Phenotyping patients could be a reasonable strategy in the workup and management of ENS.

Conflicts of interest: Each author declares that he or she has no commercial associations (e.g. consultancies, stock ownership, equity

interest, patent/licensing arrangement etc.) that might pose a conflict of interest in connection with the submitted article.

References

1. Scheithauer MO. Surgery of the turbinates and “empty nose” syndrome. *GMS Curr Top Otorhinolaryngology Head Neck Surg* 2010;9:Doc03
2. Tam YY, Lee TJ, Wu CC, et al. Clinical analysis of sub-mucosal Medpor implantation for empty nose syndrome. *Rhinology* 2014;52:35-40
3. Lee TJ, Fu CH, Wu CL, et al. Evaluation depression and anxiety in empty nose syndrome after surgical

4. Gill AS, Said M, Tollefson TT, Steele TO. Update on empty nose syndrome: disease mechanisms, diagnostic tools, and treatment strategies. *Curr Opin Otolaryngol Head Neck Surg* 2019;27:237-42
5. Li C, Farag AA, Maza G, et al. Investigation of the abnormal nasal aerodynamics and trigeminal functions among empty nose syndrome patients. *Int Forum Allergy Rhinol* 2018;8:444-52

Correspondence:

Received: 15 May 2020

Accepted: 18 May 2020

Giorgio Ciprandi

Allergy Clinic,

Casa di Cura Villa Montallegro,

Genoa, Italy

E-mail: gio.cip@libero.it