

C A S E R E P O R T

Endovascular treatment for restenosis of carotid venous bypass graft: a clinical case report

Alberto Bramucci¹, Claudio Bianchini Massoni¹, Roberto Menozzi², Alessandro Ucci¹, Enrico Epifani³, Antonio Freyrie¹

¹Vascular Surgery, Department of Medicine and Surgery, University of Parma, Parma, Italy; ²Interventional Neuroradiology, Emergency Care Department, University Hospital of Parma, Parma, Italy; ³Interventional Radiology, Diagnostic Department, University Hospital of Parma, Parma, Italy

Summary. *Background and aim:* Restenosis after open carotid surgery (OCS) represents an issue that experts are very often facing nowadays, both after carotid endoarterectomy (CEA) and carotid bypass (CB). Yet, even if from one side carotid artery stenting (CAS) is currently recommended by most guidelines as treatment of choice for carotid restenosis after CEA, on the other side little is known regarding the best treatment of restenosis after CB. This clinical case report is aimed to empathize the endovascular treatment as an effective therapeutic option for restenosis after OCS. *Methods:* A 75-year-old woman with severe comorbidities was admitted to our Unit for left carotid bypass graft restenosis. One year earlier, the patient had been treated with left carotid bypass grafting in saphenous vein for infectious complications occurred after CEA for symptomatic left carotid stenosis. The patient underwent a carotid Duplex ultrasonography scan (DUS) which showed a hemodynamically significant left carotid venous graft stenosis with peak systolic velocity of 315 cm/sec; in order to assess the grade of the stenosis a computed tomography angiography confirmed the presence of a significant narrowing of left carotid graft. A carotid artery angiography was performed after 20 days, reconfirming the presence of a significant left carotid graft stenosis and was successfully treated with 7x40mm self-expanding stent. *Results:* The patient had an uneventful post-procedural course and was discharged the day after. After six months, the patient underwent a carotid DUS in our outpatient clinic which confirmed the overall graft and stent patency. *Conclusion:* CAS represents a feasible therapeutic option for carotid restenosis in patients treated after CB. This clinical case demonstrates that CAS can be performed with acceptable risks and good early results. (www.actabiomedica.it)

Key words: Carotid restenosis [MeSH]; endovascular treatment [MeSH]; carotid artery stenting [MeSH], carotid bypass [MeSH].

Introduction

The carotid artery disease is estimated to affect almost 10% of the general population over seventy years old, causing 10% of all strokes (1). The open carotid surgery (OCS) through the years was widely accepted as a valid treatment of the carotid disease (2), yet it is appropriate to limit the scope of application to the carotid endoarterectomy (CEA) which represents

the first-line treatment according to the most recent guidelines (3). As far as OCS is concerned, carotid bypass (CB) could represent a safe and valid alternative to CEA for all conditions where CEA might be both hazardous and inadvisable, such as carotid restenosis, excessive wall thinning after endarterectomy, trauma and prosthetic patch infection (4-6). Furthermore, another issue which experts are facing very often is represented by the restenosis after OCS, both

after carotid endoarterectomy (CEA) and after carotid bypass (CB). From one side carotid artery stenting (CAS) is recommended by most guidelines as the preferred treatment for carotid restenosis after CEA, with a reported <3% of peri-procedural stroke risk (7,8), while on the other side little is known regarding the best treatment of restenosis after CB.

This clinical case report is aimed to clarify if CAS could represent an effective therapeutic option for restenosis after CB.

Case Report

A 75-year-old woman was admitted to our Unit for left carotid bypass graft asymptomatic restenosis. Her medical history, already affected by diabetes, chronic obstructive pulmonary disease, smoking habit and dyslipidemia (American Society of Anesthesiologists score 3), was significant for coronary artery disease (CAD) causing acute coronary syndrome (ACS) complicated by sudden cardiac arrest and treated with coronary angioplasty. Six years earlier the patient underwent CEA with Dacron patch angioplasty for symptomatic left carotid stenosis causing ischemic

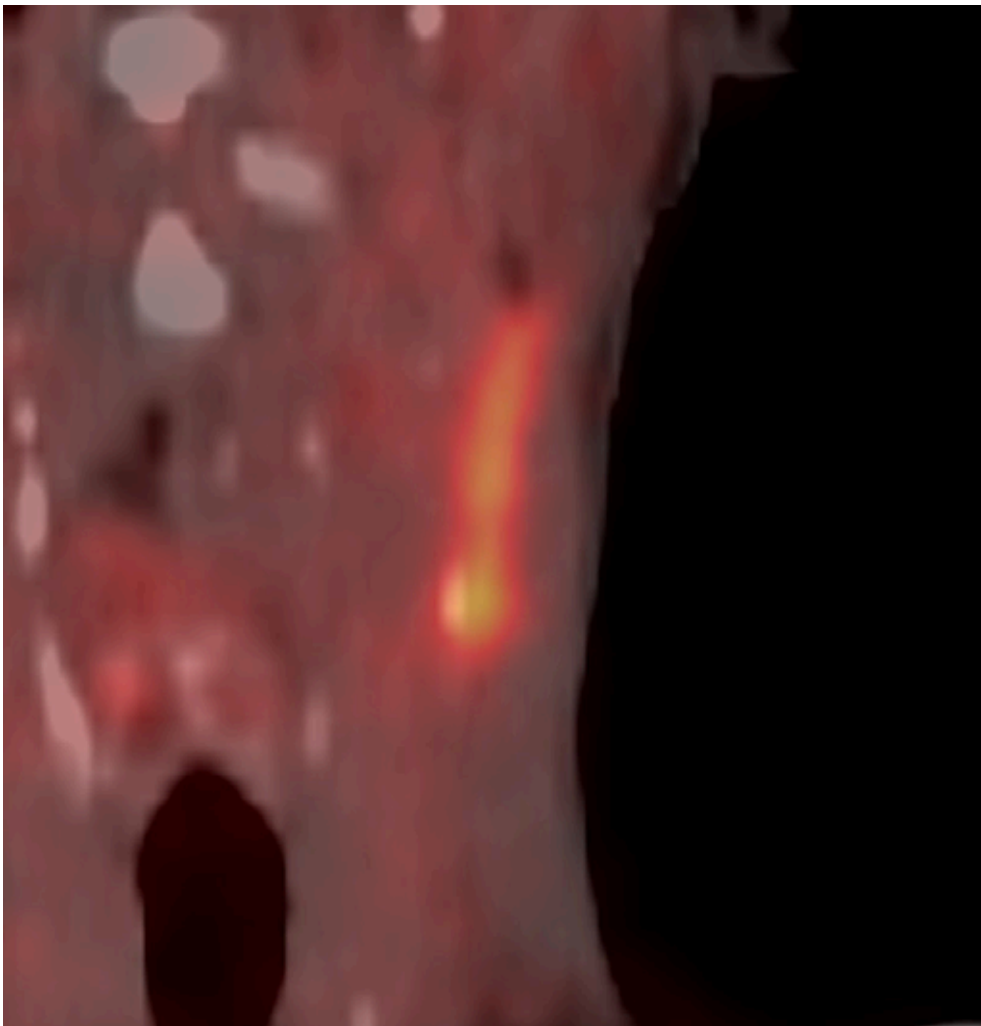


Figure 1. FGD-PET scan exam performed after two years from surgical repair with debridement, demonstrating tracer uptake in the fluid collection involved area from ICA to the middle segment of IJV, suggestive for patch infection.

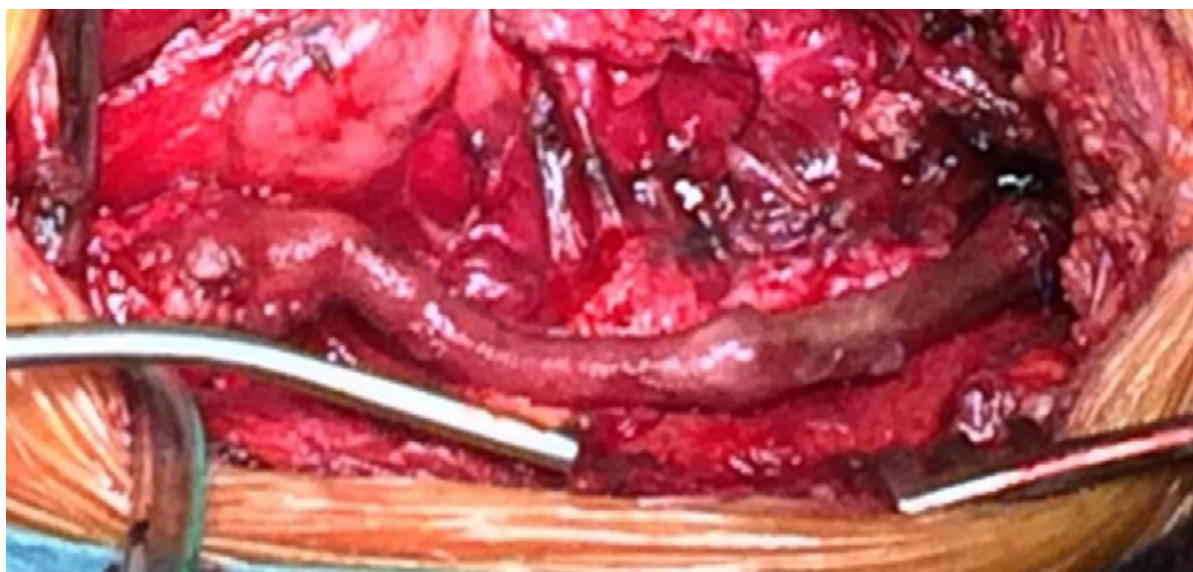


Figure 2. Intraoperative picture showing left carotid venous bypass grafting, GSV was harvested from right groin and a reversed venous bypass from common to internal carotid artery was anastomosed.

stroke involving ipsilateral frontal lobe and parietal lobe. During the OCS a Javid shunt was placed for cross-clamping intolerance. Afterwards the patient was discharged with single antiplatelet therapy with Acetylsalicylic acid (ASA) 100mg daily.

After three years from OCS, the patient developed a later cervical fistula (LCF) leading to suppuration and cellulitis, therefore surgical debridement was performed. During the surgical procedure, biptic samples were collected for microbiological cultures, all tested negative. Two years after surgical debridement, the LCF recurred. The patient firstly performed a computed tomography angiography (CTA), which showed a 15mm fluid collection along the first segment of the left internal carotid artery (ICA) toward to left internal jugular vein (IJV). In addition, a fluorodeoxyglucose positron emission tomography (FGD-PET) scan demonstrated a tracer uptake in the fluid collection, involving the area from ICA to the middle segment of IJV, suggestive for patch infection (Fig. 1). One month later, the patient underwent left carotid venous bypass grafting. Great saphenous vein (GSV) was harvested from right groin, and a reversed venous bypass was anastomosed from common to internal carotid artery (Fig. 2). The external carotid artery was ligated and a Javid shunt was used to avoid cross-clamping

intolerance. During the bypass grafting, biptic samples were collected for microbiological cultures, all tested negative. Further the patient received the indication to continue single antiplatelet therapy with ASA 100mg daily.

A carotid Duplex ultrasonography (DUS) performed after 1 year showed a hemodynamically significant venous graft stenosis with a peak systolic velocity of 315 cm/sec. To assess and characterize the grade of the stenosis the patient underwent a CTA which confirmed the presence of a 80% restenosis of the first segment of left carotid venous graft, just above the proximal anastomosis (Fig. 3A). For this reason, the indication of an endovascular treatment with bypass stenting was decided in a multidisciplinary committee and the patient 10 days before the procedure underwent pretreatment with dual antiplatelet therapy (DAPT) with ASA 100mg and Clopidogrel 75mg both daily.

Under local anesthesia and with a right retrograde femoral approach, a 7-F vascular sheath was positioned. The left common carotid artery was engaged in a telescopic technique with a dual coaxial system represented by a preloaded 7F Envoy MPD (Codman&Shurtleff, Raynham, MA, USA) guiding catheter over a 5F .038" 130mm JB2 Cook (Cook, Bloomington, IA,

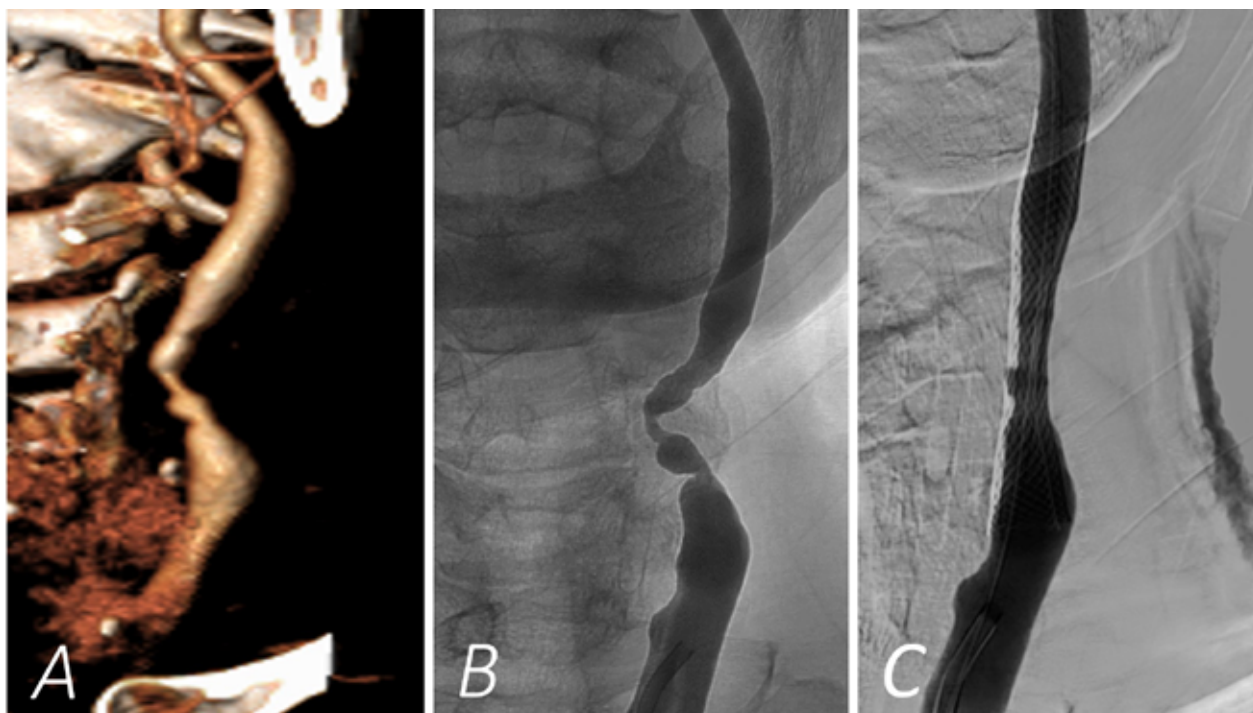


Figure 3. A) 1-year after left carotid venous bypass grafting CTA exam that confirmed the presence of a hemodynamically significant restenosis of the first segment of left carotid venous graft, just above the proximal anastomosis. B) A selective left carotid DSA was performed, confirming the presence of a left significant carotid graft stenosis. C) A post-procedural DSA, showing there were not residual stenosis, neither contrast collection outside the venous graft.

USA) diagnostic catheter and a .035" 180mm Terumo (Terumo, Shibuya-ku, Tokyo, Japan) floppy as a inner guidewire. A selective left carotid DSA was performed, confirming the presence of a left 80% carotid graft stenosis (Fig. 3B). The .035" 180mm floppy guidewire was exchanged for a .014" 182mm Choice PT (Boston Scientific, Natick, MA, USA) floppy guidewire, and the venous carotid graft was engaged without using proximal or distal embolic protection devices. Then a self-expandable 7x40mm Carotid Wallstent™ Monorail™ (Boston Scientific, Natick, MA, USA) system was positioned and deployed across the graft narrowing covering the proximal anastomosis. A monorail 5x20mm Viatrac 14 Plus (Abbott Laboratories, Chicago, IL, USA) balloon was used for post-dilatation. At the end, there was no residual stenosis and no contrast collection outside the venous graft (Fig. 3C). The patient had an uneventful post-procedural course and was discharged the day after. DAPT was extended up to 3 months after the procedure.

At 6-months carotid DUS displayed the graft and stent patency without the evidence of restenosis.

Discussion

To sum up this clinical case report, it is certainly clear how OCS complications management represents a demanding issue, but also the endovascular treatment of restenosis after OCS can be challenging in the same way.

As far as CB after primary CEA is concerned, there has been no randomized trial addressing the issue that bypass grafting has shown better outcomes than a repeated CEA. However, a retrospective analysis has reported that repeated CEA with patch and PTFE bypass grafts for repeated open surgical revascularization granted similar outcomes (9). In addition PTFE bypass grafting for repeated carotid revascularization have also shown a freedom from stroke of 93%

at 5 years (5). According to the available literature, the overall incidence of restenosis at 5 years after CB was 7% (5), compared to 4.4% shown by repeated CEA and with 13.5% after CAS (10). By contrast, an high rate of restenosis has been reported using GSV as conduit in CB (11, 12), with cumulative freedom from occlusion or recurrent stenosis >70% of 86% at 1 year, 83% at 3 years and 83% at 5 years (4).

Focusing our attention on clinical presentation of CB restenosis, in our experience the patient did not present any ipsilateral carotid territory symptoms before endovascular procedure. This clinical feature is comparable to what has been displayed by a multicentric retrospective study by Midy et al. (8). In this series the author reported that, out of a little subgroup of 28 patients treated with CAS for restenosis following bypass surgery, only 18% had complained symptoms at the time of the endovascular procedure. For this reason, the author, referring in turn to previous series (13, 14), voiced misgivings about the benefit of treating asymptomatic restenosis. Otherwise, our decision to proceed for endovascular treatment stemmed from the fact that the patient showed cross-clamping intolerance in both two previous surgical treatments. Thus, the patient's risk of having cerebrovascular suffering related to a hemodynamically significant venous graft restenosis would have been arguably high.

Another issue is represented by the short and midterm outcome. As described in our clinical case the patient previously performed two OCS in a row. Our choice to move for endovascular treatment was derived firstly by technical difficulties related to a redo OCS, mainly due to scar tissue increasing risk of cranial nerve injury and hindering blood vessel control, and secondly by patient's medical history. Even though CAD and previous ischemic stroke involving parietal and frontal lobe was present, the patient had an uneventful post-procedural and short-term clinical course. This result can be compared with series found in literature. In the specific, considering endovascular treatment for restenosis after OCS, the 30-day outcome was marked by the absence of ACS and 9 of the 23 deaths (39%) occurred during follow-up were due to cardiovascular events (8). However, as reported in this last series (8), the risk of anatomic events such as restenosis or occlusion after endovascular treatment,

was significantly higher after CB than CEA. This last finding is similar to what was reported in a previous study which have shown a 4% incidence of severe recurrent stenosis or occlusion within 18 months after vein grafting and with the lower complication rates after prosthetic grafting (4, 15). For this reason, the author emphasized the need of a DUS surveillance, particularly in patients who underwent carotid venous bypass grafting (8).

Conclusions

This clinical case confirmed how endovascular treatment with CAS for restenosis of carotid venous bypass graft can be a feasible and successful procedure in a short-term follow-up.

Conflict of Interest: Each author declares that he or she has no commercial associations (e.g., consultancies, stock ownership, equity interest, patent/licensing arrangement etc.) that might pose a conflict of interest in connection with the submitted article.

References

1. Abbott AL, Bladin CF, Levi CR, Chambers BR. What should we do with asymptomatic carotid stenosis? *Int J Stroke* 2007;2:27-39.
2. Setacci C, Argentero A, Cremonesi A, et al. Linee Guida SICVE-Patologia carotidea. *Italian J Vasc and Endovasc Surg* 2015;22:13-24.
3. Naylor AR, Ricco JB, De Borst GJ, et al. Editor's Choice - Management of Atherosclerotic Carotid and Vertebral Artery Disease: 2017 Clinical Practice Guidelines of the European Society for Vascular Surgery (ESVS). *Eur J Vasc Endovasc Surg* 2018;55:3-81.
4. Lauder C, Kelly A, Thompson MM, London NJM, Bell PRF, Naylor AR. Early and late outcome after carotid artery bypass grafting with saphenous vein. *J Vasc Surg* 2003;38:1025-30.
5. Illuminati G, Belmonte R, Schneider F, Pizzardi G, Calió FG, Ricco JB. Prosthetic bypass for restenosis after endarterectomy or stenting of the carotid artery. *J Vasc Surg* 2017;65:1664-72.
6. Naylor AR. Management of prosthetic patch infection after CEA. *J Cardiovasc Surg*. 2016;57:137-44
7. Lal BK. Recurrent carotid stenosis after CEA and CAS: diagnosis and management. *Semin Vasc Surg* 2007;20: 259-66.

8. Midy D, Berard X, Becquemin JP, et al. Multicentric retrospective study of endovascular treatment for restenosis after open carotid surgery. *Eur J Vasc Endovasc Surg* 2011;42:742-50.
9. Archie JP Jr. Reoperations for carotid artery stenosis: role of primary and secondary reconstructions. *J Vasc Surg* 2001;33: 495-503.
10. Tu J, Wang S, Huo Z, Wu R, Yao C, Wang S. Repeated carotid endarterectomy versus carotid artery stenting for patients with carotid restenosis after carotid endarterectomy: systematic review and meta-analysis. *Surgery* 2015;157:1166-73
11. Camiade C, Maher A, Ricco JB, et al. Carotid bypass with polytetrafluoro-ethylene grafts: a study of 110 consecutive patients. *J Vasc Surg* 2003;38:1031-1038.
12. Fokkema M, Vrijenhoek JE, Den Ruijter HM, Groenwald RH, Schermerhorn ML, Bots ML. Stenting versus endarterectomy for restenosis following prior ipsilateral carotid endarterectomy: an individual patient data meta-analysis. *Ann Surg* 2015;261:598-604.
13. Beebe HG. Scientific evidence demonstrating the safety of carotid angioplasty and stenting: do we enough to draw conclusions yet? *J Vasc Surg* 1998;27:788-90.
14. Healy DA, Zierler RE, Nicholls SC, et al. Long-term follow-up and clinical outcome of carotid restenosis. *J Vasc Surg* 1989;10:662-8.
15. Ricco JB, Marchand C, Neau JP, Marchand E, Cau J, Febrer G. Prosthetic carotid bypass grafts for atherosclerotic lesions: a prospective study of 198 consecutive cases. *Eur J Vasc Endovasc Surg* 2009;37:272-8

Correspondence:

Arrived: 1 May 2020

Accepted: 13 May 2020

Dr Alberto Bramucci

Vascular Surgery, Department of Medicine and Surgery,
University of Parma, Parma, Italy

Email: alberto.bramucci@gmail.com

Phone: +39 0521703575, +39 3385789335;

fax +39 0521703559