

Reinsertion of distal biceps ruptures with a single anterior approach: analysis of 14 cases using tension-slide technique and interference screw

Gian Mario Micheloni, Luigi Tarallo, Giuseppe Porcellini, Michele Novi, Fabio Catani

Department of Orthopedics and Traumatology, Policlinic of Modena, University of Modena and Reggio Emilia

Summary. *Background:* Several techniques of surgical repair of biceps tendon ruptures are described in literature. Cortical button repair have shown minimal loss of elbow flexion, supination and strength. In this retrospective study we report the outcomes in terms of elbow function and complications of tension-slide technique and interference screw. *Materials and methods:* 14 patients with complete distal biceps tendon rupture were included in the retrospective study and treated with the same tension-slide technique (BicepsButton® - Arthrex, Inc, Naples, Florida) evaluating the clinical and functional outcomes and the complication rate with a follow-up average of 18 months. *Results:* The flexion recovered compare to the healthy contralateral was 96% (min 115° - max 135°; average 128°), the extension was 97% (min: -2° - max 15°; average 4°), the supination was 90% (min 20° - max 90°; average 75°), the pronation was 95% (min 15° - max 90°; average 76°). The mean Disabilities of Arm, Shoulder and Hand (DASH) score was 8.1 ± 10.5 and Mayo Elbow Performance Score overall (MEPS) score was 97.6 ± 8.2 . Two patients had LABCN paresthesia, one case, treated 2 months after injury, had posterior interosseus nerve palsy. One patient had heterotopic ossification at the radiological examination without consequences for the clinical performances. No case of non-traumatic tendon re-rupture and no case of ROM deficiency > 20%. In all case the cortical button remains well positioned and no case of osteolysis were reported. *Conclusions:* Distal biceps tendon repair with BicepsButton® system seems to be a safe, reliable and reproducible technique providing excellent clinical, functional and radiological outcomes. Comparing with other techniques the BicepsButton® system has the advantages of the single approach procedures, the reduction of surgical time and risk of heterotopic ossifications. (www.actabiomedica.it)

Key words: distal biceps rupture, single approach, tension-slide technique, interference screw

Introduction

Distal biceps tendon ruptures are typical injuries of middle aged male. The incidence is 3% of all biceps injuries and 10% of all tendon injuries (1). The common mechanism of injury is an eccentric extension force loaded on an extended and supinated forearm. Most cases occur in dominant arm at the bicipital tuberosity on the radius (2,3). Pain and reduced strength in forearm supination is common at clinical examination. In rare cases conservative treatment is an option,

but this can lead to chronic arm pain and weakness of forearm supination (4-7). Surgical repair is considered the standard of care and several techniques involving variety of fixation methods and either 1 or 2-incision approaches have been reported in literature (8-12). A systematic review of repair techniques, reported lowest complication rate for cortical button repair (13) and other authors demonstrate the association with minimal loss of elbow flexion, supination strength and motion (comparing with contralateral side) (14). At our institution, after several years where we had used

a double incision approach for the treatment of distal biceps tendon ruptures, since two years, we prefer the new technique of repair with a single incision anterior approach, cortical button fixation and interference screw. The aim of the study is to assess the elbow function and complications of this surgical technique.

Materials and Methods

Fourteen patients (all male) with an average age of 42 (min. 35 - max. 73) and complete distal biceps tendon rupture (11 of 14 dominant arm) were operated between January 2018 and June 2019 by same senior surgeon and same tension-slide technique (BicepsButton® - Arthrex, Inc, Naples, Florida). All patients were physically active, 5 of them elite athletes.

Before surgery all patients had instrumental examination with ultrasound, 7 of 15 underwent magnetic resonance imaging (MRI).

The patients were clinically evaluated by measuring the degrees of pronation/supination, flexion/extension, documenting areas of hypoesthesia, neurological pain. The Mayo Elbow Performance score (MEPS) and Disabilities of Arm, Shoulder and Hand score (DASH) were also completed. Radiographs were taken at the review visit and were used to confirm appropriate placement of a cortical button against the far cortex of the radial tuberosity and to assess for heterotopic ossifications. After 90 days an ultrasound assessment was made for allows the return to sport activities. The average follow up was 18 months (range 6-24).

Surgical treatment

Each patient is positioned supine, the tourniquet is applied to the injured arm, the elbow is extended and forearm supinated to protect the posterior interosseous nerve (PIN). A minimally invasive, 3 cm transverse incision, over the antecubital fossa is performed. After dissection of the subcutaneous tissues, brachioradialis muscle belly was identified and reflected laterally to protect the motor branch of the radial nerve. The median nerve was identified and lateral antebrachial cutaneous nerve (LABCN) is carefully discerned from biceps brachii muscle to avoid secondary traction. In the distal portion a series of vein (the

so-called leash of Henry) and the recurrent branches of the radial artery are often coagulated or ligated. The ruptured tendon was mobilized and was followed proximally to the myotendinous junction under direct visualization (Figure 1). Light traction is performed to determine whether it could be reattached to the bicipital tuberosity. The distal degenerated portion of the biceps tendon is resected and 2-3 cm - Krackow sutures are placed in the tendon. The free suture ends were then passed through the cortical button. The radial tuberosity is palpated with the index finger and then using a blunt, curved hemostat that must be carefully inserted into the biceps channel. The radial tuberosity is cleaned up from the soft tissues and drilled bicortically, restoring the native footprint anatomy as suggested by recent literature (15) (Figures 2,3). Accurate washing and sucking are mandatory to prevent het-

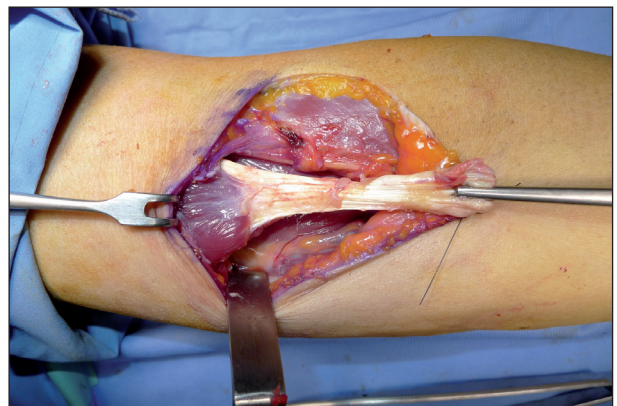


Figure 1. Injured biceps tendon mobilization and exposition.

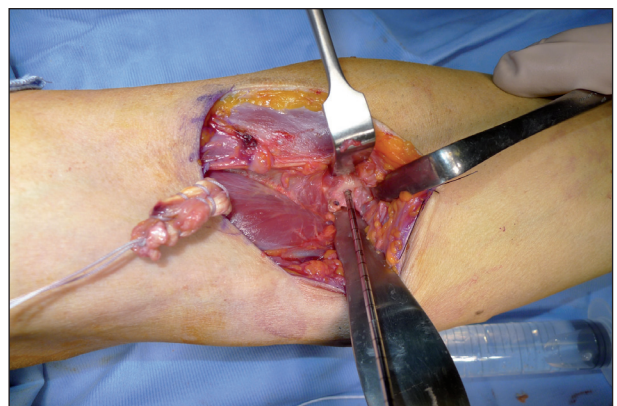


Figure 2. Drilling into the radial tuberosity at 90° to its longitudinal axis and 0 to 30° ulnar angle with patient's forearm in full supination (anatomic footprint).

erotropic ossification caused by bone debris spreading. The elbow was slightly flexed to relieve tension on the biceps tendon and maximally supinated. The cortical button was delivered through the drill-hole and past the posterior radial cortex (Figure 4). It was flipped blindly to secure the tendon on top of the tuberosity. Tension was placed on the traction suture to lock the button and then applied to the zip strand to pull the biceps tendon into the tunnel. An interference screw is positioned into the hole to ensure the final fixation and position (Figures 5-6). The elbow were immobilized using a sling at 90° of flexion and 45° of supination for one week. Passive rehabilitation in tolerated

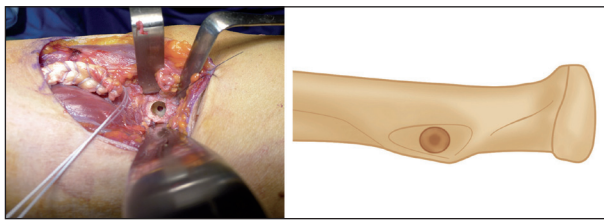


Figure 3. Bicortical radial holes and the end of the biceps tendon with suture (on the left).

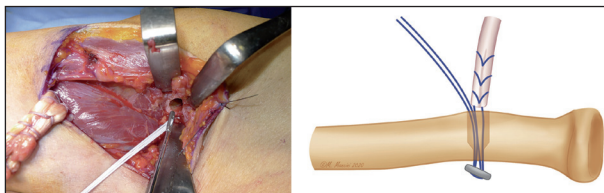


Figure 4. Delivering of the cortical button through the drill-holes.

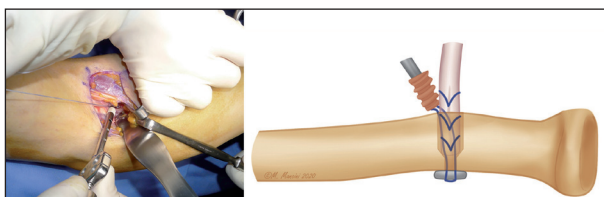


Figure 5. Tensioning of the tendon and cortical screw positioning into the hole.

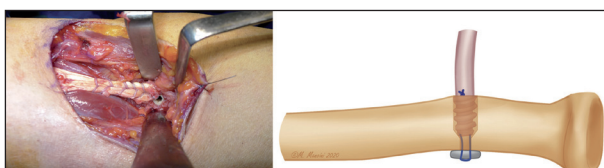

Figure 6. Final intraoperative result of the procedure.

range of motion was initiated after 10-15 days and muscle strengthening beginning after 6 weeks following our rehabilitation protocol (16).

Results

All patients were reviewed by an independent examiner. The flexion recovered compare to the healthy contralateral was 96% (min 115° - max 135°; average 128°), the extension was 97% (min: -2° - max 15°; average 4°), the supination was 90% (min 20° - max 90°; average 75°), the pronation was 95% (min 15° - max 90°; average 76°). The mean Disabilities of Arm, Shoulder and Hand score was 8.1 ± 10.5 and Mayo Elbow Performance Score overall score was 97.6 ± 8.2 .

All elite players, after measurements of flexion and supination strength (compared to contralateral), returned to play sport (RTP), 3 athletes returned to prior level of performance (RPP).

Two patients had LABCN paresthesia, one case, treated 2 months after injury, had posterior interosseus nerve palsy.

One patient had heterotopic ossification at the radiological examination without consequences for the clinical performances.

No case of non-traumatic tendon re-rupture and no case of ROM deficiency > 20%.

In all case the cortical button remains well positioned and no case of osteolysis were reported (Figure 7).

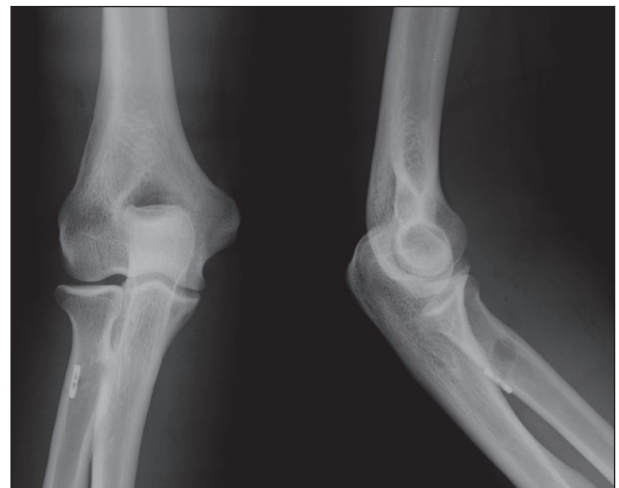


Figure 7. X-ray control at the final follow-up

Discussion

Distal portion of the biceps tendon lesion occurs typically in middle-aged male people and the arm is frequently the dominant as reported in our series (11 of 14). The superiority of surgical treatment compared to the conservative, in terms of functional recover, is largely demonstrated in literature (5,17). In our series all patients, also the oldest, had strong motivation to return to prior activities. For all these reasons in all cases we decided for surgical treatment.

Both one-incision approach (using suture anchors, endobutton or biotenodesis screw) and double-incision approach technique are reported in literature (18-22). No statistically significant differences were observed relative to ROM recovery (22), but advantages of the double-incision exposure is anatomic reinsertion on the radial tuberosity and consequent restoration of strength in supination and flexion (23). An advantage of one-incision technique is reducing the risk of radioulnar synostosis (24), in our series we reported only one case of this complication.

In our study the recovery of flexion and extension were 96% and 97% of those of the contralateral elbow respectively, outcomes comparable to available literature (14). These satisfactory outcomes are probably related to early mobilization in our rehabilitation program.

In our patient MEPS overall score was considered excellent and DASH overall score was not significantly different from the normative value for the general population.

Three elite athletes returned to prior levels of performance, with excellent flexion and supination strength measured at the end of follow-up. This may be attributable to the cortical button with interference screw surgical technique that allowed strong fixation between bone and biceps tendon.

The BicepsButton® (Arthrex, Inc, Naples, Florida) system as other endobutton-type devices allows a mini-open approach, the tendon is easily pulled into the transosseus tunnel (1) and the tension of the repair can be controlled (25,26). As reported in other studies we suggest drilling into the bone at the native footprint, 90° to its longitudinal axis and 0 to 30° ulnar angle with patient's forearm in full supination to increase

the margin of safety and strength of supination of the biceps tendon (1,15,27).

The intraosseus placement and fixation with interference screw allows better healing and early rehabilitation without recurrence of rupture. Failure of poly-L-lactide (PLLA) interference screws with significant osteolysis, tunnel enlargement and radius fractures have been reported (28). PEEK (Poly-ether ether-ketone) screws didn't show that complication in our series according to the recent literature (29).

We found two case (14,3%) of LABCN neuropraxia, a common complication in both single-incision and double-incision technique, probably due to a fibrosis near to the nerve or a significant traction on the retractors and this is in line with the systematic review of Watson et al (30). A case (7,1%) of PIN transient palsy, with complete recovery in 8 months is reported, may be due to delay of surgery more than one month (45 days) after the rupture. A meta-analysis conducted by Amin et al (31) reported an incidence of PIN palsy of 1,7% for anterior surgery higher than double-incision technique. Remains difficult to compare our rate with the literature on the basis of the small number of patients treated.

In our series we didn't observe case of re-rupture, probably the endobutton-type technique needs a higher energy absorbed before failure compared to suture anchor techniques, as reported in other studies (32-34). However the absence of re-rupture could be also a reflection of our smaller sample size.

Regarding cost/benefits analysis, although this system is clearly more expensive than others (i.e. suture anchors) we could consider and suggest this procedure, in particular in young player, on the basis of the satisfactory clinical outcomes and RPP rate.

The present study had several limitations: first of all the retrospective design but also the small sample size and the relatively short follow up. The strength of our study was that all patients were treated by the same surgeon and were analyzed by the same observer at the follow up.

Conclusions

Distal biceps tendon repair with BicepsButton® system seems to be a safe, reliable and reproducible

technique providing excellent clinical, functional and radiological outcomes. The strong stability of the surgical fixation with the combined biotenodesis screw and endobutton technique allows early rehabilitation without high rate of complications and re-ruptures. Comparing with other techniques the BicepsButton® system has the advantages of the single approach procedures, the reduction of surgical time and risk of heterotopic ossifications.

References

- Alech-Tournier F, Elkholti K, Locquet V, Ninou M, Gibert N, Pozzetto M, Breden F et al. Outcomes of distal biceps tendon reattachment using the ToggleLoc™ fixation device with ZipLoop™ technology with single mini-open technique. *Eur J Orthop Surg Traumatol* 2019;29(4):925-31.
- Morrey BF. The elbow and its disorders. Elsevier Health Sciences, New York (2009).
- Athwal GS. Management of elbow trauma, an issue of handclinics 31-4, E-Book. Elsevier Health Sciences, New York (2016).
- Morrey BF, Askew LJ, An KN, Dobyns JH. Rupture of the distal tendon of the biceps brachii. A biomechanical study. *J Bone Joint Surg Am* 1985;67(3):418-21.
- Baker BE, Bierwagen D. Rupture of the distal tendon of the biceps brachii. Operative versus non-operative treatment. *J Bone Joint Surg Am* 1985;67(3):414-7.
- Agins HJ, Chess JL, Hoekstra DV, Teitge RA. Rupture of the distal insertion of the biceps brachii tendon. *Clin Orthop Relat Res* 1988 Sep;234:34-8.
- Bell RH, Wiley WB, Noble JS, Kuczynski DJ. Repair of distal biceps brachii tendon ruptures. *J Shoulder Elbow Surg* 2000;9(3):223-6.
- Boyd HB, Anderson LD. A method for reinsertion of the distal biceps brachii tendon. *J Bone Joint Surg Am* 1961;43(7):1041-3.
- Barnes SJ, Coleman SG, Gilpin D. Repair of avulsed insertion of biceps. A new technique in four cases. *J Bone Joint Surg Br* 1993;75(6):938-9.
- Lintner S, Fischer T. Repair of the distal biceps tendon using suture anchors and an anterior approach. *Clin Orthop Relat Res* 1996;322:116-9.
- Sotereanos DG, Pierce TD, Varitimidis SE. A simplified method for repair of distal biceps tendon ruptures. *J Shoulder Elbow Surg* 2000;9(3):227-33.
- Bain GI, Prem H, Heptinstall RJ, Verhellen R, Paix D. Repair of distal biceps tendon rupture: a new technique using the Endobutton. *J Shoulder Elbow Surg* 2000;9(2):120-6.
- Watson JN, Moretti VM, Schwindel L, Hutchinson MR. Repair techniques for acute distal biceps tendon ruptures: a systematic review. *J Bone Joint Surg Am* 2014;96(24):2086-90.
- Huynh T, Leiter J, MacDonald PB, Dubberley J, Stranges G, Old J, Marsh J. Outcomes and Complications After Repair of Complete Distal Biceps Tendon Rupture with the Cortical Button Technique. *JBJS Open Access* 2019;4(3). pii: e0013.1-6.
- Bellringer SF, Phadnis J, Human T, Redmond CL, Bain GI. Biomechanical comparison of transosseous cortical button and footprint repair techniques for acute distal biceps tendon ruptures. *Shoulder Elbow* 2020;12(1):54-62.
- Porcellini G, Rotini R, Stignani Kantar S, Di Giacomo S. The elbow: principles of surgical treatment and rehabilitation. Springer 2018.
- Tarallo L, Lombardi M, Zambianchi F, Giorgini A, Catani F. Distal biceps tendon rupture: advantages and drawbacks of the anatomical reinsertion with a modified double incision approach. *BMC Musculoskelet Disord* 2018;19(1):364.
- Balabaud L, Ruiz C, Nonnenmacher J, Seynaeve P, Kehr P, Rapp E. Repair of distal biceps tendon ruptures using a suture anchor and an anterior approach. *Hand Surg Br* 2004;29(2):178-82.
- Citak M, Backhaus M, Seybold D, Suero EM, Schildhauer TA, Roetman B. Surgical repair of the distal biceps brachii tendon: a comparative study of three surgical fixation techniques. *Knee Surg Sports Traumatol Arthrosc* 2011;19(11):1936-41.
- Gupta RK, Bither N, Singh H, Kapoor S, Chhabra A, Garg S. Repair of the torn distal biceps tendon by endobutton fixation. *Indian J Orthop* 2012;46(1):71-6.
- Tarallo L, Zambianchi F, Mugnai R, Costanzini CA, Catani F. Distal biceps tendon rupture reconstruction using muscle-splitting double-incision approach. *World J Clin Cases* 2014;2(8):357-61.
- Christopher L Camp MD, et al. Single-incision technique for repair of distal biceps tendon avulsions with intramedullary cortical button. *Arthroscopy Techniques* 2016;5(2):303-7.
- Grewal R, Athwal GS, MacDermid JC, Faber KJ, Drosdowech DS, El-Hawary R, King GJ. Single versus double-incision technique for the repair of acute distal biceps tendon ruptures: a randomized clinical trial. *J Bone Joint Surg Am* 2012;94(13):1166-74.
- Greenberg JA, Fernandez JJ, Wang T, Turner C. EndoButton-assisted repair of distal biceps tendon ruptures. *J Shoulder Elbow Surg* 2003;12:484-490.
- DiRaimo MJ, Maney MD, Deitch JR. Distal biceps tendon repair using the toggle loc with zip loop. *Orthopedics* 2008;31:1201-1203.
- Kodde IF, Bekerom MPJ van den, Eygendaal DE. Reconstruction of distal biceps tendon ruptures with a cortical button. *Knee Surg Sports Traumatol Arthrosc* 2013;23(3):919-925.
- Lo EY, Li C-S, Van den Bogaerde JM. The effect of drill trajectory on proximity to the posterior interosseous nerve during cortical button distal biceps repair. *Arthroscopy* 2011;27:1048-1054.
- Potapov A, Laflamme YG, Gagnon S, Canet F, Rouleau DM. Progressive osteolysis of the radius after distal biceps

- tendon repair with the bioabsorbable screw. *J Shoulder Elbow Surg* 2011;20: 819-826.
29. Matthews EC, Brinsden MD, Murphy AJ, Guyver PM. The biotenodesis screw and endobutton technique for repair for acute distal biceps tendon rupture. *Clin Arch Bone Joint Dis* 2018;1:006.
30. Watson JN, Moretti VM, Schwindel L, Hutchinson MR. Repair techniques for acute distal biceps tendon ruptures: a systematic review. *J Bone Joint Surg Am* 2014; 96A(24):2086-90.
31. Amin NH, Volpi A, Sean Lynch T, Patel RM, Cerynik DL, Schickendantz MS, Jones MH. Complications of distal biceps tendon repair: A Meta-analysis of single-incision versus double-incision surgical technique. *Orthop J Sports Med* 2016;4(10):2325967116668137.
32. Spang JT, Weinhold PS, Karas SG. A biomechanical comparison of EndoButton versus suture anchor repair of distal biceps tendon injuries. *J Shoulder Elbow Surg* 2006;15:509-514.
33. Chavan PR, Duquin TR, Bisson LJ. Repair of the ruptured distal biceps tendon: a systematic review. *Am J Sports Med* 2008;36:1618-1624.
34. Mazzocca AD, Burton KJ, Romeo AA, Santangelo S, Adams DA, Arciero RA. Biomechanical evaluation of 4 techniques of distal biceps brachii tendon repair. *Am J Sports Med* 2007;35:252-258.

Received: 10 April 2020

Accepted: 10 May 2020

Correspondence:

Gian Mario Micheloni

Department of Orthopedics and Traumatology, Policlinic of Modena, University of Modena and Reggio Emilia

E-mail: gianmario.micheloni@libero.it