

C A S E R E P O R T

High renin hypertension in focal renal fibromuscular dysplasia: turn off of renin system angiotensin overactivation by renal angioplasty cured high blood pressure and quickly reversed myocardial hypertrophy

Simona Merla¹, Riccardo Simoni¹, Stefano Tedeschi¹, Massimiliano Ferrari¹, Giovanni Passeri¹, Carla Marcato², Enrico Epifani², Ignazio Semproni¹, Giulia Zini¹, Ignazio Verzicco¹, Pietro Coghi¹, Riccardo Volpi¹, Aderville Cabassi¹.

¹Clinica e Terapia Medica, Centro per lo Studio dell'Iperensione Arteriosa e delle malattie Cardiorenali, Dipartimento di Medicina e Chirurgia, Università di Parma; ²Unità di Radiologia Interventistica, Azienda Ospedaliera-Universitaria di Parma, Parma, Italy.

Abstract. *Background:* Fibromuscular dysplasia (FMD) is an idiopathic, non-atherosclerotic and non-inflammatory stenotic lesion of renal arteries causing renovascular hypertension up-regulating renin-angiotensin-aldosterone system. *Case report:* A 18-year-old man was referred to our Hypertension Center (Clinica e Terapia Medica) for the recent onset of hypertension, poorly controlled on calcium channel blockers, already associated to electrocardiographic and echocardiography signs of left ventricular hypertrophy and significant albuminuria (728 mg/24 h). An increased plasma renin activity (PRA), aldosterone level and a mild hypokalemia raised the suspicion of renovascular hypertension. Abdominal CT and MRI angiography showed mild kidneys asymmetry and a tubular stenosis of the right renal artery in its mid-distal portion close to renal hilum. Radionuclide renal scintigraphy documented a kidneys asymmetry of separated glomerular filtration rate. Renal FMD was diagnosed based on patient age and the absence of cardiovascular risk factors for atherosclerosis. Patient successfully underwent right renal angioplasty giving a rapid normalization of blood pressure levels without antihypertensive drugs. Plasma aldosterone and PRA rapidly normalized as well as serum potassium levels. Six months after angioplasty echocardiography showed a regression of left ventricular hypertrophy and the patient albumin urine excretion became normal (14 mg/24 h). *Conclusions:* FMD can cause renovascular hypertension associated to organ damage such myocardial hypertrophy and albuminuria through mechanisms dependent but also independent from blood pressure levels. Renal angioplasty turned off renin-angiotensin-aldosterone overactivity allowing the cure the hypertension and a surprisingly rapid reverse of myocardial hypertrophy and of excess of albumin urine excretion not only dependent on blood pressure normalization. (www.actabiomedica.it)

Key words: renovascular hypertension, fibromuscular dysplasia, renin-angiotensin-aldosterone system, myocardial hypertrophy, albumin urine excretion.

Introduction

Secondary hypertension, which indicates an underlying and potentially curable cause, accounts for 5% to 10% of the hypertensive population, but is

up to 20% in patients with severe hypertension (1,2). Renovascular hypertension is an important and curable cause of secondary hypertension, whose frequency accounts for less than 1% of cases of mild to moderate hypertension, while more prevalent in severe

hypertension (3,4). Renovascular hypertension arises from a critical renal artery stenosis which determines renal hypoperfusion and up-regulation of renin release in the affected kidney, followed by a rise in angiotensin II and a secondary aldosterone excess leading to vasoconstriction and urinary potassium excretion. Renal artery stenosis can be secondary to different causes: i) fibromuscular dysplasia (FMD) (10-20% of cases), ii) atherosclerosis of the renal artery (80-90%, especially in the elderly) and less frequently arteritis (e.g., Takayasu arteritis) (3). The prevalence of symptomatic FMD is about 0.4% and generally it affects females less than 50 years old (3,4). The most significant laboratory findings are high levels of plasma renin activity (PRA) and aldosterone, often associated with hypokalaemia. Diagnostic investigation starts and includes in increasing order of accuracy, non-invasive imaging tests such as renal Doppler vascular ultrasonography, computed tomographic (CT) angiography and/or contrast enhanced magnetic resonance imaging (MRI) angiography. When the clinical assessment of the patient allows to proceed with interventional revascularization strategies, the gold standard for diagnosis and treatment is invasive catheter-based angiography. FMD should always be suspected when the onset of arterial hypertension occurs at a young age. As described in our case report, FMD is a potentially remediable form of arterial hypertension thanks to renal percutaneous angioplasty which cures the hypertensive state by abolishing the stimulus underlying the hyperactivation of the renin angiotensin aldosterone system.

The beneficial effect of renal angioplasty in FMD in selected patients is not only limited to the cure of arterial hypertension due to the correction of high renin condition but also to its ability to rapidly induce the regression of hypertrophic heart disease. This represents an important target because the excessive activation of renin angiotensin system induces harmful effects on vascular and myocardial structure not only through systemic vasoconstriction but also through the direct effects on cardiomyocyte proliferation independent from blood pressure elevation. Left ventricular hypertrophy characterizes at least 30% of hypertensive patients (5) and is associated with a higher risk of cardiovascular morbidity and mortality: left ventricular hypertrophy regression correlates with a lower incidence of cardiovascular events (6).

Case Report

An 18-year-old man was referred to the Hypertension Center of the Azienda Ospedaliera-Universitaria di Parma for the recent onset of hypertension, already associated with electrocardiographic signs of left ventricular hypertrophy (see Fig. 1A), which was confirmed by transthoracic echocardiography (septal thickness 16 mm, posterior wall thickness 14 mm, diastolic left ventricle internal dimension 48 mm, grade II diastolic dysfunction, left atrium size 46 mm, ejection fraction 65%). Elevated blood pressure and cardiac hypertrophy were not present at his medical check-up, electrocardiographic record and heart ultrasound carried out 3 years earlier (as required in Italy to be allowed to play amateur sports). He had a family history for arterial hypertension; the patient denied eating liquorice, drinking alcohol, smoking, using abuse drugs, nasal decongestants or nonsteroidal anti-inflammatory drugs that may cause blood pressure to rise (7). Physical examination was unremarkable; abdominal bruit and peripheral edema were absent. His blood pressure was uncontrolled on amlodipine 10 mg/day (145/90 mm Hg). Heart rate was 84 bpm. Twenty-four-hour ambulatory blood pressure monitoring (ABPM) showed elevated day time systo-diastolic blood pressure values (mean 139 mm Hg SD 11, 86 mm Hg SD 10, respectively) with moderate variability and a nocturnal dipping pressure profile. His blood tests performed showed a normal renal function, a mild hypokalaemia (3.2 mEq/L) refractory to oral salt supplementation (KCl 600 mg twice a day), an increased plasma renin activity (PRA, 47.96 ng/ml/h, normal range 0.48-4.88, both tested in sitting position) and aldosterone level (60 ng/dl, normal range 3.8-31.3). A mild increase in twenty-four-hour urinary fractionated metanephrine (339 ug/24 h, normal values 64-302) and normetanephrine (613 ug/24 h normal values 162-528) was also observed whereas within the normal range was urinary cortisol excretion. Urinary excretion of albumin was significantly elevated (728 mg/24 h, normal values <30 mg/24h). The presence of pheochromocytoma was excluded after a negative radiolabelled metaiodobenzylguanidine (¹²³I-MIBG) scintigraphy. Autoimmunity screening was negative excluding an underlying vasculitis disease. The patient who had already performed a renal

ultrasound evaluation in an outpatient diagnostic facility outside our Hospital centre, showed a report that excluded renal masses, abnormality or asymmetry of the intraparenchymal vascular resistance index. But despite an apparent normality of the ultrasound test, the presence of high PRA values and plasma aldosterone levels posed a strong suspicion of renovascular hypertension which was further investigated. An abdominal CT scan was performed showing a kidneys asymmetry (mild reduction of the right kidney longitudinal diameter 11 cm versus left kidney 14 cm),

associated with a tubular stenosis of the right renal artery (1 mm of diameter) in its mid-distal portion at about 22 mm from the aortic origin in absence of peristenotic expansive masses (Fig. 2A). MRI angiography confirmed the focal distal narrowing of renal right artery (9 mm of length) close to the renal hilum upstream the vascular bifurcation (Fig. 2 B, C). A radionuclide renal scintigraphy was also performed and showed an asymmetry of glomerular filtration rate between the two kidneys: global glomerular filtration rate calculated with the Gates method was 99.5 ml/

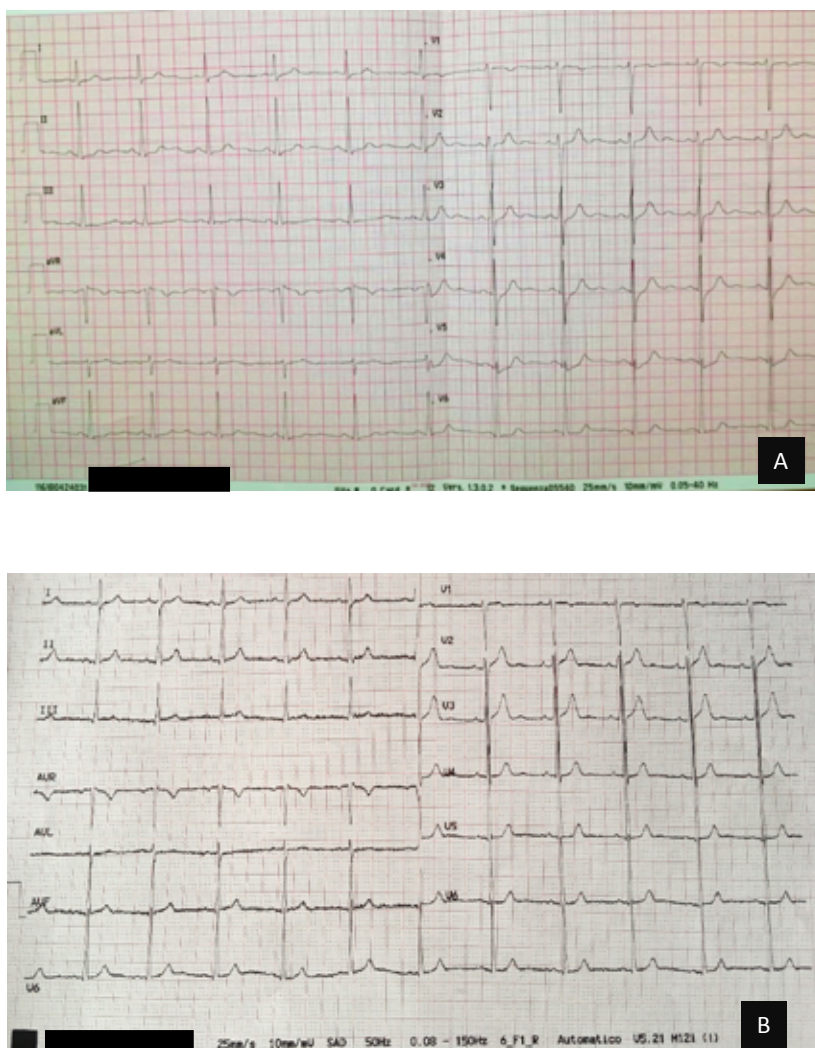


Figure 1. Patient's baseline electrocardiogram recording (A) showing sinus rhythm at 67 beats/minutes, with normal intervals and mean QRS axis. Sokolow-Lyon voltage criteria for left ventricular hypertrophy are met in the precordial leads (sum of S wave in V2 and R wave in V6 = 4,3 mV); six months after renal angioplasty, the electrocardiographic recording (B) showed a markedly attenuation of the left ventricular hypertrophy criteria (sum of S wave in V2 and R wave in V6 = 3,3 mV).

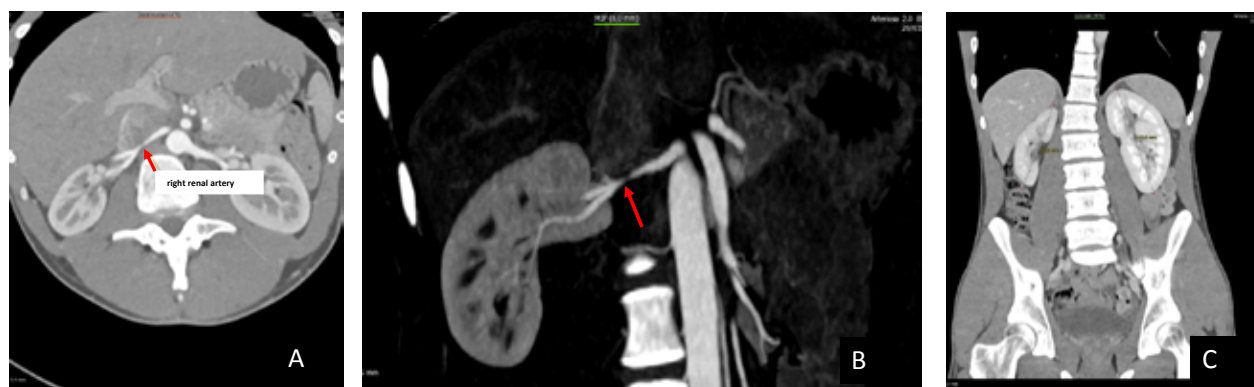

Figure 2. Upper abdominal CT Scan with contrast injection (A) and Magnetic Resonance Imaging (B) showing a narrowing of medium-distal portion of the right renal artery and (C) kidneys asymmetry.

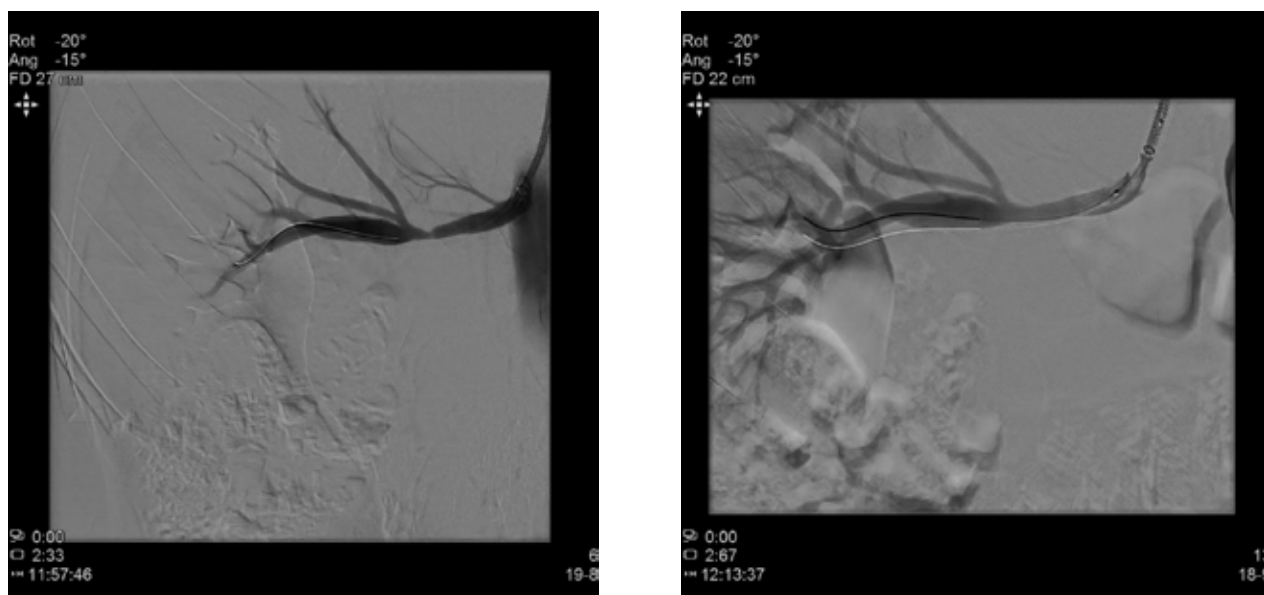


Figure 3. Right renal Angiography before (A) and after (B) balloon angioplasty.

min with a distribution of 68% for the left kidney and 32% for the right kidney. Because of i) the young age of the patient, ii) the absence of cardiovascular risk factors, iii) the location and iii) the imaging features of the right renal artery, the lesion was interpreted as a FMD. A possible involvement of other vascular beds was tested with vascular echo-color Doppler and brain MRI which excluded stenotic lesions of carotid and intracranial vessels as well as occult aneurysms or dissections. The patient underwent successful right renal angiography and balloon angioplasty (3.5x20 mm and

5x20 mm balloons were used on the right renal artery) (Fig. 3 A, B). The following day, plasma aldosterone (10.8 ng/dl) and PRA (3.08 ng/ml/h) in sitting position were normalized as well as serum potassium levels without oral supplementation. Antihypertensive drug therapy was reduced, and the patient was discharged from the hospital only with amlodipine (subsequently reduced to 2,5 mg/day) and an anti-platelet therapy (acetylsalicylic acid, 100 mg/die). Antihypertensive therapy was then stopped because the patient was normotensive without pharmacological treatment.

At two follow-up visits (after 1 and 6 months from angioplasty) the patient was normotensive, with normal serum potassium levels. Two subsequent echocolor Doppler ultrasounds did not show re-stenosis of distal portion of right renal artery. Six months later, the electrocardiographic recording showed a markedly attenuation of the classic alterations typical of left ventricular hypertrophy (Fig. 1B). At the 6-month visit, the cardiac ultrasound measurements of septal thickness, LV diastolic dimension, posterior wall thickness, left atrial area, were all significantly reduced, while the ejection fraction remained unchanged (septal thickness 11.9 mm, posterior wall thickness 9.6 mm, diastolic left ventricle internal dimension 50.4 mm, filling pattern indicative of normal diastolic function, left atrium size 35 mm, ejection fraction 65%); albumin urinary excretion was normalized (14 mg/24 h).

Discussion

This is an interesting case of a young male affected by focal right renal artery FMD with renovascular hypertension and associated myocardial hypertrophy whose blood pressure levels are quickly normalized and whose hypertrophy rapidly regressed in a very short period of time after renal angioplasty. As reported in a recent Consensus Document, renal FMD is defined as an idiopathic, non-atherosclerotic and non-inflammatory lesion affecting the muscular wall of renal arteries, characterized by abnormal cell proliferation and distortion of vascular architecture, that can cause renovascular hypertension with a marked up-regulation of the renin-angiotensin-aldosterone system (8). There are several points of discussion that emerge from our clinical case. The first point, pathophysiological, partially expected but which surprised us for the rapidity of cardiac hypertrophy regression, concerns the marked activation of the renin-angiotensin system as a main actor able through different mechanisms (increase of peripheral vascular constriction, rise of oxygen and nitrogen free radicals generation, impaired nitric oxide availability, sympathetic stimulation, sodium and water retention and an increase in urinary potassium excretion, vascular smooth muscle cell remodelling, sodium and water retention and increase in urinary potassium

excretion, cardio-myocytes remodelling and hypertrophy) (9-13) to cause high blood pressure (even if not at high degree of hypertension) and the development of myocardial hypertrophy (9,11). A complex relationship between moderate blood pressure rise and the development of myocardial hypertrophy emphasizes the role of the renin-angiotensin pathway as a main promoter of increased ventricular mass and diastolic dysfunction in our clinical case. What is surprising in our case is the rapidity of the regression of cardiac hypertrophy and the resolution of the severe diastolic dysfunction previously observed, once the excess of PRA has been corrected through renal angioplasty. Several studies reported that angioplasty of atherosclerotic renal artery stenosis represents an independent predictor for myocardial hypertrophy regression by a mechanism involving the reduction of renin-angiotensin-aldosterone system activation (14-18). But as observed through the various studies there are at least four important factors to consider as determinants of the degree of hypertrophy regression from partial reduction of left ventricular mass to complete normalization of wall thickness and diastolic function after renal angioplasty: i) age of the patient, ii) type of vascular lesion causing renal artery stenosis (atherosclerotic, inflammatory or due to FMD), iii) blood pressure levels, iv) length of the follow-up (3, 6, 9, 12, 24 months). Generally, in the clinical setting of an essential hypertensive patient, a temporal association between arterial hypertension grading and myocardial hypertrophy degree is known where the longer the duration and the higher the blood pressure levels, the greater the amount of myocardial hypertrophy observed (6). However, there are clinical observations supporting the concept that myocardial hypertrophy development not always parallels the degree and the duration of hypertension, indicating that high renin levels (and therefore angiotensin II and aldosterone generation) per se can independently from blood pressure levels determine an increase in myocardial mass (11,19). In our case, not only the 6-month echocardiographic re-evaluation but also the electrocardiographic recording showed a reversal of left ventricular hypertrophy signs.

The second point of discussion concerns the approach to a patient showing high renin hypertension

associated with elevated aldosterone levels and hypokalaemia. All these features can suggest the presence of renovascular hypertension. The classic sign on clinical examination of the patient of the abdominal bruit with a diastolic component and a lateralization towards renal areas was absent. However, the abdominal bruit should raise the suspicion of the presence of renal artery stenosis, although less than forty percent of patients with renovascular hypertension reveal this clinical sign. Furthermore, even if the PRA test is essential in the initial workup of a hypertensive patient with hypokalaemia and can help in differentiating between primary and secondary aldosterone excess, it has limitations in the diagnosis of renovascular hypertension. In fact, high levels of PRA are not found in all patients with renovascular hypertension but rather only in 50 to 80 percent of those confirmed upon renal angiogram. The elevation of PRA can be temporary and noticeable in the initial phases of renovascular hypertension and subsequently suppressed by volume expansion due to excess of secondary aldosterone or by bilateral renal arterial disease or by increased oral sodium intake.

Therefore, also PRA must always be evaluated and interpreted together with the other clinical, diagnostic laboratory and instrumental information.

Concerning the accuracy of the plasma radioimmuno-metric measurement of renin activity (PRA) or the chemiluminescent assays for measuring the concentration of direct active renin (DR), for about a decade there has been discussion on which of the two methods is the best, the easiest to use and to apply in the clinical patient testing. Fifteen years ago, two publications started to promote the precision and the accuracy of DR measurement and the saving of labour time and costs over the traditional measurement of PRA (20,21). PRA represents an indirect measure of renin that uses an enzyme-kinetic assay, which measures the rate of generation of angiotensin I from its substrate angiotensinogen. PRA is closely dependent upon the concentration of plasma angiotensinogen; DR measurement have the theoretical advantage over PRA of the independence from angiotensinogen concentration. Therefore, in clinical situations where low angiotensinogen is reported, such as in heart failure, PRA can result in lower values. Conversely, during pregnancy

or in women taking oral contraceptive pills, high circulating angiotensinogen levels result in higher PRA values. In addition to angiotensinogen concentration, PRA measurements are influenced by other factors including incubation conditions, pH values and low inter-laboratory reproducibility. In general, there is a good correlation between DR and PRA except at lower PRA levels. The PRA method is definitely cumbersome to perform. DR assay is faster, simpler and with better reproducibility and therefore will progressively replace PRA in circulating renin determination (2).

In addition to the discussion related to the correct interpretation of laboratory data, imaging studies are mandatory to support the diagnosis of renovascular hypertension as happened in our clinical case (8,22).

Currently, the renal angiogram is fundamental in the classification of FMD even if histological classification was used until a few years ago.

Unlike in adults and elderly patients where the genesis of renovascular hypertension is generally linked to an atherosclerotic renal artery stenosis, in young people renal artery stenosis can be of non-inflammatory and dysplastic origin such as in FMD patients or can be inflammatory such as in Takayasu arteritis patient (mean age of onset around 30 years and less than one in seven patients with this diagnosis is over 45 years of age) (8,23). In contrast to the atherosclerotic lesions that affect the proximal portion of the renal artery, FMD usually occurs in the middle or distal portion and often involves renal artery main branches (24). FMD can determine chronic ischemia resulting in a dimensional reduction of the kidneys but rarely leads to renal failure. It is rare to find a significant alteration of the renal function unless there are ongoing complications such as renal arterial dissection or in the case of bilateral stenosis (23). Although FMD can potentially involve any artery of small and medium size, it most commonly affects the renal and carotid arteries. Renal arterial lesions may concern the intima, media or perimedial layers of the vessel wall (8). The traditional histological classification of FMD describes three types: a) medial FMD, characterized by a homogeneous elastic sleeve arranged around an intact internal lamina (85% of cases); b) periarterial FMD described by an excess of tissue at the junction between media and adventitia (10% of cases); c) intimal FMD, characterized by an

irregular rearrangement of mesenchymal cells (5% of cases) (3). All these alterations lead to tortuosity of the artery or stenosis and predispose to dissection or aneurysms (4). But nowadays the angiographic classification of FMD is more widely used in practice than those based on histological alterations and distinguish among multifocal, tubular, and focal types (24). The multifocal type is the most frequent and appears as a succession of stenosis and narrow aneurysmal areas that evoke the image of a "string of beads"; its histological correlate is often the medial dysplasia and is more frequent in women (25). The tubular type consists of a single stenosis of more than 1 cm in length, while the focal type is associated with a single stenosis of less than 1 cm in length. The latter two forms are considered a unique entity under the name of "focal" (3) and are more frequent in male as in our case.

As mentioned above, imaging tests are necessary when the laboratory findings are suggestive of FMD. The renal artery Duplex Doppler ultrasonography could be considered the initial test, however both sensitivity and specificity, being between 75-85% and 70-92% respectively, are not sufficiently convincing to establish or exclude a FMD diagnosis (26-28). In a meta-analysis of 24 studies examining the sensitivity of ultrasound as a non-invasive method to investigate renal artery stenosis, only 4 showed a sensitivity greater than 90% (28). Ten to twenty percent of cases can show false negative results as occurred in our case: the reason of this low accuracy can be attributed to poor visualization of the entire artery, especially when FMD is distal, to the operator inexperience or

or, and it is not our case, when the patient is obese (29). For these reasons, experts recommend to refer the patient to a highly experienced centre (8). CT angiography and contrast enhanced MRI angiography are more effective than ultrasound for the detection of lesions of the middle and distal portion of renal artery. Both imaging tests offer sensitivity and specificity above 90%.

The gold standard is renal arteriography which allows the diagnostic confirmation and the therapeutic procedures. In this regard, the management of renovascular hypertension due to FMD can be medical, endovascular or surgical. In our case report the treatment has been the percutaneous renal angioplasty that

is emerging as the treatment of choice. This treatment allowed the cure of high blood pressure, the normalization of the hypokalaemia and the regression of myocardial hypertrophy. Renal artery stenting is generally not indicated in the setting of FMD and is limited to treat complications (dissection, pseudoaneurism, rupture). The rate of cure of high blood pressure is high in younger patient and those with a shorter duration of hypertension (30).

But when the medical option is followed, the traditional antihypertensive drugs are used, giving preference to the ACE inhibitors and Sartans in the absence of specific contraindications. If necessary, it is possible to use calcium channel blockers or beta blockers also in combination because arterial hypertension could be resistant to single medical therapy. The follow up of patients that underwent angioplasty requires regular blood pressure and serum electrolytes monitoring and at least annual imaging assessments of the affected artery bed, particularly within the 2 years following the procedure.

Conclusions

The finding of sustained high blood pressure levels in young adults should incite the clinician to suspect a form of secondary hypertension and in particular to pay attention to possible hemodynamic relevant renal artery stenosis secondary to FMD leading to high renin renovascular hypertension. The presence of significant organ damage as in our clinical case (myocardial hypertrophy and pathologic urinary albumin excretion) disproportionate to the degree of arterial hypertension and therefore not always related to blood pressure levels should alert clinician to possible mechanisms that induce directly organ damage such as the activation of renin angiotensin system. Such an overactivity should be promptly turned off and corrected by renal angioplasty. When renovascular hypertension is related to a focal FMD, the high blood pressure has not lasted too long and the patient is young, high are the probabilities for arterial hypertension to be cured thanks to renal angioplasty and also for the associated myocardial hypertrophy and for the excess of urine albumin excretion to be reversed in a relative rapid period of time.

Conflict of interest: Each author declares that she or he has no commercial associations (e.g. consultancies, stock ownership, equity interest, patent/licensing arrangement etc.) that might pose a conflict of interest in connection with the submitted article

References

- Carey RM, Calhoun DA, Bakris GL, et al.; American Heart Association Professional/Public Education and Publications Committee of the Council on Hypertension; Council on Cardiovascular and Stroke Nursing; Council on Clinical Cardiology; Council on Genomic and Precision Medicine; Council on Peripheral Vascular Disease; Council on Quality of Care and Outcomes Research; and Stroke Council. Resistant Hypertension: Detection, Evaluation, and Management: A Scientific Statement From the American Heart Association. *Hypertension*. 2018;72(5):e53-e90.
- Pedicini V, Gennaro N, Muglia R, et al. Renin-dependent hypertension cured with percutaneous radiofrequency ablation. *J Hypertens*. 2019;37(3):653-656.
- Plouin PF, Perdu J, La Batide-Alanore A, Boutouyrie P, Gimenez-Roqueplo AP, Jeunemaitre X. Fibromuscular Dysplasia. *Orphanet J Rare Dis* 2007; 2:28.
- Di Monaco S, Lengelé JP, Heenaye S, et al. Prevalence and characteristics of renal artery fibromuscular dysplasia in hypertensive women below 50 years old. *Eur J Clin Invest* 2019; 49:e13166
- Pelà G, Bruschi G, Cavatorta A, Manca C, Cabassi A, Borghetti A. Doppler tissue echocardiography: myocardial wall motion velocities in essential hypertension. *Eur J Echocardiogr*. 2001;2(2):108-17
- Agabiti-Rosei E, Muesan ML. Prognostic significance of left ventricular hypertrophy regression. *Adv Exp Med Biol*. 1997; 432:199-205.
- Cabassi A, Tedeschi S, Perlini S, et al. Non-steroidal anti-inflammatory drug effects on renal and cardiovascular function: from physiology to clinical practice. *Eur J Prev Cardiol*. 2019 :2047487319848105. doi: 10.1177/2047487319848105.
- Gornik HL, Persu A, Adlam D, et al. First International Consensus on the diagnosis and management of fibromuscular dysplasia. *Vasc Med* 2019; 24(2): 164-189.
- Kurdi M, Booz GW. New take on the role of angiotensin II in cardiac hypertrophy and fibrosis. *Hypertension*. 2011;57(6):1034-8.
- Cabassi A, Bouchard JF, Dumont EC, et al. Effect of antioxidant treatments on nitrate tolerance development in normotensive and hypertensive rats. *J Hypertens*. 2000;18(2):187-96.
- Cabassi A, Dancelli S, Pattoneri P, et al. Characterization of myocardial hypertrophy in prehypertensive spontaneously hypertensive rats: interaction between adrenergic and nitrosative pathways. *J Hypertens*. 2007;25(8):1719-30.
- Higashi Y, Sasaki S, Nakagawa K, Matsuura H, Oshima T, Chayama K. Endothelial function and oxidative stress in renovascular hypertension. *N Engl J Med*. 2002;346(25): 1954-62).
- Cabassi A, Binno SM, Tedeschi S, et al. Low serum ferroxidase I activity is associated with mortality in heart failure and related to both peroxynitrite-induced cysteine oxidation and tyrosine nitration of ceruloplasmin. *Circ Res*. 2014;114(11):1723-32.
- Zeller T, Rastan A, Schwarzwälder U, et al. Regression of left ventricular hypertrophy following stenting of renal artery stenosis. *J Endovasc Ther*. 2007;14(2):189-97.
- Lekston A1, Niklewski T, Gasior M, et al. Effects of short- and long-term efficacy of percutaneous transluminal renal angioplasty with or without intravascular brachytherapy on regression of left ventricular hypertrophy in patients with renovascular hypertension. *Pol Arch Med Wewn*. 2009;119(4):211-8.
- Rzeznik D, Przewlocki T, Kablak-Ziembicka A, et al. Effect of renal artery revascularization on left ventricular hypertrophy, diastolic function, blood pressure, and the one-year outcome. *J Vasc Surg*. 2011;53(3):692-7.
- Cuspidi C, Dell'Oro R, Sala C, et al. Renal artery stenosis and left ventricular hypertrophy: an updated review and meta-analysis of echocardiographic studies. *J Hypertens*. 2017;35(12):2339-2345.
- Symonides B, Chodakowska J, Januszewicz A, et al. Effects of the correction of renal artery stenosis on blood pressure, renal function and left ventricular morphology. *Blood Press*. 1999;8(3):141-50.
- Yamori Y, Mori C, Nishio T, et al. Cardiac hypertrophy in early hypertension. *Am J Cardiol* 1979; 44:964-969.
- Unger N, Lopez Schmidt I, Pitt C, et al. Comparison of active renin concentration and plasma renin activity for the diagnosis of primary hyperaldosteronism in patients with an adrenal mass. *Eur J Endocrinol* 2004; 150:517-23.
- Hartman D, Sagnella GA, Chesters CA, Macgregor GA. Direct renin assay and plasma renin activity assay compared. *Clin Chem* 2004;50: 2159-61.
- Herrmann SM, Textor SC. Renovascular Hypertension. *Endocrinol Metab Clin North Am*. 2019;48 (4):765-778.
- Chaudhry MA, Latif F. Takayasu's arteritis and its role in causing renal artery stenosis. *Am J Med Sci*. 2013;346(4):314-8.
- Kincaid OW, Davis GD, Hallermann FJ, Hunt JC. Fibromuscular dysplasia of the renal arteries. Arteriographic features, classification, and observations on natural history of the disease. *Am J Roentgenol Radium Ther Nucl Med*. 1968;104(2):271-82
- Lassiter FD. The string-of-beads sign. *Radiology*. 1998;206(2):437-8.
- Hansen KJ, Tribble RW, Reavis SW, et al. Renal duplex sonography: evaluation of clinical utility. *J Vasc Surg* 1990; 12: 227-236.
- Williams GJ, Macaskill P, Chan SF, et al. Comparative accuracy of renal duplex sonographic parameters in the diagnosis

- of renal artery stenosis: paired and unpaired analysis. *Am J Roentgenol* 2007; 188: 798–811.
28. Vasbinder GB, Nelemans PJ, Kessels AG, Kroon AA, de Leeuw PW, van Engelshoven JM. Diagnostic tests for renal artery stenosis in patients suspected of having renovascular hypertension: a meta-analysis. *Ann Intern Med* 2001; 135(6) 401–411.
29. Rountas C, Vlychou M, Vassiou K, et al. Imaging Modalities for Renal Artery Stenosis in Suspected Renovascular Hypertension: Prospective Intraindividual Comparison of Color Doppler US, CT Angiography, GD-Enhanced MR Angiography, and Digital Subtraction Angiography- *Ren Fail* 2007; 29(3): 295–302.
30. Trinquart L, Mounier-Vehier C, Sapoval M, Gagnon N, Plouin PF. Efficacy of revascularization for renal artery stenosis caused by fibromuscular dysplasia: a systematic review and metaanalysis. *Hypertension* 2010; 56: 525–32.

Correspondence:

Received: March 1, 2020

Accepted: March 3, 2020

Prof. Aderville Cabassi.

Centro per lo Studio dell'Ipertensione Arteriosa e delle malattie Cardiorenali (Affiliate with the Società Italiana dell'Ipertensione Arteriosa), Clinica e Terapia Medica, Department of Medicine and Surgery, DIMEC University of Parma, Via Gramsci 14, 43126 Parma, Italy.

Phone: +39 0521 703084

Email: aderville.cabassi@unipr.it