

## C A S E R E P O R T

# Blocking screw augmentation to treat delayed union of proximal tibial shaft fracture after locked IM nailing

Alberto Ferreli,<sup>1</sup> Daniela Nonne,<sup>1</sup> Angelo Russo,<sup>1</sup> Giuseppe Dessì,<sup>1</sup> Giuseppe Marongiu<sup>2</sup>

<sup>1</sup> Division of Orthopaedics and Traumatology, Brotzu Hospital, Cagliari, Sardinia, Italy

<sup>2</sup> Orthopedic and Trauma Clinic, Ospedale Marino, Department of Surgical Sciences, University of Cagliari, Cagliari, Italy

**Summary.** *Cases:* We present the cases of two adult male patients with painfully delayed union of proximal tibia diaphyseal fracture after intramedullary nailing. Patients underwent to nail dynamization and Poller blocking screw augmentation at 3 and 5 month, respectively, after the index surgery. Both patients were pain-free after the surgery and bone-union were radiographically evident after 3 months. At 12-month follow-up, patients returned to their previous activities. *Conclusions:* Although nail dynamization is the choice treatment to obtain fracture compression for delayed union of tibial shaft fractures, augmentation with Poller blocking screw could provide additional mechanical stiffness in unstable supra-isthmic shaft fractures of the tibia and favour bone union. ([www.actabiomedica.it](http://www.actabiomedica.it))

**Keywords:** Poller screw, blocking screw, nonunion, delayed union, tibial fracture, Intamedullary nailing, fracture augmentation

## Introduction

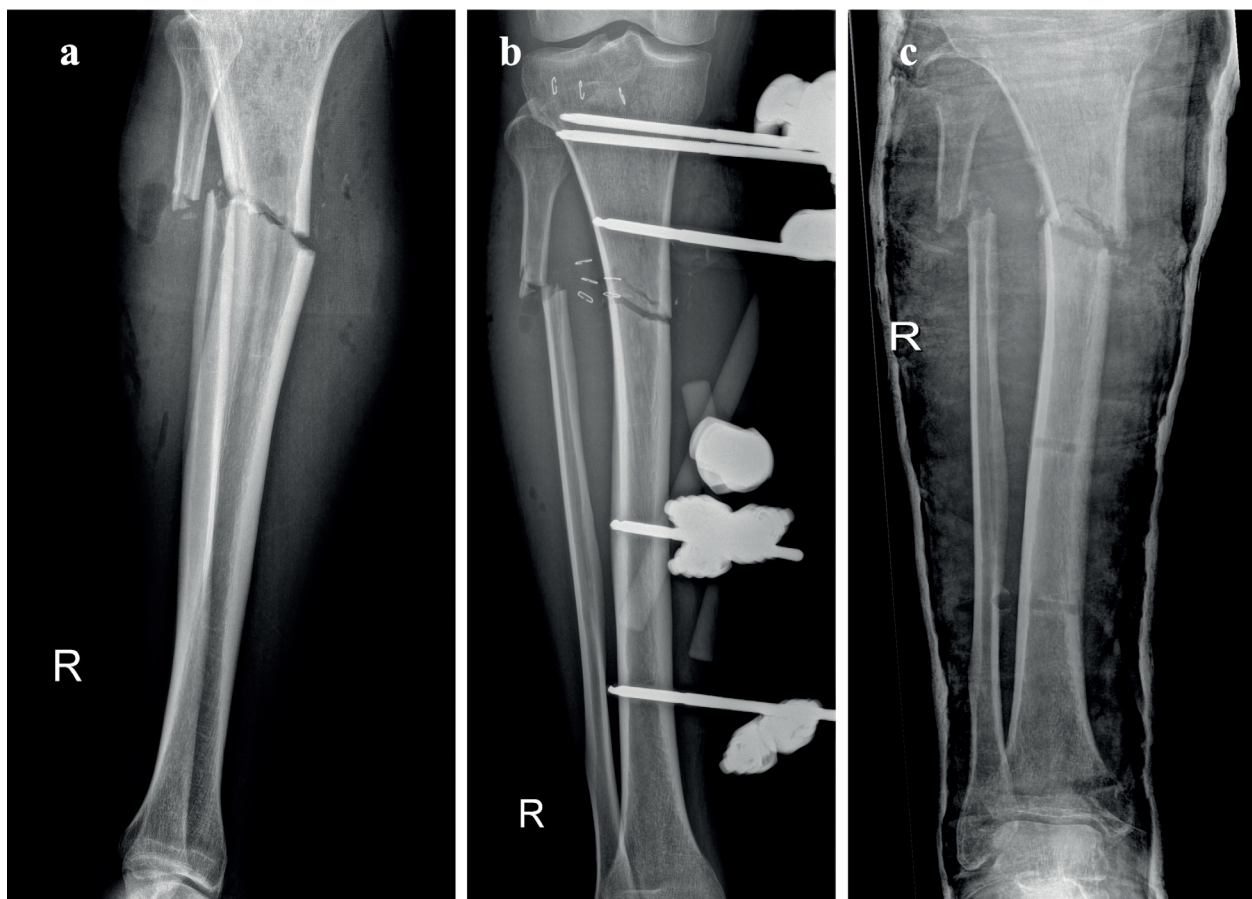
Intramedullary nailing (IMN) is considered the treatment of choice for diaphyseal tibia fractures (1). The reported risk of nonunion after nailing in tibial shaft fracture is 0 - 5.5% (2,3). A major risk factor for tibial nonunion is the fracture location, most commonly involving the area proximally or distally to the isthmus (2). In this area the expanding diaphysis going to the metaphysis increases the width of the intramedullary canal and consequently the contact between the nail and the inside cortex decreases(4). The local instability of the construct with residual movement at the fracture site can eventually result into an impaired bone union process.

Nail dynamization, exchange nailing and augmentation plating have been proposed as possible solution for nonunion treatment, particularly for hypertrophic

nonunion, aiming to obtain mechanical stability of the fracture and enhance the rigidity of the construct (5).

In case of delayed union less invasive and less time consuming procedures, such as nail dynamization, are more likely indicated(6). The underlying principle of dynamization is based on the enhancement of micro-movements at the fracture gap resulting in bone healing stimulation. In fractures of the proximal or distal 1/3 tibial diaphysis, which are typically unstable, nail dynamization did not often provide the desired effect of fracture compression (7). Particularly in more complex fracture patterns such as multi-fragmentary, wedge or oblique fractures, fracture compression could lead to loss of reduction resulting in further sliding, rotation or angulation of the proximal or distal fragment(3).

We speculated that positioning a blocking Poller screw, slightly medial or lateral to the nail, could “aug-



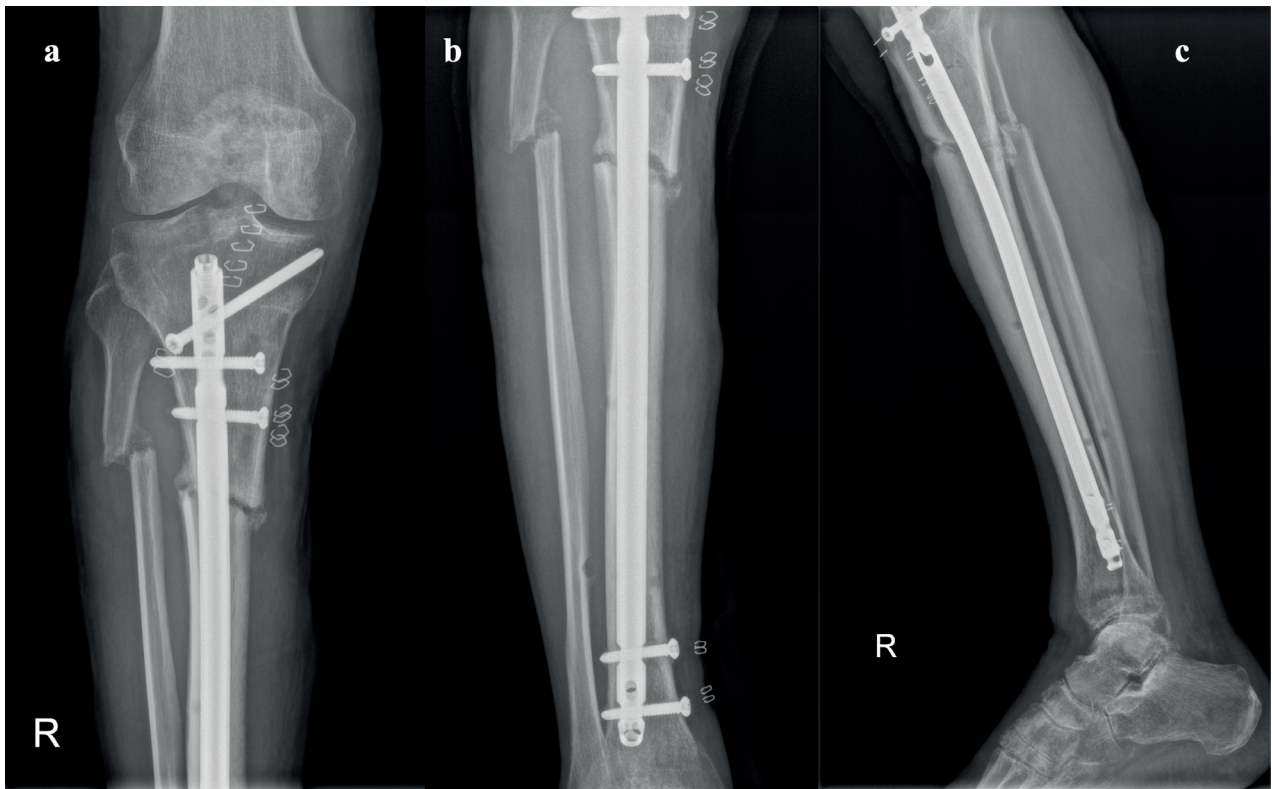
**Figure 1.** a) Only one x-ray view of the tibia was performed in E.R, showing the open fracture of the proximal 1/3 tibia shaft; b) then an External fixator was placed; c) X-rays after removal of the external fixator and application of a temporary splint.

ment” the fracture in case of delayed unions of supra- or infra- isthmic fractures, by reducing the width of the medullary cavity, increasing the stiffness of the construct and therefore limiting the movement of the proximal or distal fragment. Here we describe two cases of a delayed union of the proximal third of the tibial diaphysis successfully treated with the insertion of a blocking poller screw. The patients were informed that data concerning their cases would be submitted for publication, and provided consent.

### Case report #1

A 49-years old man was admitted to our department on January 2017 for open tibia shaft fracture due to high-energy road accident. Fracture was classified

as Gustilo grade III B and an oblique fracture ( $> 30^\circ$ ) 42A2 of the proximal 1/3 of the tibial diaphysis according to Arbeitsgemeinschaft für Osteosynthesefragen/Orthopaedic Trauma Association (AO/OTA) classification (Fig. 1a). Five hours after the injury, the patient received damage control surgery for the open tibia fracture with an external fixator (Fig. 1b). After two months, the external fixator was removed and a temporary splint was applied (Fig. 1c). Skin wound completely healed and no signs of infection were present. White cells count, high erythrocyte sedimentation rate (ESR) and C-reactive protein (CRP) were normal. After 40 days, the patient was readmitted to our Department and underwent to closed reduction and locked IMN of the tibial shaft fracture (Fig. 2). Both static and dynamic screws were placed and the nail was locked in a static configuration.



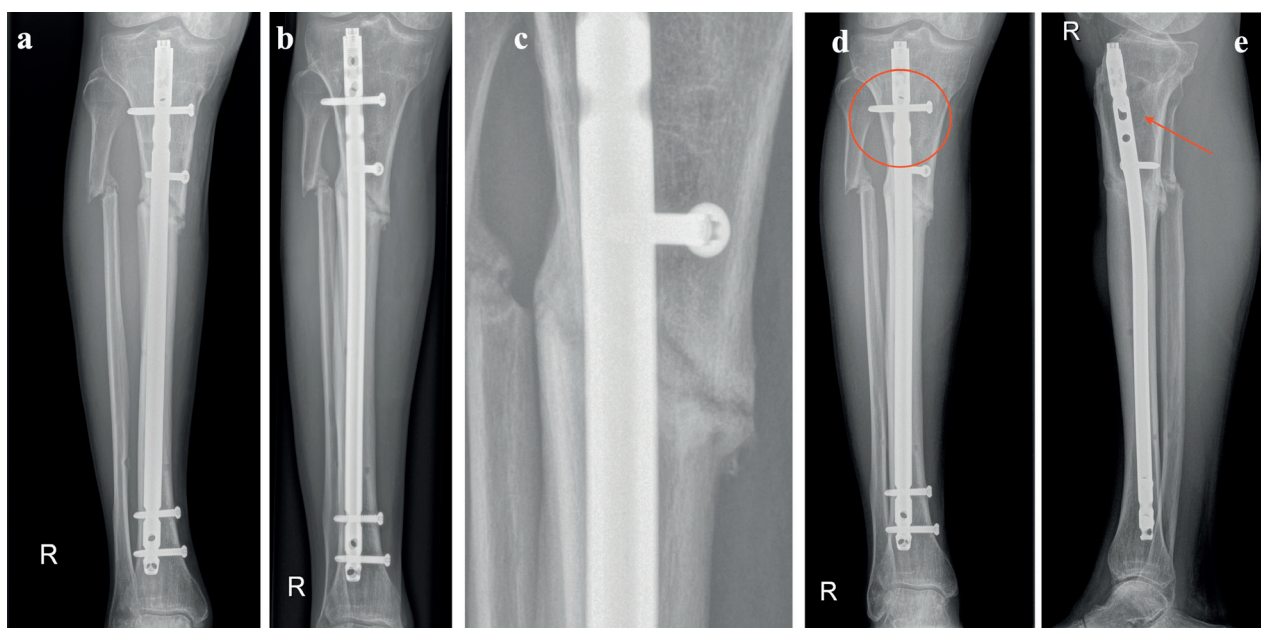
**Figure 2.** (a, b) AP and (c) lateral view of the tibia after locked IM nailing

The day after the surgical procedure, the patient was allowed to walk with two crutches and full-weight bearing. After 60 days from the surgery the patient was able to walk without aids. However, he complained pain at the proximal-mid third of the tibia after walking for more than 60 minutes. Five months after IMN, the anteroposterior (AP) and lateral view radiographs of the lower limb showed a delayed union of the diaphyseal tibia fracture (Fig. 2). Due to this painful delayed-union, we decided to perform the nail dynamization removing the 2 static proximal interlocking screws of the nail and by preserving a screw in a dynamic locking hole (Fig.3). We then inserted a poller screw slightly medial to the nail from anterior to posterior, in order to provide additional stability of the proximal fragment (Fig. 3c). The patient was allowed to full weight-bearing the day after the surgery. He reported complete pain relief without the need for pain killers since the same day. After one month, AP view radiographs showed callus formation at the lateral cortical bone. The following x-rays at two, three and six months after the surgery,

showed the progressive bridging callus and the complete fracture healing at six months (Fig. 3d, 3e). We used the measurement tools of our PACS (Picture archiving and communication system) viewer (Suitestensa RIS PACS, Ebit, Esaote, Italy) to analyze the position of the proximal screw positioned in the dynamic hole of nail, as indirect sign of nail dynamization and fracture compression. However, the screw appeared to be at the same position and no signs of migration were found. At 12 month follow up, the patient still did not complain about pain or discomfort. Passive and active range of motion of the knee is complete and no limb length discrepancy was detected.

### Case report #2

A 38-years old man was admitted to our department on June 2018 for the treatment of a close tibia shaft fracture due to a sport-related injury. Fracture was classified as an AO/OTA intact wedge fracture



**Figure 3.** (a, b) AP and lateral view of the tibia showing delayed union. (c) The static screws were removed and a Poller blocking screw was placed slightly medial to the nail; (d, e) AP and lateral view of the tibia showing complete bone union 3 months after dynamization and augmentation with Poller screw. The red circle and the red arrow note indicate that the position of the proximal screw in the dynamic hole did not change

42B2 of the proximal 1/3 of the tibial diaphysis (Fig. 4a, 4b). The patient underwent closed reduction and locked intramedullary nailing (IMN) of the tibial shaft fracture (Fig. 4c, 4d, 4e). Both static and dynamic screws were placed. The day after the surgical procedure, the patient was allowed to walk with two crutches and full-weight bearing.

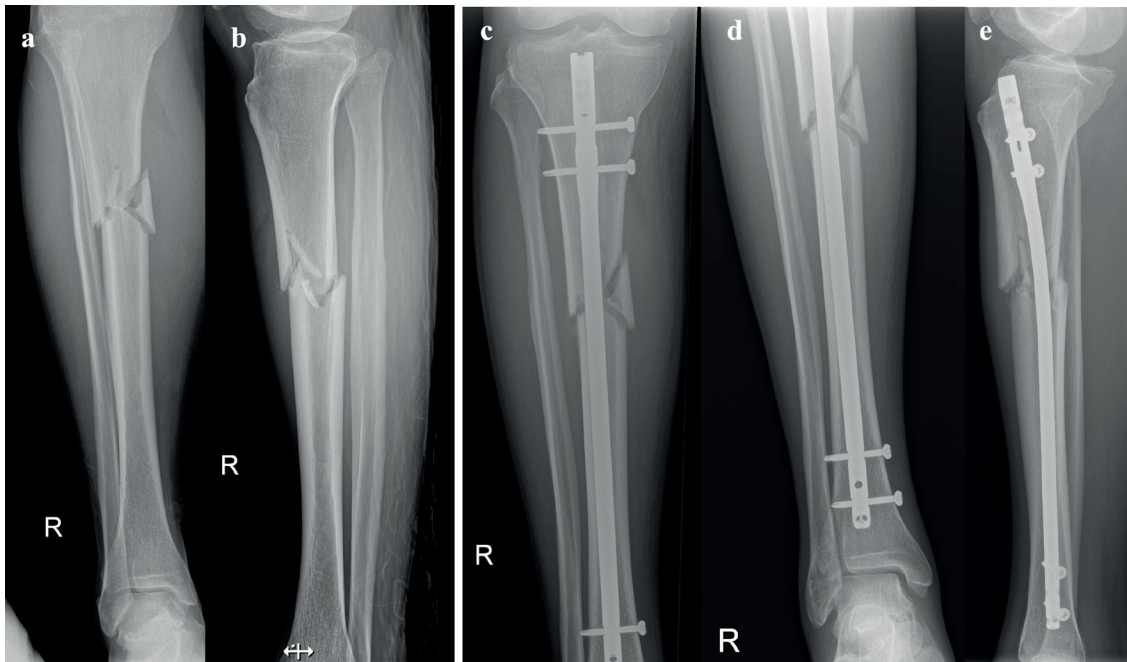
After three months from the surgery the patient referred persistent pain at the proximal third of the tibia and he still walked with the aid of two canes. At radiographs there was no evidence of callus formation and fracture gap appeared equal to the postoperative images (Fig. 5a, 5b). Moreover, the static proximal locking screw broke. We decided to wait and see if the screw breakage would eventually provide the nail dynamization. After 6 months from the surgery, the patient still complaint pain and there were no signs of fracture healing, nail dynamization and fracture compression.

In December 2018, we removed the broken screw, performed the nail dynamization by removing the distal locking screws and a fibular osteotomy to favor fracture compression. Moreover, we augmented

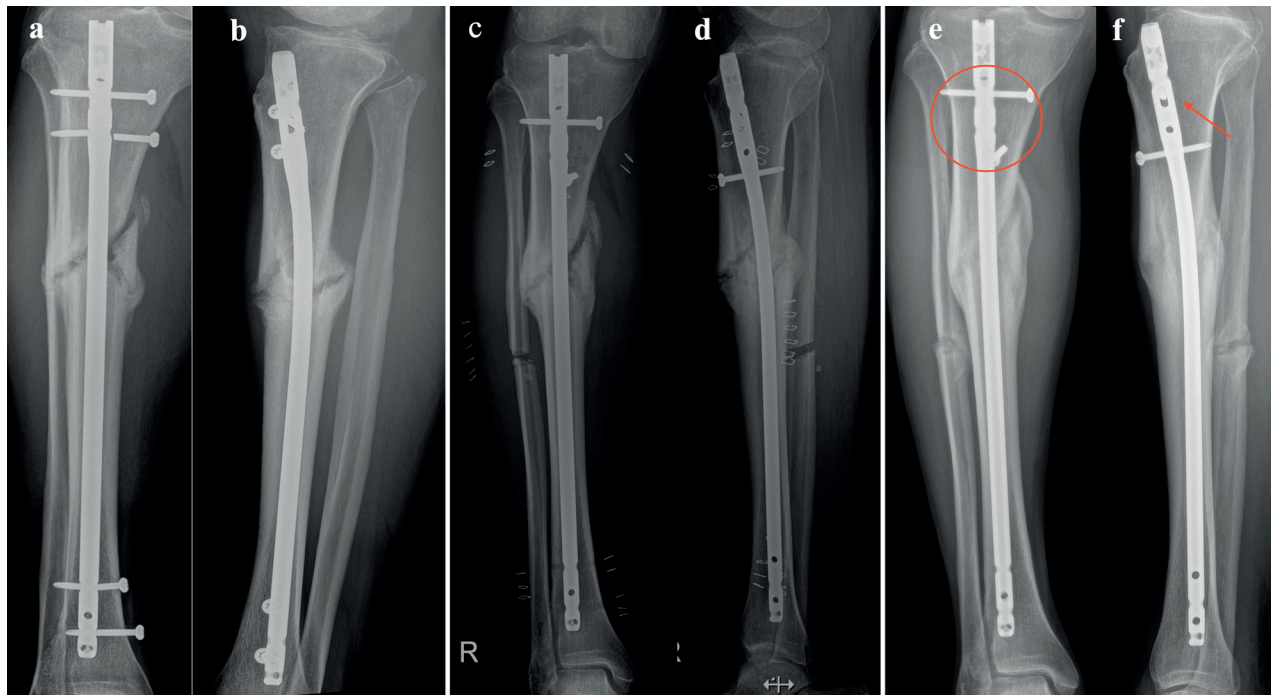
the fracture stability with a poller blocking screw of the proximal fragment on the medial side of the nail (Fig. 5c, 5d). The day after the surgery the patient was allowed to full-weight bearing and he reported reduction of pain. Thirty days later he walked without the need for aids and pain-free. Three months later, the fracture appeared completely healed, without signs of dynamization of the nail (Fig. 5e, 5f). The patient still did not complain about pain or discomfort. Passive and active range of motion of the knee is complete and no limb length discrepancy was detected. Eventually the patient had returned to his sport activity. Signs of advanced bone remodeling were found at x-rays. As for the first case described, analyzing the position of the proximal screw positioned in the dynamic hole, there were not signs of fracture compression.

## Discussion

Non-articular fractures of the proximal and distal tibia account for 5 to 11% of tibia shaft fractures and as the other closed and open tibial shaft fractures, are



**Figure 4.** (a, b) AP and lateral view of the tibia showing a close fracture of the proximal 1/3 of the tibial diaphysis. (c,d) AP and (e) lateral view of the tibia showing IM nailing with 2 proximal and distal locking screw in the static configuration



**Figure 5.** a, b) AP lateral view of the tibia at 4 months from the surgery showing sign of hypertrophic delayed union. The red arrow indicates the breakage of one the proximal screws. (c, d) After 5 months from IMN, removal of the broken screw, dynamization of the nail by removing the distal locking screw and fibular osteotomy were performed. In addition a blocking Poller screw was placed slightly medial to the nail. (e, f) 3 months after the dynamization and screw augmentation the fracture was completely healed. The red circle and the red arrow note indicate that the position of the proximal screw in the dynamic hole did not change

mainly related to high energy trauma in young adult patients (8). However, according to ageing of the population, increase rates of fragility fractures of the tibial shaft have been reported in elderly patients, often related to complex fracture pattern (8–10). Although IMN represent the best suited option for diaphyseal fractures of long bones, delayed union and nonunion represent frequent complications which are the result of a number of both patient-related and fracture-related factors which could negatively affect the healing process (2,11,12). Impaired blood supply and mechanical instability at the fracture gap are the most important fracture-related factors (13,14).

Surgical approaches such as nail dynamization, exchange nailing and augmentation plating aim to address the mechanical issues supporting delayed union and non-unions (5)(15)(16).

Nail dynamization provides fracture compression through the removal of interlocking screws of the IM nail, either proximal or distal to the fracture site. The enhancement of micro-movement at the fracture site results in stimulation of osteogenesis. A fracture is considered suitable for dynamization only when sufficient stability at the fracture site is obtained. Moreover, dynamization has to be avoided in case of multi-fragmentary and comminuted fracture at risk for loss of reduction.

Exchange nailing involves removal of the original nail, reaming the tibial canal removing any nonviable tissue and accommodate a new nail at least 1 mm larger than the original(5–7). The procedure theoretically improves healing rates due to increased blood supply and bone autologous grafting induced by reaming, and the additional stability from using a nail of larger radius(5). Augmentation plating consists in placing a plate over a retained nail improving the stiffness of the construct and reducing micromotions (16)(18). Further compression at the nonunion site when needed can be achieved with the use of a dynamic compression plate. Union rates after revision range from 84% to 98% for both femoral and tibia fractures nonunion.

However, exchange nailing and augmentation plating are invasive and technical demanding procedure compared to nail dynamization, therefore, their use should be considered restricted to recalcitrant delayed unions or in those cases not suitable for nail

dynamization. On the other hand, nail dynamization should be considered the first choice when radiological signs of impaired bone healing are visible after the first 3 months(19). There is not consensus about the best timing for the procedure but available results suggest that dynamization of delayed union is more promising than dynamization of tibial diaphyseal non-unions(15). Litrenta et al. in a large series of IMN dynamization for tibial shaft fracture, reported a mean 5.2 months from the trauma to the procedure(7). They found out union in 83% of cases and reported worst results in patients with a fracture gap.

In order to provide additional stability after nail dynamization, we used blocking Poller screws to supplement intramedullary nailing for proximal tibial delayed unions. The Poller blocking screw, which was devised by *Krettek et al.*, have been traditionally applied with the aim to decrease the width of the medullary cavity and guide the nail in the center of the widened meta-diaphyseal flaring area(20). Several authors demonstrated that sagittal-directed blocking screws, placed adjacent to an intramedullary nail with frontally oriented interlocking screws can significantly increase the primary stability in both proximal and distal tibial fractures. (4,21).

The rationale for the use of Poller blocking screws in delayed union of proximal or distal shaft fractures is that, decreasing the width of the medullary cavity and enhancing the contact area implant/internal cortex at the center of the widened canal, the mechanical stiffness of the bone-implant construct would result improved (4). In our clinical practice we have applied Poller blocking screws in addition to other traditional surgical techniques for bone healing enhancement of delayed union and nonunion. In the first case, we performed at the same time dynamization by removing the static proximal locking screws and leaving the dynamic screw in order to control rotation(6). The immediate pain relief clinically reported by the patient, should be addressed by the additional stability obtained with the combination of the two procedures. Conversely, we did not find any migration of the nail at digital radiologic analysis, therefore, the role of fracture compression after dynamization has to be considered marginal.

Similarly in the second case we presented, we speculated that the delayed union was related to a

combination of wide fracture gap (due to insufficient fracture compression) and fracture instability. The breakage of the static proximal fracture after two months represented the first sign of “need for compression” of this fracture. However, this event did not provide fracture compression and it seemed to make even more instable the fracture gap, with radiological signs of a hypertrophic callus. Therefore, we choose to combine Poller blocking screws augmentation in addition to nail dynamization and fibular osteotomy, to achieve both fracture compression and improved bone-implant construct stiffness. As per the first case, we did not found any migration of the nail at digital radiologic analysis, therefore, we considered marginal the role of fracture compression after dynamization and fibular osteotomy.

To the best of our knowledge, there are no studies in the English literature describing the use of a Poller screw to treat a tibial delayed union or nonunion without changing the nail. In the literature only Eom et al. in 2016 has reported the successful use of a Poller blocking screw to treat a nonunion of femoral shaft fracture(22). They used multiple Poller screw to augment the stability of the distal fragment of a mid-shaft femoral fracture which underwent to nonunion, leading the fracture to healing after 3 months.

## Conclusion

Although little information can be brought from a single case report, we conclude that the Poller blocking screw augmentation for delayed union after IMN represented a simple, cost-effective, minimally invasive surgical technique which permitted a quick recovery, full weight-bearing and early pain relief. Blocking screws could increase the overall mechanical stability of distal and proximal tibia fractures, in which a mismatch between nail diameter and canal width exists. In our cases, the main biomechanical effect was determined by the neutralization of the shear forces after the insertion of the Poller screw. Instead, the compression effect - due to nail dynamization was, in our opinion, biomechanically non-significant. We believe that Poller screw augmentation could represent an effective procedure, especially in the hypertrophic delayed un-

ion. Biomechanical studies and then large clinical trials are needed in order to provide the evidence about the extensive use of this procedure.

**Conflict of interests:** Each author declares that he or she has no commercial associations that might pose a conflict of interest in connection with the submitted article

## Reference

1. Schandelmaier P, Farouk O, Krettek C, Reimers N, Mannss J, Tscherne H. Biomechanics of femoral interlocking nails. *Injury*. 2000 Jul;31(6):437–43.
2. Zelle BA, Bhandari M, Espiritu M, Koval KJ, Zlowodzki M, Evidence-Based Orthopaedic Trauma Working Group. Treatment of distal tibia fractures without articular involvement: a systematic review of 1125 fractures. *J Orthop Trauma*. 2006 Jan;20(1):76–9.
3. Rupp M, Biehl C, Budak M, Thormann U, Heiss C, Alt V. Diaphyseal long bone nonunions - types, aetiology, economics, and treatment recommendations. *Int Orthop*. 2018;42(2):247–58.
4. Song S-H. Radiologic Outcomes of Intramedullary Nailing in Intraisthmal Femur-Shaft Fracture with or without Poller Screws. *Biomed Res Int*. 2019;2019:9412379.
5. Swanson EA, Garrard EC, O Connor DP, Brinker MR. Results of a systematic approach to exchange nailing for the treatment of aseptic tibial nonunions. *J Orthop Trauma*. 2015 Jan;29(1):28–35.
6. Huang K-C, Tong K-M, Lin Y-M, Loh E-W, Hsu C-E. Evaluation of methods and timing in nail dynamisation for treating delayed healing femoral shaft fractures. *Injury*. 2012 Oct;43(10):1747–52.
7. Litrenta J, Tornetta P, Vallier H, Firoozabadi R, Leighton R, Egol K, et al. Dynamizations and Exchanges: Success Rates and Indications. *J Orthop Trauma*. 2015 Dec;29(12):569–73.
8. Wennergren D, Bergdahl C, Ekelund J, Juto H, Sundfeldt M, Möller M. Epidemiology and incidence of tibia fractures in the Swedish Fracture Register. *Injury*. 2018 Nov;49(11):2068–74.
9. Court-Brown CM, Clement ND, Duckworth AD, Biant LC, McQueen MM. The changing epidemiology of fall-related fractures in adults. *Injury*. 2017 Apr;48(4):819–24.
10. Marongiu G, Mastio M, Capone A. Current options to surgical treatment in osteoporotic fractures. *Aging Clin Exp Res*. 2013 Oct;25(S1):15–7.
11. Mills LA, Aitken SA, Simpson AHRW. The risk of non-union per fracture: current myths and revised figures from a population of over 4 million adults. *Acta Orthop*. 2017 Aug;88(4):434–9.

12. Massari L, Benazzo F, Falez F, Cadossi R, Perugia D, Pietrogrande L, et al. Can Clinical and Surgical Parameters Be Combined to Predict How Long It Will Take a Tibia Fracture to Heal? A Prospective Multicentre Observational Study: The FRACTING Study. *Biomed Res Int.* 2018;2018:1809091.
13. Frölke JPM, Patka P. Definition and classification of fracture non-unions. *Injury.* 2007 May;38 Suppl 2:S19-22.
14. Marongiu G, Capone A. Atypical periprosthetic acetabular fracture in long-term alendronate therapy. *Clin Cases Miner Bone Metab.* 2016 Dec;13(3):209-13.
15. Vaughn J, Gotha H, Cohen E, Fantry AJ, Feller RJ, Van Meter J, et al. Nail Dynamization for Delayed Union and Nonunion in Femur and Tibia Fractures. *Orthopedics.* 2016 Nov 1;39(6):e1117-23.
16. Ateschrang A, Karavalakis G, Gonser C, Liener U, Freude T, Stöckle U, et al. Exchange reamed nailing compared to augmentation compression plating leaving the inserted nail in situ in the treatment of aseptic tibial non-union: a two-centre study. *Wien Klin Wochenschr.* 2013 May;125(9-10):244-53.
17. Brinker MR, O'Connor DP. Exchange nailing of ununited fractures. *J Bone Joint Surg Am.* 2007 Jan;89(1):177-88.
18. Chiang JC, Johnson JE, Tarkin IS, Siska PA, Farrell DJ, Mormino MA. Plate augmentation for femoral nonunion: more than just a salvage tool? *Arch Orthop Trauma Surg.* 2016 Feb;136(2):149-56.
19. Vaughn JE, Shah RV, Samman T, Stirton J, Liu J, Ebraheim NA. Systematic review of dynamization vs exchange nailing for delayed/non-union femoral fractures. *World J Orthop.* 2018 Jul 18;9(7):92-9.
20. Krettek C, Stephan C, Schandelmaier P, Richter M, Pape HC, Miclau T. The use of Poller screws as blocking screws in stabilising tibial fractures treated with small diameter intramedullary nails. *J Bone Joint Surg Br.* 1999 Nov;81(6):963-8.
21. Krettek C, Miclau T, Schandelmaier P, Stephan C, Möhlmann U, Tscherne H. The mechanical effect of blocking screws ("Poller screws") in stabilizing tibia fractures with short proximal or distal fragments after insertion of small-diameter intramedullary nails. *J Orthop Trauma.* 1999 Nov;13(8):550-3.
22. Eom TW, Kim JJ, Oh HK, Kim JW. Challenge to treat hypertrophic nonunion of the femoral shaft: the Poller screw augmentation technique. *Eur J Orthop Surg Traumatol.* 2016 Aug;26(6):559-63.

Received: 22 January 2020

Accepted: 01 February 2020

Correspondence:

Dr. Giuseppe Marongiu, M.D.

Orthopedic and Trauma Clinic,

Ospedale Marino,

Department of Surgical Sciences,

University of Cagliari,

Cagliari, Italy

Fax/tel: 070 6094368

tel. +39348816853

E-mail; Giuse.marongiu@gmail.com;

giuseppe.marongiu@unica.it