

C A S E R E P O R T

Acute abdominal pain in an adolescent girl with an ovarian yolk sac tumor

Ettore Stefanelli¹, Valentina Talarico², Maria Scavone¹, Elena Carboni¹, Giuseppe Stranieri³, Maria Concetta Galati⁴, Domenico Salerno³, Giuseppe Raiola²

¹Department of Pediatrics, Magna Graecia University of Catanzaro, Catanzaro, Italy; ²Department of Pediatrics, "Pugliese-Ciaccio" Hospital, Catanzaro, Italy; ³Department of Pediatric Surgery, "Pugliese-Ciaccio" Hospital, Catanzaro, Italy; ⁴Department of Pediatric Oncohematology, "Pugliese-Ciaccio" Hospital, Catanzaro, Italy

Summary. Yolk sac tumor (YST) is a rare tumor that usually occurs in the first two decades of life. It is considered the second most common malignant germ cell tumor of the ovary, characterized by a rapid growth and a bad prognosis due to the frequent metastasis. We report the case of a 12-year-old girl who came to our observation for an acute abdominal pain. Clinical examination evidenced a vague mass in the suprapubic region and a lower abdomen tenderness, the US imaging revealed a complex lesion of the left ovary (19 x 13 cm) and the alpha-fetoprotein (AFP) resulted high (5858 ng/mL). Computed tomography (CT) revealed a large pelvic mass. The treatment consisted of debulking surgery of yolk sac tumor followed by 4 cycles of BEP protocol (Bleomycin, Etoposide, Cisplatin). After 3 years of follow-up there was no evidence of disease recurrence. (www.actabiomedica.it)

Key words: yolk sac tumor, germ cell tumor, ovarian torsion, ovarian tumor, alpha-fetoprotein

Introduction

Yolk sac tumor (YST) of the ovary, also known as endodermal sinus tumor (EST), is a rare malignant lesion, which belongs to the group of malignant ovarian germ cell tumors (MOGCT). It is considered the second most frequent MOGCT after dysgerminoma, with an incidence of approximately 1% of the ovarian tumors in children and adolescent (1, 2). It is highly malignant and it has a bad prognosis (3). Its frequency is higher in Japan compared to North America and Western Europe (4). The histology of the ovarian tumors is variable and the prevalence of the different types of tumors is different between adults and children (5). The incidence of malignant lesions increases with patient's age and tends to be associated with higher levels of serum tumor markers (6). So it is imperative that these lesions are precociously detected and effectively treated.

We present a case of a YST in a 12-year-old adolescent girl, remarking the importance to consider these rare tumors when an abdominal or pelvic mass is found.

Case Report

A 12-year-old Caucasian girl presented to the Emergency Department for a sudden abdominal pain. There was no known previous medical history. At clinical examination she was in Tanner's stage 2-3, afebrile, tachycardic, tachypneic and normotensive.

Abdominal evaluation revealed a swelling mass characterized by hard consistency and undefined outlines in the suprapubic region. A transabdominal ultrasonography (US) showed a heterogeneous mass of 19 x 13 cm with mixed echogenic and hypoechoic components. A pelvic computed tomography (CT) evidenced

a fluid disomogeneous complex mass of 20 x 14 x 9 cm with fatty components and some hyperdense calcific areas (Figure 1). This mass dislocated the uterus to the right, the bowel loops to the upper-right quadrant and the bladder ahead. Hence the mass was presumed to have an ovarian origin. The serum tumor markers, human chorionic gonadotropin (β -hGC) and cancer antigen 125 (CA 125), assessed before the operation, were within normal limits, while alpha-fetoprotein (AFP) was high (5858 ng/mL; normal range 0-12 ng/mL) orienting to a diagnosis of ovarian YST.

An emergency laparotomy was performed; bloody ascites and peritoneal inflammation were found. No signs of macroscopic invasion of the pelvic structures were present. After the reduction of the cystic lesion by aspiration, a left salpingo-oophorectomy was performed (Figure 2).

Macroscopic anatomy showed an enlarged ovarian mass with large areas of necrosis and hemorrhage mixed with solid and cystic components. There was no evidence of left tube involvement. Microscopically, the tumor had an epithelial cell type appearance with Schiller-Duval bodies. On immunohistochemistry, tumor cells were positive for AFP and negative for

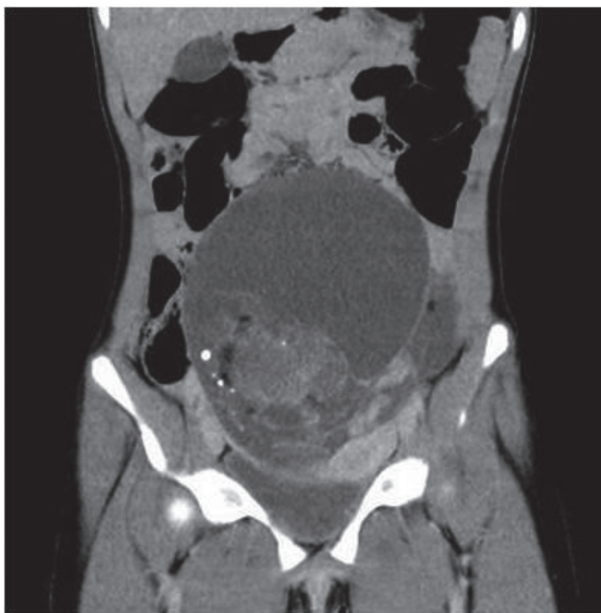


Figure 1. CT scan (sagittal section) showing a large pelvic mass, measuring 20 x 14 x 9 cm, with fatty components and some hyperdense calcific areas

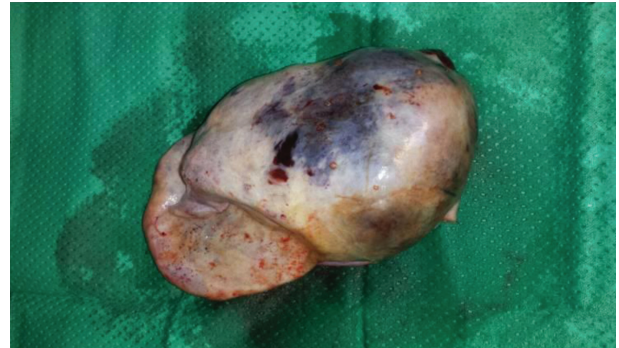

Figure 2. Postoperative enlarged ovarian mass with large areas of necrosis and hemorrhage mixed with solid and cystic components

CD30 and placental alkaline phosphatase (PLAP). Peritoneal washing cytology and multiple biopsies of the peritoneum and omentum were negative.

These findings were consistent with a diagnosis of YST associated to minor teratomatous lesions. The patient was discharged 5 days after the operation, and referred to the oncologist for a further treatment. An adjuvant chemotherapy regimen was performed according to the national comprehensive cancer network (4 cycles of bleomycin, etoposide and cisplatin: BEP) (7). Clinical surveillance did not reveal any chemotherapy-related toxicity.

A normalization of AFP level was observed within 2 months after surgery, suggesting an absence of residual tumor.

During 3 years of follow-up, the serum tumor markers and pelvic magnetic resonance imaging (MRI) showed no evidence of recurrence.

Discussion

A YST is the second most common malignant germ cell tumor and counts for only 1% of the malignant ovarian masses (8). It is most common in patients between 18 to 25 years. In most cases there are no clinical symptoms. However, abdominal swelling may be present in case of rapid growth. The size of tumors varies from 7 cm to 40 cm, with a median of 15-16 cm. The tumor is rarely bilateral (12-19%).

In symptomatic patients, abdominal pain is quite frequently complained leading to the discovery of the

disease, as seen in our patient. Clinical signs consist of an abdominal or pelvic mass, vaginal bleeding, fever, ascites or peritonitis secondary to torsion, infection or rupture of the ovarian tumor (9). The survival rate is higher in patients with earlier stage disease (stage I or II).

At present, the etiology of YST remains obscure. YST may develop from the false migration of embryonic primitive pluripotent germ cells or oncogenesis of the residual cells when they migrate from the genital ridge of the yolk sac endoderm (10).

These lesions typically determine abdominal pain with a rapidly enlarging abdominal mass (11). Moreover, like in this case, ascites or peritonitis, due to the torsion of the lesion, are rare additional features (12). CT scan and MRI are the most common techniques used to diagnose these lesions, but there are no specific signs to distinguish YST from other ovarian masses.

After treatment, periodic reevaluations are required, such as abdominal and pelvic examination, CT scan, chest X-ray and AFP levels. YST are heterogeneous with a number of different histopathological subtypes. The typical histopathological features of YST are solid, tubular and focal papillary patterns with Schiller-Duval bodies and sinusoidal structures with fibrovascular cores lining formed by tumor cells, frequent mitotic figures and are cytokeratin positive (13). In children, the vast majority of YST (85%) are in clinical stage I in comparison to a lower percentage (35%) in adults (14). AFP can be applied as a feasible tumor marker because its level is elevated in > 90% of YST (15, 16). In our case, the level of AFP was also increased (5858 ng/mL).

Therapeutic approach is based on surgery and chemotherapy, depending on the stage of the tumor based on FIGO classification. The aim of surgery is removing the primary ovarian tumor without excessive morbidity. The standard surgical staging consists of peritoneal washing, peritoneal biopsies, and biopsies of any suspicious lesions. Factors related to good prognosis are no ascites at presentation, stage I disease, less than 42 days to AFP normalization, fertility-sparing surgery and a serum AFP half-life less of 10 days (17).

The BEP is considered the gold-standard first-line treatment for germ cell tumors at all stages (18). Abdominal and pelvic examination, CT, chest X-ray

and AFP levels are suggested during the follow-up (19). Progressive or recurrent ovarian tumour after treatment with BEP chemotherapy has been reported to be associated with a poor prognosis (17). The use of radiotherapy remains poorly defined because of its addiction to chemotherapy had no effect on improving survival.

During 3 years of follow-up, the serum tumor markers and pelvic MRI showed no evidence of recurrence.

Conclusions

YST are rare neoplasms that usually occurs in the first two decades of life. Surgery with adjuvant chemotherapy is the standard management. It is important for clinicians to remember that patients with YST can present abdominal pain in an unusual way. Serum AFP is a useful marker for the diagnosis and management of YST. More research is required for investigating the mechanisms of pathogenesis in order to develop more effective treatments for YST.

Ethics statement: We have obtained verbal informed consent from the patient's guardian for the publication of this case report.

Conflict of interest: Each author declares that he or she has no commercial associations (e.g. consultancies, stock ownership, equity interest, patent/licensing arrangement etc.) that might pose a conflict of interest in connection with the submitted article

References

1. Fujita M, Inoue M, Tanizawa O, et al. Retrospective review of 41 patients with endodermal sinus tumor of the ovary. *Int J Gynecol Cancer* 1993; 3:329-335.
2. Caserta D, Ralli E, Bordi G, Moscarini M. An unusual clinical presentation of a pure yolk sac tumor of the ovary: case report. *Eur J Gynaec Oncol* 2013;34:577-579.
3. Mitchell PL, Al-Nasiri N, A'Hern R, et al. Treatment of non-dysgerminomatous ovarian germ cell tumors: an analysis of 69 cases. *Cancer* 1999; 85:2232-2244.
4. Nawa A, Obata N, Kikkawa F, et al. Prognostic factors of patients with yolk sac tumors of the ovary. *Am J Obstet Gynecol* 2001; 184:1182-1188.
5. von Allmen D. Malignant lesions of the ovary in childhood. *Semin Pediatr Surg* 2005;14:100-105.
6. Loh AH, Gee KW, Chua JH. Diagnostic accuracy of pre-operative alpha-fetoprotein as an ovarian tumor marker in

- children and adolescents: not as good as we thought?. *Pediatr Surg Int* 2013; 29:709-713.
7. Eddaoualline H, Sami H, Rais H, et al. Ovarian Yolk sac tumor: a case report and literature review. *Clin Case Rep Int* 2018; 2:1057.
 8. Dallenbach P, Bonnefo iH, Pelte MF, Vlastos G. Yolk sac tumors of the ovary: an update. *Eur J Surg Oncol* 2006; 32:1063-1075.
 9. Fathalla AE, Shokralla HA. Yolk Sac Tumor of the Ovary in 18 Egyptian Cases: Does It Really Differ? *J Cancer Ther* 2016; 7:247-253.
 10. Mckenny J, Heerema-McKenney A, Rouse RV. Extragonadal germ cell tumors: a review with emphasis on pathologic features, clinical prognostic variables, and differential diagnostic considerations. *Adv Anat Pathol* 2007; 14:69-92.
 11. Jones RG, Akande MY, Younes HK, et al. Yolk sac tumor of the ovary in a young girl with tuberous sclerosis: A case report and review of the literature. *Gynecol Oncol Rep* 2014;10:9-12.
 12. Tewari K, Cappuccini F, Disaia PJ, et al. Malignant germ cell tumors of the ovary. *Obstet Gynecol* 2000;95:128-133.
 13. van den Akker M, Vervloessem D, Huybrechs A, Declercq S, van der Werff Ten Bosch J. Yolk sac tumor in the abdominal wall of an 18-month-old girl: a case report. *J Med Case Rep* 2017;11:47.
 14. Christopher SC. Prepubertal Testicular and Paratesticular Tumors: Medscape Reference. New York, NY:WebMD LLC, 2011.
 15. Khan IU, Jose J, Fawazy T, Hadi WA, Sharma PK. Testicular yolk sac tumor in an eight-month old child: a case report. *Gulf Med J* 2012; 1:37-40.
 16. Sell A, Sogaard H, Norgaard-Pedersen B. Serum alpha-fetoprotein as a marker for the effect of post-operative radiation therapy and/or chemotherapy in eight cases of ovarian endodermal sinus tumour. *Int J Cancer* 1976;18:574-580.
 17. Guida M, Pignata S, Palumbo AR. et al. Laparoscopic treatment of a yolk sac tumour: case report and literature review. *Translational Med* 2013;7:1-5.
 18. Moniaga NC, Randall LM. Malignant mixed ovarian germ cell tumour with embryonal component. *J Pediatr Adolesc Gynecol* 2011;24:e1-e3.
 19. Kawai M, Kano T, Furuhashi Y et al. Prognostic factors in yolk sac tumors of the ovary. A clinicopathologic analysis of 29 cases. *Cancer* 1991; 67:184-192.

Received: 11 November 2019

Accepted: 10 December 2019

Correspondence:

Dr. Valentina Talarico

Department of Pediatric,

“Pugliese-Ciaccio” Hospital,

88100 Catanzaro, Italy

Tel +39 3402457848

E-mail: mail: talaricovalentina@gmail.com