

## C A S E R E P O R T

# Injury of the brachial artery accompanying simple closed elbow dislocation: a case report

Goretti Claudio<sup>a</sup>, Pari Carlotta<sup>a\*</sup>, Puzzo Agnese<sup>a</sup>, Rizqallah Yousef<sup>a</sup>, Bonanno Maria Giovanna<sup>b</sup>, Belluati Alberto<sup>a</sup>.

<sup>a</sup>Orthopaedic and Trauma Department, Hospital Santa Maria delle Croci, Ravenna, Italy

<sup>b</sup>Vascular Surgery Department, St. Orsola-Malpighi University Hospital, Bologna, Italy

## Abstract

**Background:** Elbow dislocation is the second common dislocation in adults, after the shoulder. The anatomical proximity to the joint of the brachial artery could lead to concomitant vascular injuries, even if their occurrence remains very rare. **Method:** It is reported the case of a right-hand-dominant 42-year-old man who sustained a simple closed posterior elbow dislocation of his left elbow, associated to a complete brachial artery rupture. He urgently underwent the reduction of the joint dislocation and an artery-repairing surgical procedure using a graft from ipsilateral saphenous vein. **Results:** The full functional capacity of the elbow was obtained. **Conclusions:** The abundance of the brachial artery collateral network may hide the presence of a vascular injury, potentially associated to a closed elbow dislocation. Therefore, a high index of suspicion should be maintained. The Emergency Team plays a crucial role in its early diagnosis, which is essential to avoid irreversible ischemia related damages. A prompt reduction of the joint dislocation and the vascular injury surgical repair are required. Regarding the treatment of the concomitant collateral ligaments and capsular injuries, the indication to proceed to the simultaneous ligaments reconstruction is still controversial in literature.

**Keywords:** Elbow dislocation, Brachial Artery Injury, Saphenous Vein Graft

## Introduction

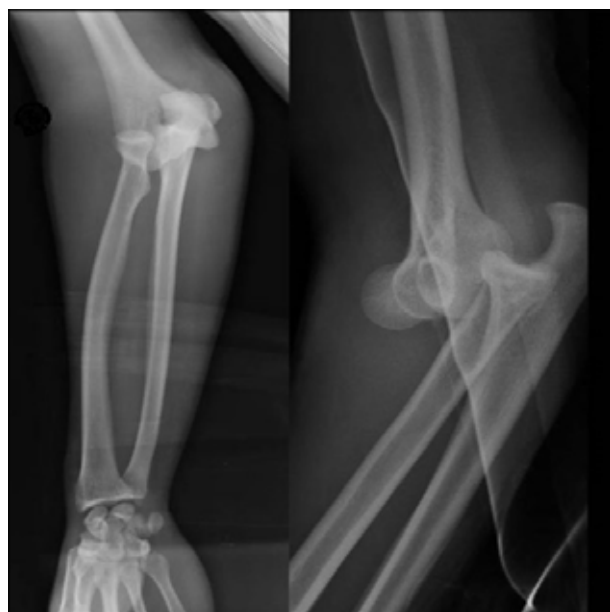The elbow dislocation is the most common major joint dislocation in adults, second only to the shoulder [1-2]. It is classified as simple or complex, according to the presence or the absence of associated fractures. The simple type consists of a pure elbow dislocation with isolated soft tissue injuries; it might possibly be present a small avulsion fracture. The complex type consists of a dislocation with both ligament injuries and associated fractures of the elbow, such as olecranon fractures, radial head fractures and coronoid fractures, which contribute to elbow instability [3-4].

Recently, Mayne et al. reported an incidence of 2.65 per 100.000 person-years in the adult population [5].

The elbow joint dislocation could be complicated by neurovascular injuries due to the anatomical proximity of the brachial artery and the median nerve. The brachial artery damage is reported to be mainly associated to open elbow dislocations or to the presence of penetrating wounds at the elbow site; however, it is rare in closed dislocations. Sparks et al. reported an incidence of 0.47% of brachial artery rupture in a 5-year retrospective analysis on 634 patients, who had sustained a simple closed elbow dislocation [6]. The recognition of the of the brachial artery injury could be difficult. However, a high index of suspicion should be maintained in order to make an early diagnosis, which is essential to avoid irreversible ischemia related damages.

## Case Presentation

A right-hand-dominant 42-year-old man was admitted to our Emergency Department having sustained a fall from a standing height on his left arm during a football match, one hour earlier. He presented to us with a clear elbow deformity, swelling and persistent paresthesia of the hand. Even if the hand remained warm and pink and seemed to conserve a good capillary refill, no radial and ulnar pulses could be traced at the wrist. X-rays revealed a closed posterior dislocation of the elbow, without associated fractures (fig.1). Immediate closed reduction was performed, obtaining the restoration of the joint congruity and the resolution of the hand paresthesia. Nevertheless, the weakness of the radial and the ulnar pulses persisted, and the Color Doppler Ultrasound evaluation revealed a sub-acute ischemia of the forearm, caused by the thrombosis of the brachial artery. He was urgently taken to the operating room for a surgical exploration : a 4-centimetre rupture of the brachial artery was found proximally to the split into its radial and ulnar branches. Both the proximal and the distal extremities of the damaged artery appeared to be torn and bruised (fig.2-a).



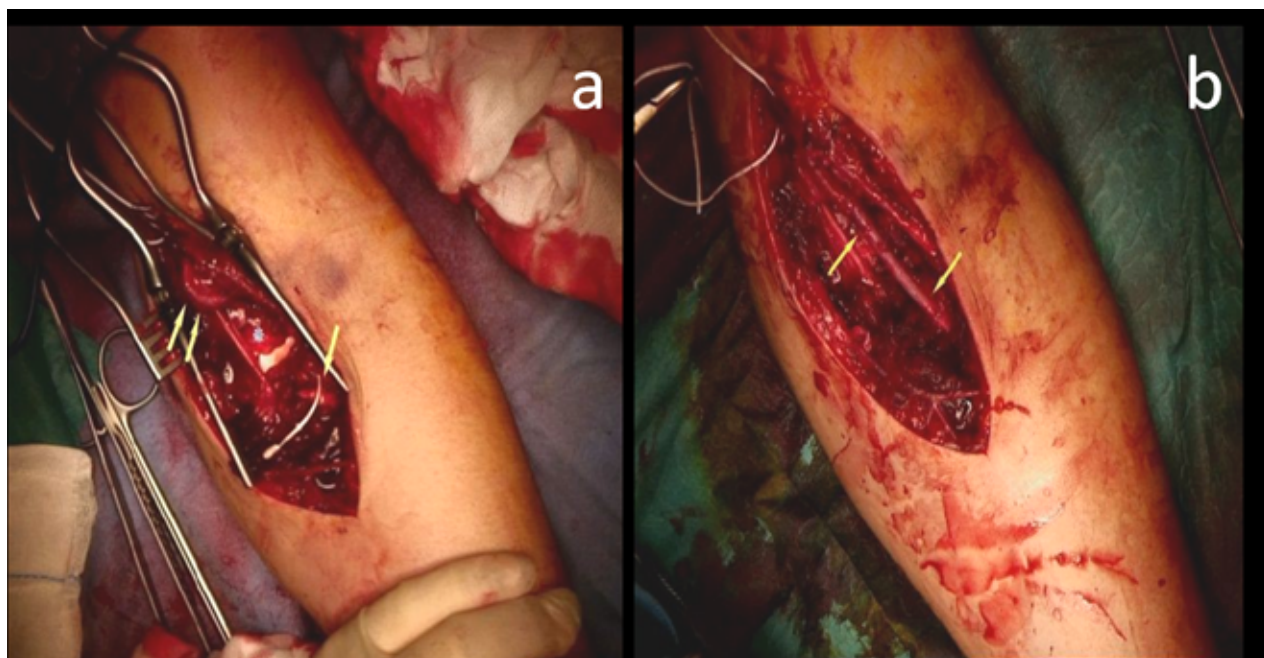
**Figure 1.** Patient's x-rays at his arrival at Emergency Department revealed a closed posterior dislocation of the left elbow.

Similarly, the anterior part of the joint capsule was torn and the common flexor tendon was detached from its origin at the medial epicondyle. A 5-centimetre interposition graft, using the ipsilateral saphenous vein, was performed with complete restoring of the distal radial and ulnar pulses (fig.2-b). The time elapsed between the trauma until the artery-repairing surgical procedure was 7 hours. The joint capsule tear was repaired. The common flexor tendon was re-anchored, by a double trans-bone suture, slightly distal from its anatomical origin, to avoid an excessively high tension nearby the newly built saphenous graft. The elbow joint stability was accurately tested at the end of the surgical procedure, and no signs of instability were found. However, it was decided to protect the joint in a fixed 90-degrees-elbow-splint for three weeks, to safeguard the neo-vascular graft. Postoperatively, a CT scan was performed to exclude the presence of any hidden bony avulsions. No post-operative complications occurred. Six days after the surgery the patient was discharged; at the splint removal he was initiated to a targeted rehabilitation programme. At the two-year follow-up the left elbow A-ROM was 10 degrees extension, 140 degrees flexion, and the patient had come back to his complete daily activities. A slight valgus instability at 30 degrees flexion, which completely receded in full extension, was still present (fig.3).

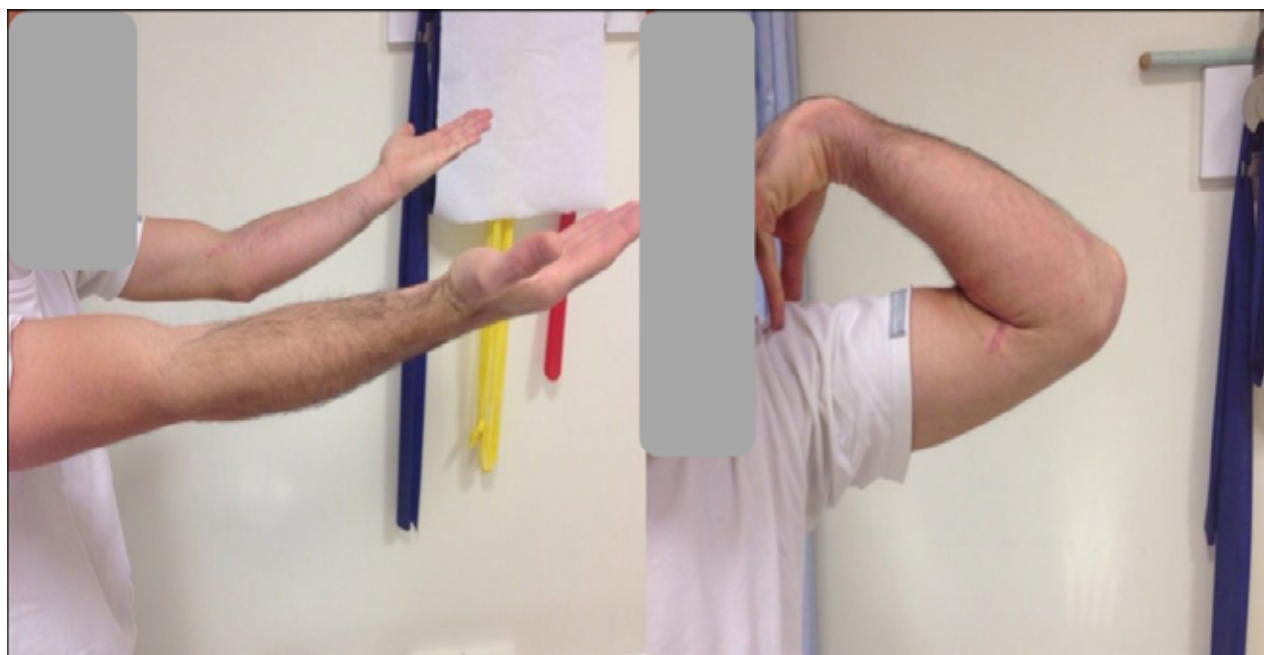
## Discussion

Closed elbow dislocations are rarely associated with arterial rupture, especially in the absence of accompanying fractures or open/penetrating injuries. Sporadic single cases are reported in literature. The only case series described, belongs to the major specialized Centres of Vascular Disease [6]. Although it might occur either in anterior and posterior dislocation, authors report a higher incidence in case of posterior dislocation [7-17].

The brachial artery is anatomically protected proximally by its medial position, but it becomes more vulnerable at its distal end, where it takes a more anterior position together with the median nerve. The rapid posterior movement of the bicipital aponeurosis, which occurs in posterior dislocation, can lead the



**Figure 2.** Both the proximal and the distal extremities of the brachial artery appeared to be torn and bruised (fig.2-a). The 5-centimetre interposition graft performed using the ipsilateral saphenous vein (fig.2-b).



**Figure 3.** Left elbow A-ROM at the 2-year follow-up.

artery to be entrapped between the bicipital aponeurosis and the dislocated bony structures of the distal part of the humerus, causing the artery disruption [7]. The risk to bump into a vascular lesion is probably related to how far the displacement extends, itself secondary to the intensity of the energy of the trauma [18]. The injury of the brachial artery can be clinically evident in case of a pulseless, cool and white hand. However, its diagnosis could be difficult due to an incomplete obliteration of the artery lumen or to the activation of collateral periarticular network, which can provide residual flow [6,8,9,19]. Collateral circulation of the elbow is organized into three vascular arcades ( medial, lateral and posterior) which provide both extraosseous and intraosseous blood supply by their perforating vessels [20]. This collateral network is immediately solicited when the main brachial axis is interrupted, explaining how it is possible to maintain the perception of a radial pulse, also in case of a disruption of the main brachial axis [18]. Distal pulses are reported to be trackable at the wrist in a percentage of 11.9% of brachial artery injuries[21], resulting in a diagnosis delay[6]. Therefore, the absence of a pulse should suggest vascular involvement, while the presence of a radial pulse does not exclude arterial damage. Cataldi et al. (2019) reported the emblematic case of a patient with a complete brachial artery injury after suffering an open elbow dislocation, where the typical clinical findings of ischemia were absent, due to the collateral network activation [22]. In most cases the damage consists in a thrombosis caused by the intensive artery spasm of the contused and torn vascular wall [8,11,12,14]; the complete rupture, as occurred in the herein patient, is much less frequent [8,10,16]. Angiography remains the gold standard elective procedure for studying the brachial artery flow; however, it requires time and it is not free from interventional risks. Hence, patients with obvious clinical symptoms of brachial artery injuries, as well as those whose Color Doppler Ultrasound evaluation demonstrates a substantial difference in pressure between the right and left brachial arteries, should undergo surgical repair without further angiographic examination [23]. The Doppler Ultrasonography has been proved to be reliable for the evaluation of the vascular injuries with a 95 to 100% sensitivity, a 97,3 to 99% specificity, and

98 to 98,7% accuracy [24]. If uncertainty remains after physical and ultrasound examination, angiography should be used to confirm the vascular injury [23], even if several authors have recently recommended the option of performing an angio-CT evaluation[10-11].

The simple ligation of the brachial artery, proposed in less recent literature, was based on the anastomotic replacement of the blood supply, and it had been performed in the past without disastrous results [12, 25].

Observation alone was successfully reported by Lim et al. in a case report in 2017 [12]. It may be considered only for cases in which the Color Doppler Ultrasound evaluation reveals a residual flow at the wrist and negligible signs of ischemia of the hand are trackable : those cases which Brahmandam defined as “pink pulseless hands”[26]. Nevertheless, the real efficacy of non-operative treatment is controversial. A wide spectrum of disability might follow the interruption of the brachial artery. While most patients experience no immediate symptoms due to the rich collateral network around the elbow, intermittent claudication of the hand, cold intolerance, Volkmann syndrome or major diseases up to gangrene, have been well documented in literature [27]. Louis et al., in a 14-cadaver anatomical study, demonstrated how, after stressing the elbow in a forced hyperextension position until it was obtained the posterior dislocation of the joint, the disruption of the Inferior Ulnar Collateral-Anterior Ulnar Recurrent anastomotic loop occurred in 13 cadavers [13]. On the bases of this study we can assume that a damage of the brachial artery and a damage of its collateral network may occur at the same time. Moreover, the swelling and the hematoma resulting from the dislocation may negatively weigh on the vascular flow. Therefore, the brachial artery repair is advocated when a dislocation is accompanied by a brachial artery disruption. The surgical repair can be accomplished by a variety of techniques, including resection with end-to-end anastomosis, or interposition graft, usually performed using the saphenous vein [28]. End-to-end anastomosis is advisable in case of clean section and total integrity of the artery walls, and if it can be performed without tension in full elbow extension [11,16]. However, the intimal lesion may extend beyond the rupture in arterial contusions,

making it necessary to cut into the healthy area to prevent the risk of secondary thrombosis: this excludes the possibility of a direct repair, requiring a venous graft [18]. The saphenous vein graft represents the gold standard procedure, otherwise synthetic graft deserves to be considered as an alternative choice, especially in case of an unsuitable saphenous vein [28]. The 'golden period' for performing the revascularization procedure is established to be within 6 to 8 hours by several authors, to maximize the post-operative outcome [29-31]. In the herein patient the time elapsed between the trauma and the arterial repair was 7 hours. The forearm fasciotomy is recommended in patients with an increased osteo-fascial compartment pressure, extended soft tissues damage, and in case of a delayed surgical procedure [32]. A prompt reduction is mandatory to restore the joint congruity, and it needs to be immediately performed after the x-rays have revealed the dislocation of the elbow. The joint congruity has to be accurately maintained both during the surgery to allow the arterial repair, and during the post-operative management to promote the 'venous graft arterializations'. In simple dislocations a fixed 90-degree elbow splint is sufficient to protect the restored joint congruity [9]. Nevertheless, some authors suggest the application of an External Fixator to obtain the absolute stability as well as an easier management of the post-operative cares, especially if a fasciotomy was performed [14,16]. Regarding the collateral ligament and capsular injuries in simple elbow dislocations, some Authors suggest that its reconstruction is not necessarily needed, and it is not free from interventional risks [33-35]. A prompt reduction and the determination of the postreduction stability are mandatory. Varus and valgus stability in full extension and at 30 to 45 degrees flexion should be tested. If a joint instability is still present more than 45 degrees flexion, the surgical treatment, consisting in ligaments repair or hinged external fixation, will be required [3,37-38]. If the joint stability is obtained, the elbow will need to be immobilized in a fixed 90-degrees-elbow-splint for 5 to 10 days before starting a targeted rehabilitation programme [3]. A prolonged immobilization for more than 3 weeks is associated with unsatisfactory outcome, due to the residual flexion contracture [37].

In case of associated brachial artery injury, the indication to proceed to the simultaneous ligaments reconstruction is still controversial in literature. Platz et al. described the immediate reconstruction of the capsule and the medial collateral ligament at the same time of the vascular repair in 3 patients, obtaining a good long-term functional outcome [15]. Nevertheless, for most of the Authors the postreduction joint stability has to be considered the crucial factor for defining when the ligaments reconstruction is really needed, regardless the presence of a vascular injury [9,10,12,13,15].

## Conclusions

Despite of the high frequency of the elbow dislocation, the associated brachial artery injury remains extremely rare, particularly in case of simple closed dislocation. The abundance of the periarticular network accounts, may hide the presence of the vascular injury, leading to its delayed diagnosis. Therefore, a high index of suspicion should be maintained in order to avoid irreversible ischemia related damages. An accurate clinical examination and the Color Doppler Ultrasound evaluation are generally sufficient to define the presence of the artery damage. If uncertainty remains, angiography or angio-TC should be used to confirm the vascular injury. The treatment consists in a prompt closed reduction of the joint dislocation, associated to the surgical exploration and repair of the brachial artery, usually performed using a saphenous vein autograft.

**Conflict Of Interest:** All authors declare there is no conflict of interest.

## References

1. Stoneback JW, Owens BD, Sykes J, Athwal GS, Pointer L, Wolf JM. Incidence of elbow dislocation in the United States population. *J Bone Joint Surg Am.* 2012 Feb 1;94(3):240-5
2. Yang NP, Chen HC, Phan DV, Yu IL, Lee YH, Chan CL et al. Epidemiological survey of orthopedic joint dislocated based on nation wide insurance data in Taiwan, 2000-2005. *BMC Musculoskelet Disord.* 2011 Nov 5;12:253

3. Cohen MS, Hastings II. Acute elbow dislocation: evaluation and management. *J Am Acad Orthop Surg*. 1998 Jan-Feb;6(1):15-23
4. Hildebrand KA, Patterson SD, King GJW. Acute elbow dislocation : Simple and complex. *Orthop Clin North Am*. 1999 Jan;30(1):63-79
5. Mayne IP, Wasserstein D, Modi CS, Henry PD, Mahomed N, Veillette C. The epidemiology of closed reduction for simple elbow dislocations and the incidence of early subsequent open reduction. *J Shoulder Elbow Surg*. 2015 Jan;24(1):83-90
6. Sparks SR, DeLaRosa J, Berga JJ, Hoyt DB, Owens EL. Arterial injury in uncomplicated upper extremity dislocations. *Ann Vasc Surg*. 2000 Mar;14(2):110-3
7. Carter SJ, Germann CA, Dacus AA, Sweeney TW, Peron AD. Othopedic pitfalls in the ED: neurovascular injury associated with posteriorelbowdislocations. *Am J Emerg Med*. 2010 Oct;28(8):960-5
8. Garrigues GE, Patel MB, Colletti TP, Weaver JP, Mallon WJ. Thrombosis of the brachial artery after closed dislocation of the elbow. *J Bone Joint Surg Br*. 2009 Aug;91(8):1097-9
9. Grimer RJ, Brooks S. Brachial artery damage accompanying closed posterior dislocation of the elbow. *J Bone Joint Surg Br*. 1985 May;67(3):378-81
10. Kumar JK, Sampath D, Reddy H, Motukoru V . Complete brachial artery transection following closed posterior elbow dislocation: a rare case report. *J Orthop Case Reports*. 2015 Oct-Dec; 5(4): 27-29
11. Ikeda K, Osamura N. Occult elbow dislocation with brachial artery injury. *J Clin Case Rep* 4:420
12. Lim SM, Chua GG, Asrul F, Yazid M. Posterior elbow dislocation with brachial artery thrombosis treated non-surgically: a case report. *Malays Orthop J*. 2017 Nov;11(3):63-65
13. Louis DS, Ricciardi JE, Spengler DM. Arterial injury: a complication of posterior elbow dislocation. *J Bone Joint Surg Am*. 1974 Dec;56(8):1631-6
14. Miyazaki AN, Fregoneze M, Santos PD, Do Val Sella G, Checchia CS, Checchia SL. Brachial artery injury due to closed posterior elbow dislocation: case report. *Rev Bras Ortop*. 2016 Feb 24;51(2):239-43
15. Platz A, Heinzelman M, Ertel W, Trentz O. Posterior elbow dislocation with associated vascular injury after blunt trauma. *J Trauma*. 1999 May;46(5):948-50
16. Reynders P, Broos P, Stoffelen D. Brachial artery injury in closed posterior elbow dislocation case report. *Acta Orthop Belg*. 2001 Feb;67(1):73-6
17. Kailash S, Shanmuganathan S. Anterior dislocation of elbow with neurovascular injury: a rare case report. *J Orthop Case Rep*. 2017 Jan-Feb;7(1):91-94
18. Ayel JE, Bonneville N, Lafosse JM, Pidhorz L, Al Homisy M, Mansat P, et al. Acute elbow dislocation with arterial rupture. Analysis of nine case. *Orthop Traumatol Surg Res*. 2009 Sep;95(5):343-51
19. Eijer H, Ballmer FT, Ris HB, Hertel R. Delayed diagnosis of a rupture brachial artery after posterior dislocation of the elbow. *Injury*. 1998 Jun;29(5):390-2
20. Yamaguchi K, Sweet FA, Bindra R, Morrey BF, Gelberman RH. The extraosseus and intraosseus arterial anatomy of the adult elbow. *J Bone Joint Surg Am*. 1997 Nov;79(11):1653-62
21. Perry MO, Thai ER, Shires GT. Management of arterial injuries. *Ann Surg*. 1971 Mar;173(3):403-8
22. Cataldi C, Ceri L, Colasanti GB, Moreschini F, Mondanelli N, Giannotti S. Complete brachial artery injury after open elbow dislocation: a case report. *Euromediterranean Biomedical J*. 2019,14(04)017-019.
23. Ergunes K, Yilik L, Ozsoyler I, Kestelli M, Ozbek C, Gurbuz A. Traumatic brachial artery injuries. *Tex Heart Inst J*. 2006;33(1):31-4
24. Bynoe RP, Miles WS, Bell RM, Greenwold DR, Haynes JL, Rush DS. Non invasive diagnosis of vascular trauma by duplex ultrasonography. *J Vasc Surg*. 1991 Sep;14(3):346-52
25. Henderson RS, Robertson IM. Open dislocation of the elbow with rupture of the brachial artery. *J Bone Joint Surg Br*. 1952 Nov;34-B(4):636-7
26. Brahmandam P, Plummer M, Modrall JG, Megison SM, Clagett GP, Valentine RJ. Hand ischemia associated with elbow trauma in children. *J Vasc Surg*. 2011 Sep;54(3):773-8
27. Mains DB, Freeark RJ. Report on compound dislocation of the elbow with entrapment of the brachial artery. *Clin Orthop Relat Res*. 1975 Jan-Feb;(106):180-5
28. Ekim H, Tuncer M. Management of traumatic brachial artery injuries: a report on 49 patients. *Ann Saudi Med*. 2009 Mar-Apr;29(2):105-9
29. Fox N, Rajani RR, Bokhari F, Chiu WC, Kerwin A, Seamon MJ, et al. Evaluation and management of penetrating lower extremity arterial trauma: an Eastern Association for the practice management guideline. *J Trauma Acute Care Surg*. 2012 Nov;73(5 Suppl 4):S315-20
30. Franz RW<sup>1</sup>, Shah KJ, Halaharvi D, Franz ET, Hartman JF, Wright ML. A 5-year review of management of lower extremity arterial injury at an urban level I trauma center. *J Vasc Surg*. 2011 Jun;53(6):1604-10
31. Zellweger R, Hess F, Nicol A, Omshoro-Jones J, Kahn D, Navsaria P. An analysis of 124 surgically managed brachial artery injuries. *Am J Surg*. 2004 Sep;188(3):240-5
32. Martin DJ, Fazzi UG, Leach WJ. Brachial artery transection associated with closed elbow dislocation of elbow. *Eur J Emerg Med*. 2005 Feb;12(1):30-2
33. Hackl M, Beyer F, Wegmann K, Leschinger T, Burkhart KJ, Muller LP. The treatment of simple elbow dislocation in adults. *Dtsch Arztebl Int*. 2015 May 1;112(18):311-9
34. Josefsson PO, Gentz CF, Johnell O, Wendeberg B. Surgical versus non-surgical treatment of ligamentous incurie following dislocation of the elbow joint. *J Bone Joint Surg Am*. 1987 Apr;69(4):605-8
35. Taylor F, Sims M, Theis JC, Herbison GP. Interventions for treating acute elbow dislocation in adults. *Cochrane Database Syst Rev*. 2012 Apr 18;(4):CD007908

36. Sheps DM, Hildebrand KA, Boorman RS. Simple dislocation of the elbow: evaluation and treatment. *Hand Clin.* 2004 Nov;20(4):389-404
37. Mehlhoff TL, Noble PC, Bennett JB, Tullos HS. Simple dislocation of the elbow in adult. *J Bone Joint Surg Am.* 1988 Feb;70(2):244
38. Hopf JC, Berger V, Krieglstein CF, Muller LP, Koslowsky TC. Treatment of unstable elbow dislocations with hinged elbow fixation – subjective and objective results. *J Shoulder Elbow Surg.* (2015) 24,250-257.

---

Received: 10 October 2020 - Accepted: 20 November 2020

**Corresponding Author**

\* Pari Carlotta

email addresses: carlotta.pari@alice.it