

R E V I E W

Upper extremity reconstruction following open surgical repair of giant arteriovenous fistula aneurysm: clinical case and systematic review of the literature

Tariq A. Almeray¹, Jeremie D. Oliver², Matthew S. Jorgensen³, Brian D Rinker⁴,
Houssam A. Farres³, Albert G. Hakaim³, Antonio J. Forte⁴

¹ Division of General Surgery, Mayo Clinic Florida, Jacksonville, FL; ² Mayo Clinic School of Medicine, Mayo Clinic, Rochester, MN; ³ Division of Vascular Surgery, Mayo Clinic Florida, Jacksonville, FL; ⁴ Division of Plastic Surgery, Mayo Clinic Florida, Jacksonville, FL

Summary. *Background:* Nearly 30% of arteriovenous fistulas (AVFs) located in the upper extremity for hemodialysis access result in short- and long-term adverse effects, such as rupture, necessitating emergent surgical management and extensive soft-tissue reconstruction. With this systematic review, we aimed to compile all reported open surgical techniques used for complicated AVF repair in the upper extremity, the respective soft-tissue reconstructive outcomes, and vascular patency rates at final follow-up. *Methods:* Using Ovid Medline/PubMed databases, we conducted a review of the English-language literature on AVF aneurysm surgical management in the upper extremity, filtered for relevance to open surgical technique and outcomes in vascular patency after aneurysmal repair at long-term follow-up (≥ 6 months postoperatively). We include a detailed case of surgical removal of a giant AVF aneurysm and subsequent flap elevation and reconstruction of the upper extremity. *Results:* Of 150 articles found in the initial search, 19 (from 2010-2017) met inclusion criteria. From the reviewed studies, 675 patients underwent open surgical repair of AVF aneurysm in the upper extremity. Surgical approaches included partial-to-full aneurysm excision, interposition graft, tubularized extracellular matrix, sutured and stapled aneurysmorrhaphy, and stent graft. Rates of vascular patency at repair site ranged from 47% to 100%, with a pooled average of 78% at 6 months or longer postoperatively. *Conclusions:* For plastic and hand surgeons, aneurysmal ligation and excision is feasible even in severe cases and is associated with overall good vascular and soft-tissue reconstructive outcomes in the upper extremity. (www.actabiomedica.it)

Key words: aesthetic outcome, AVF, AV fistula, dialysis, reconstruction; upper extremity

Introduction

Native arteriovenous fistula (AVF) became the first choice for permanent vascular access in patients with end-stage renal disease due to its lower rates of infection and thrombosis compared with other options (ie, catheter-based and arteriovenous graft) (1). However, almost 30% of AVFs result in short- and long-term adverse effects (eg, thrombosis, stenosis, and

aneurysmal degeneration) (2). Risk factors associated with AVF include hypertension, diabetes mellitus, peripheral arterial disease, early AVF puncture, and repeated puncture at the same site (3). AVF aneurysmal degeneration is a serious, yet underreported, adverse effect in the literature (4). Continuous high-pressure flow in the venous side and multiple punctures can lead to weakening of the venous wall and aneurysmal formation. AVF aneurysms can either be true (containing

all vessel wall elements) or a pseudoaneurysm (adjacent soft-tissue space communicating with the lumen of the access site) (5). AVFs proximal to the elbow are more prone to aneurysmal degeneration than those distal to the elbow (6). The incidence of aneurysmal degeneration complicating an AVF ranges from 5% to over 60% (4, 6). Moreover, major aneurysmal degeneration can lead to life-threatening adverse effects, including high cardiac output heart failure and rupture (7). The risk of aneurysm rupture increases with size, and emergent treatment is required. Therefore, timely management of aneurysmal AVF at an early stage is crucial to prevent life-threatening adverse effects and possibly salvage the AVF. In addition, plastic surgeons operating in the upper extremity are faced with the challenging task of reconstructing the investing soft-tissue structures to envelope the repaired AVF site. The purpose of this systematic review was to compile all reported open surgical techniques used for complicated AVF repair in the upper extremity, their respective soft-tissue reconstructive outcomes, and vascular patency rates at final follow-up. In addition, we provide a thorough case example of successful vascular and reconstructive surgical management of a giant AVF true aneurysm that was inducing high cardiac output heart failure. The patient's consent for publication was obtained.

Methods

Three authors independently conducted electronic literature searches using Ovid Medline/PubMed databases in July 2018, without timeframe limitations. Discrepancies were settled by the senior author. The following were used as either search terms or Medical Subject Headings in all combinations in the search strategy: "arteriovenous fistula," "upper extremity," "aneurysm," and "repair." The search results were collected and reviewed for potential inclusion. The reference lists of included studies were also searched for missed articles.

Eligibility criteria included clinical outcomes reported on surgical management of AVF aneurysm in the upper extremity that reported surgical technique used to repair aneurysm and postoperative outcome of vascular patency at final follow-up (≥ 6 months). Ab-

stracts, presentations, non-English language papers, animal studies, nonclinical studies, ex vivo studies, reviews and meta-analyses, and studies not reporting outcome data of at least 6 months of follow-up were excluded. See Figure 1 for a stepwise description of study selection and criteria for included articles.

Data collection from selected studies included the year of the study, authors, number of patients with confirmed AVF aneurysm who underwent surgical repair, specific surgical approach and techniques used in repairing the aneurysm, and vascular patency rate at final follow-up (≥ 6 months postoperatively). The hemodialysis access site patency rate included both primary and secondary patency.

Results

Of the 150 articles found in the preliminary literature search, 19 met inclusion criteria (8-26). From the reviewed studies, 675 total patients were identified to have undergone surgical repair of an AVF aneurysm in the upper extremity from 2010 to 2017. Surgical approaches to repair the aneurysms included partial-to-full aneurysm excision, interposition graft, tubularized extracellular matrix, sutured and stapled aneurysmorrhaphy, and stent graft. Rates of vascular patency at the repair site ranged from 47% to 100%, with a pooled average of 78% at postoperative follow-up of 6 months or longer. See Table 1 for all collected data from the included studies.

Illustrative Case

We present a case of a 71-year-old man with a medical history of coronary artery disease and end-stage renal disease secondary to hypertension, diabetes mellitus, and renal cancer. His surgical history included right nephrectomy and left brachiocephalic AVF complicated by aneurysmal formation, resulting in high cardiac output and pulmonary hypertension. He presented to our institution for management of the AVF aneurysm and the associated adverse effects. The patient had duplex ultrasound studies done that revealed extremely tortuous left brachiocephalic AVF and increased velocities in the cephalic arch, suggest-

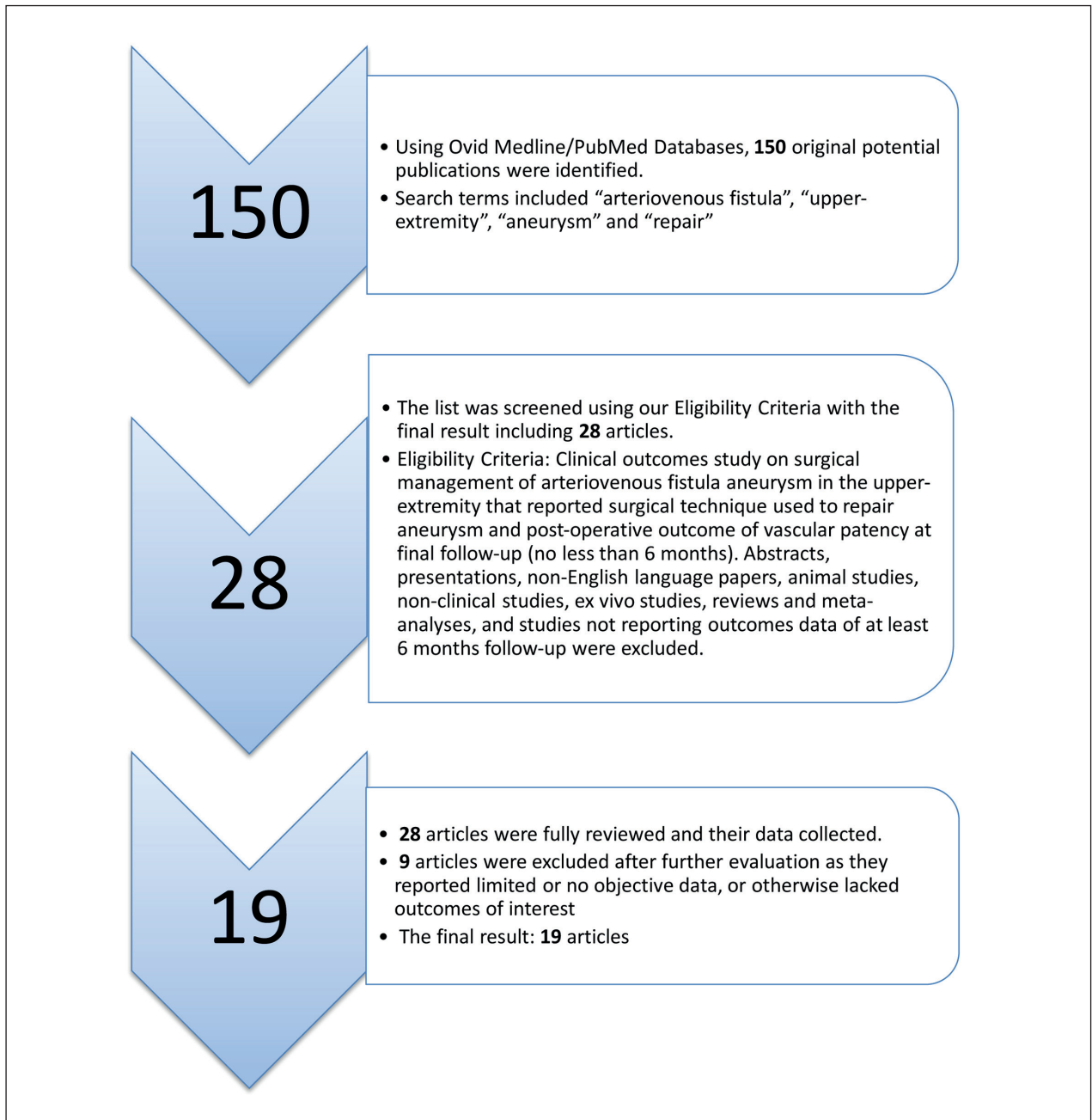


Figure 1. Flow Chart of systematic literature search criteria and results

ing central stenosis. Due to diffuse enlargement in his AVF, central stenosis on the left upper extremity, and severe AVF-related adverse effects (eg pain, high cardiac output, and pulmonary hypertension), a decision was made to look for another dialysis access location. We discussed a potential 2-staged procedure with the

patient; the first stage would be creating a right upper-extremity brachiocephalic AVF, and, once this matured, the second stage would be ligating and excising the left AVF. After successful creation of the right brachiocephalic AVF, the patient presented for left AVF ligation and excision (Figure 2).

Table 1. Reviewed studies illustrating surgical management techniques and patency outcomes in arteriovenous access aneurysm repair

Author	No. of Patients	Year	Surgical Technique	Patency at Final Follow-Up
Al-Thani et al (8)	40	2017	Excision and interposition graft	90% PAP at 14 months
Inui et al (9)	19	2017	Interposition graft and venoplasty	73% PAP at 6 months
Wang and Wang (10)	185	2017	Partial excision of aneurysm	96% PAP at 12 months
Baker and Malgor (11)	1	2017	Stapled aneurysmorrhaphy	PAP at 12 months
Dubose et al (12)	15	2016	Excision and tubularized extracellular matrix	100% PAP at 6.9 months
Uysal and Ceviker (13)	1	2016	Sutured aneurysmorrhaphy	PAP at 6 months
Patel et al (14)	48	2015	Sutured aneurysmorrhaphy	100% PAP at 6 months
Vo et al (15)	40	2015	Stapled aneurysmorrhaphy	88% PAP at 1 year
Powel et al (16)	35	2015	Long-segment plication	100% PAP at 10 months
Tozzi et al (17)	14	2014	Stapled aneurysmorrhaphy	86% PAP at 16.5 months
Fotiadis et al (18)	11	2014	Stent graft	73% SP at 6 months
Sigala et al (19)	31	2014	Autologous reconstruction	96% SP at 12 months
Rokosny et al (20)	62	2014	Reinforced aneurysmorrhaphy	80% PAP at 12 months
Zink et al (21)	38	2013	Stent graft	76.3 PAP at 6 months
Almehmi and Wang (22)	36	2012	Partial aneurysmectomy	56% PAP at 6 months
Belli et al (23)	26	2012	Excision and primary repair	52% PAP at 12 months
Pasklinsky et al (24)	23	2011	Excision and repair (vein or prosthesis)	47% PAP at 12 months
Berard et al (25)	38	2010	External reinforced aneurysmorrhaphy	93% PAP at 12 months
Pierce et al (26)	12	2007	Stapled reduction aneurysmoplasty	100% PAP at 10.5 months

Abbreviations: PAP, primary assisted patency; SP, secondary patency

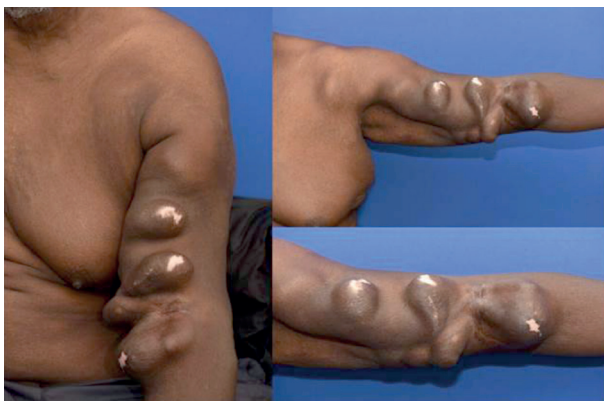

Figure 2. Preoperative photographs of brachiocephalic arteriovenous fistula aneurysmal degeneration

Surgical Technique

An S-shaped incision was created over the antecubital fossa, and the subcutaneous tissue was dissected to the level of the brachial artery. Proximal and distal control of the brachial artery was achieved. The AVF anastomosis with the brachial artery was isolated using a vascular vessel loop. The proximal portion of the AVF was clamped just above the anastomosis us-

ing a side-biting clamp. The brachial artery pulse was tested, as were the radial and ulnar pulses, and were found to be adequate. The anastomosis was then transected and the stump over-sewn using a 5-0 Prolene suture (Ethicon Inc) in a continuous vertical mattress fashion (Figure 3).

The distal portion of the fistula and the aneurysmal component were opened, and all remaining wall thrombus was removed. The aneurysm was dissected both proximally and distally, ligated using 2-0 Vicryl sutures (Ethicon Inc), and resected, measuring approximately 80 cm (Figure 4).

The wound was then thoroughly irrigated, and 2 Jackson-Pratt drains were placed. Next, we overlapped bilateral skin flaps to assess for the amount of skin redundancy, which was then resected using a #15 blade. We proceeded with closure by approximating the deeper tissues and dermis using 2-0 Vicryl sutures, and the skin edges using staples; a sterile dressing was applied. The patient tolerated the procedure well and was transferred to the recovery room in stable condition. At 2-month follow-up, the patient had no complaints and the wound was healing properly (Figure 5).

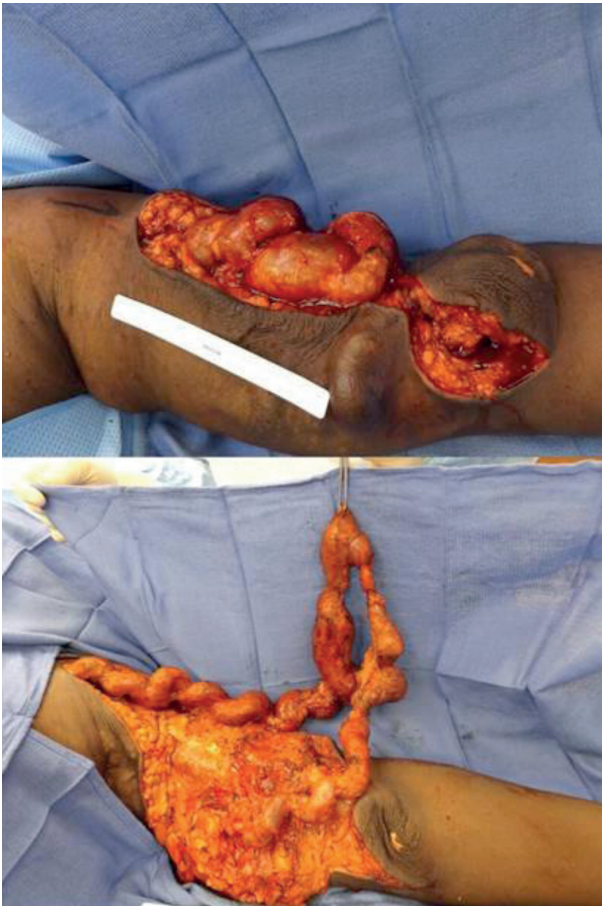

Figure 3. Intraoperative photographs of the giant arteriovenous fistula with s-shaped incision to release aneurysm

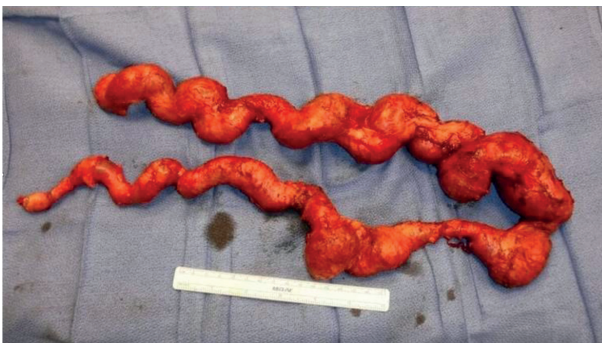


Figure 4. Excised arteriovenous fistula pathologic specimen

Discussion

Hemodialysis vascular access adverse effects account for more than 20% of hospitalizations for patients with end-stage renal disease (3). The adverse

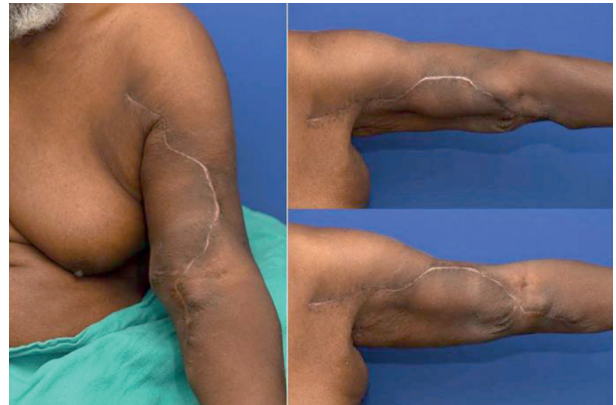

Figure 5. Postoperative photographs 2 months after open surgical arteriovenous fistula aneurysm repair

effects of vascular access sites in the upper extremity include thrombosis, stenosis, steal syndrome, infection, and aneurysmal degeneration. The incidence of aneurysm formation in vascular access sites is variable, but can be over 60% (4-7). Multiple factors may play a substantial role in aneurysmal degeneration in AVF patients, including repetitive stress due to frequent cannulation, venous hypertension, and transplantation. In this case, we report that high turbulent flow over time and central venous stenosis likely contributed to aneurysmal degeneration. These aneurysms can ultimately cause skin breakdown, thrombosis, pain, fistula rupture, infection, and aesthetic dissatisfaction. Plastic surgeons comfortable operating in the upper extremity and trained in extensive microvascular reconstructive surgery possess the skillset necessary for successful repair of AVF aneurysmal degeneration and the overlying soft-tissue defects of the upper extremity to comprehensively treat the functional, reconstructive, and aesthetic components of these cases.

From a reconstructive standpoint, the challenge stems from the overall size of these defects after full excision of the aneurysm vasculature, as the S-shaped incision demonstrated in our case. This leaves a large area to be covered by overlapping bilateral skin flaps. Intraoperative assessment of skin redundancy immediately following aneurysm resection allows for proper analysis of the overall quality and blood supply of the remaining skin of the upper extremity overlying the defect. Multilayered approximation of the deep and superficial skin layers following the incision course can

restore the external aesthetic components of the upper extremity, even after a degenerative event like AVF aneurysm, as is seen in the images included in our case.

Given the paucity of published data and techniques in reconstructing the upper extremity in the setting of massive AVF aneurysm resection, we wish to draw a parallel in this topic to general upper-extremity reconstruction following ablative surgery. Whether resecting a massive aneurysmal dilatation or a solid tumor of the upper extremity, the unifying goal remains to restore both function and form, considering remaining anatomic structures following resection of aberrant tissue. Assuming the underlying bony framework of the upper extremity has remained intact with all associated tendinous and ligamentous connections, the ultimate focus of these resections revolves around achieving adequate soft-tissue coverage of viable, vascularized tissue to restore the defect. In the event that the native tissue locally surrounding the resected portion is not sufficient to provide adequate closure, flap reconstruction is likely indicated.

Alternatively, as is presented in our case, the incision can be executed in a large S-shape, which is of great utility in approaching an AVF aneurysm of this dimension, given the anatomic location and course of arteriovenous anastomotic site being resected. This large S-shaped incision was made to allow for complete resection of all portions of the AVF affected by aneurysmal dilatation, and to prepare the longitudinally extensive site for optimal soft-tissue coverage. Performing this incision allowed for us to restore the natural form of the upper extremity and create a closure site with minimal tension to encourage proper healing of the delicate soft-tissue covering. While this surgical approach to AVF aneurysm management is not well described in plastic and reconstructive surgery literature, the authors strongly advocate for the involvement of a plastic surgeon in cases of extensive upper-extremity soft-tissue reconstruction following AVF aneurysm resection given the well-cited experience of plastic surgeons in achieving reliable soft-tissue coverage of large defects. We hope this comprehensive report and case example can further stimulate clinical and scholarly work toward this approach in the plastic surgery community.

The incidence of aneurysmal rupture of the AVF can be up to 5.3% (5, 6). Kidney Disease Outcomes

Quality Initiative recommended surgical intervention and avoidance of aneurysmal segment cannulation to decrease the risk of adverse effects (7). Multiple treatment options have been described in the literature, including open plication, excision and primary anastomosis, excision and interposition venous or polytetrafluoroethylene graft, endovascular intervention, and ligation with excision (Table 1). Despite the advances in endovascular techniques, open surgical management of these aneurysms remains the main treatment modality, partially due to the higher infectious adverse effects associated with stent graft and covered stent use. Multiple studies have described different techniques to salvage the AVF and repair the aneurysmal portions by plication and partial aneurysm excision with acceptable outcomes and patency rates (15, 24, 26). Pierce et al (26) used longitudinal stapling in 12 patients with aneurysmal AVF to reduce the aneurysmal diameter. Vo et al (15) also reported staple aneurysmorrhaphy in 50 patients, with an 85% secondary patency rate at 3-year postoperative follow-up. In staple aneurysmorrhaphy, reducing the veins to normal adjacent diameter, fixing central stenosis, and having healthy skin coverage are key factors for a successful outcome. However, in our case, due to the central venous stenosis and severity of the patients' symptoms (high cardiac output, pulmonary hypertension, and diffuse aneurysmal degeneration), surgical ligation and excision was preferred. Similar to our case, Pasklinsky et al (24) reported ligation and excision in 30% of their patients due to severe symptoms. Since our patient was on dialysis, we elected to create another dialysis access (right brachiocephalic AVF) and wait until it matured to then ligate and excise the prior access in order to not interrupt the patient's dialysis therapy.

Limitations of this systematic review of the literature on AVF aneurysm surgical treatment approaches and outcomes include the heterogeneity of reported techniques and outcomes, and, by default, the lack of ability to compare the multiple surgical approaches. Thus, this systematic review is primarily focused on reporting the techniques and outcomes in managing AVF aneurysms in the upper extremity to increase awareness of this treatment modality in the plastic and vascular surgery communities, both for function and aesthetic benefit to patients. A shortcoming in the cur-

rent body of literature on this topic is a lack of reported reconstructive outcomes in the patients undergoing extensive soft-tissue reconstruction after aneurysm repair. However, we have attempted to supplement this review by discussing our approach to upper-extremity reconstruction in our case example, and sharing the postoperative images to demonstrate reconstructive and aesthetic outcome. Comparative studies should be conducted, analyzing the relative efficacy of specific surgical approaches (ie, interposition graft vs stent vs tubularized acellular matrix) to better understand the potential benefits of surgical management of these aneurysms. Future studies should also aim to maintain a longer follow-up time with larger cohorts to properly evaluate the long-term benefits of surgical repair of these aneurysms in regards to maintaining patency of the vessels over time to continually provide a vascular access point for hemodialysis.

Conclusion

Despite AVF in the upper extremity being the preferred method of vascular access for hemodialysis, a number of adverse effects can arise, including aneurysmal degeneration. In a subset of patients, aneurysmal degeneration can be diffuse and severe, increasing the complexity of surgical intervention and reconstruction of the upper extremity to salvage the AVF. For plastic and hand surgeons, aneurysmal ligation and excision prior to layered coverage of the sizeable defect is feasible, even in severe cases, and is associated with overall good vascular and soft-tissue reconstructive outcomes in the upper extremity. We advocate for increased involvement of plastic and reconstructive hand surgeons in these challenging cases of upper-extremity aneurysmal degeneration of AVF dialysis sites, as these patients can recover well from a vascular and aesthetic reconstructive standpoint under the care of an experienced plastic surgeon.

Conflict of interest: Each author declares that he or she has no commercial associations (e.g. consultancies, stock ownership, equity interest, patent/licensing arrangement etc.) that might pose a conflict of interest in connection with the submitted article

References

1. Bachleda P, Utikal P, Kalinova L, Vachalova M. Surgical remodelling of haemodialysis fistula aneurysms. *Ann Acad Med Singapore* 2011; 40: 136-9.
2. Fitzgerald JT, Schanzer A, Chin AI, McVicar JP, Perez RV, Troppmann C. Outcomes of upper arm arteriovenous fistulas for maintenance hemodialysis access. *Arch Surg* 2004; 139: 201-8.
3. Georgiadis GS, Lazarides MK, Panagoutsos SA, et al. Surgical revision of complicated false and true vascular access-related aneurysms. *J Vasc Surg* 2008; 47: 1284-91.
4. Huber TS, Carter JW, Carter RL, Seeger JM. Patency of autogenous and polytetrafluoroethylene upper extremity arteriovenous hemodialysis accesses: a systematic review. *J Vasc Surg* 2003; 38: 1005-11.
5. Mudoni A, Cornacchiari M, Gallieni M, et al. Aneurysms and pseudoaneurysms in dialysis access. *Clin Kidney J* 2015; 8: 363-7.
6. Haimov M, Baez A, Neff M, Slifkin R. Complications of arteriovenous fistulas for hemodialysis. *Arch Surg* 1975; 110: 708-12.
7. Valenti D, Mistry H, Stephenson M. A novel classification system for autogenous arteriovenous fistula aneurysms in renal access patients. *Vasc Endovascular Surg* 2014; 48: 491-6.
8. Al-Thani H, El-Menyar A, Al-Thani N, et al. Characteristics, Management, and Outcomes of Surgically Treated Arteriovenous Fistula Aneurysm in Patients on Regular Hemodialysis. *Ann Vasc Surg* 2017; 41: 46-55.
9. Inui T, Boulom V, Bandyk D, Lane JS, 3rd, Owens E, Barleben A. Dialysis Access Hemorrhage: Access Rescue from a Surgical Emergency. *Ann Vasc Surg* 2017; 42: 45-9.
10. Wang S, Wang MS. Successful use of partial aneurysmectomy and repair approach for managing complications of arteriovenous fistulas and grafts. *J Vasc Surg* 2017; 66: 545-53.
11. Baker J, Malgor RD. Concomitant Staple Aneurysmorrhaphy and Flow-Calibrated Arteriovenous Fistula Banding Over a Coronary Dilator to Treat Hand Steal Syndrome. *Vasc Endovascular Surg* 2017; 51: 307-11.
12. DuBose JJ, Fortuna GR, Charlton-Ouw KM, et al. Utility of a tubularized extracellular matrix as an alternative conduit for arteriovenous fistula aneurysm repair. *J Vasc Surg* 2016; 63: 446-52.
13. Uysal D, Ceviker K. A simple aneurysmorrhaphy technique for the management of venous aneurysm: a case of massive hemorrhage at an arteriovenous fistula. *J Vasc Access* 2016; 17: e85-6.
14. Patel MS, Street T, Davies MG, Peden EK, Naoum JJ. Evaluating and treating venous outflow stenoses is necessary for the successful open surgical treatment of arteriovenous fistula aneurysms. *J Vasc Surg* 2015; 61: 444-8.
15. Vo T, Tumbaga G, Aka P, Behseresh J, Hsu J, Tayarrah M. Staple aneurysmorrhaphy to salvage autogenous arteriovenous fistulas with aneurysm-related complications. *J Vasc Surg* 2015; 61: 457-62.

16. Powell A, Wooster M, Carroll M, et al. Long-segment plication technique for arteriovenous fistulae threatened by diffuse aneurysmal degeneration: short-term results. *Ann Vasc Surg* 2015; 29: 1327-31.
17. Tozzi M, Franchin M, Ietto G, et al. A modified stapling technique for the repair of an aneurysmal autogenous arteriovenous fistula. *J Vasc Surg* 2014; 60: 1019-23.
18. Fotiadis N, Shawyer A, Namagondlu G, Iyer A, Matson M, Yaqoob MM. Endovascular repair of symptomatic hemodialysis access graft pseudoaneurysms. *J Vasc Access* 2014; 15: 5-11.
19. Sigala F, Kontis E, Sassen R, Mickley V. Autologous surgical reconstruction for true venous hemodialysis access aneurysms--techniques and results. *J Vasc Access* 2014; 15: 370-5.
20. Rokosny S, Balaz P, Wohlfahrt P, Palous D, Janousek L. Reinforced aneurysmorrhaphy for true aneurysmal haemodialysis vascular access. *Eur J Vasc Endovasc Surg* 2014; 47: 444-50.
21. Zink JN, Netzley R, Erzurum V, Wright D. Complications of endovascular grafts in the treatment of pseudoaneurysms and stenoses in arteriovenous access. *J Vasc Surg* 2013; 57: 144-8.
22. Almehti A, Wang S. Partial aneurysmectomy is effective in managing aneurysm-associated complications of arteriovenous fistulae for hemodialysis: case series and literature review. *Semin Dial* 2012; 25: 357-64.
23. Belli S, Parlakgumus A, Colakoglu T, et al. Surgical treatment modalities for complicated aneurysms and pseudoaneurysms of arteriovenous fistulas. *J Vasc Access* 2012; 13: 438-45.
24. Pasklinsky G, Meisner RJ, Labropoulos N, et al. Management of true aneurysms of hemodialysis access fistulas. *J Vasc Surg* 2011; 53: 1291-7.
25. Berard X, Brizzi V, Mayeux S, et al. Salvage treatment for venous aneurysm complicating vascular access arteriovenous fistula: use of an exoprosthesis to reinforce the vein after aneurysmorrhaphy. *Eur J Vasc Endovasc Surg* 2010; 40: 100-6.
26. Pierce GE, Thomas JH, Fenton JR. Novel repair of venous aneurysms secondary to arteriovenous dialysis fistulae. *Vasc Endovascular Surg* 2007; 41: 55-60.
27. Saint-Cyr M, Langstein HN. Reconstruction of the hand and upper extremity after tumor resection. *J Surg Oncol* 2006; 94: 490-503.
28. Tung TC, Wang KC, Fang CM, Lee CM. Reverse pedicled lateral arm flap for reconstruction of posterior soft-tissue defects of the elbow. *Ann Plast Surg* 1997; 38: 635-41.

Received: 13 May 2019

Accepted: 22 May 2019

Correspondence:

Antonio J. Forte, MD, PhD, MS,
Division of Plastic Surgery, Mayo Clinic,
4500 San Pablo Rd, Jacksonville, FL 32224
Tel. 904-953-2073
Fax: 904-953-7368
E-mail: ajvforte@yahoo.com.br