

C A S E R E P O R T

Asymmetric bilateral hip dislocation in young man: a case report

Stefano Giaretta, Andrea Silvestri, Alberto Momoli, Gian Mario Micheloni

Orthopedic and Traumatology Unit, Ospedale San Bortolo, Vicenza, Italy

Summary. Bilateral hip dislocation is a rare event, asymmetric dislocation is even rarer. Due to the intrinsic stability of the hip joint these lesions usually follow a high energy trauma. Because of the common associated lesions, the initial clinical assessment should be performed thoroughly. CT scan rather than x-rays offers a complete survey of these possible associated injuries such as thoracic or abdominal bleedings, neurologic lesions or fractures directly associated with the hips dislocations. The first goal should be reduction of the dislocation to prevent avascular necrosis (AVN) of the femoral head and arthritis. We report a case of a young man with right anterior hip dislocation and left posterior hip dislocation with associated fracture of the posterior wall. (www.actabiomedica.it)

Key words: asymmetrical hip dislocation, traumatic hip dislocation, bilateral dislocation

Introduction

Usually hip dislocations occur after traumatic injury and 85-90% of these are posterior dislocations (1). Bilateral dislocations account for 1% of all hip dislocations (2). In the English-language literature only 29 documented cases of this dislocation pattern can be found (3-9).

Case report

A 23 year-old male had a car accident at approximately 70 km/h. He was brought at the emergency department (E.D.) within 2 hours after the accident. At the arrival he was hemodynamically stable but with a GCS=3. He reported several abrasions all over the body and had evident deformations of both lower extremities. The left hip was shortened, adducted and internally rotated, the other one was shortened, abducted, externally rotated and flexed at 30°. Both the extremities had limited range of motion (the former limited external rotation, the latter limited internal ro-

tation). The lower limbs were warm and the peripheral pulses were strong and symmetrical.

Initial imaging included computer tomography (CT) of brain, thorax, abdomen and pelvis.

CTs were negative for hemorrhages but revealed a fracture of the left clavicle and an asymmetric bilateral hip dislocation.

The right hip was anteriorly dislocated with no associated fractures. The left hip was posteriorly dislocated with a fracture of the posterior wall (Fig. 1)

The right hip was successfully reduced in the E.D. whereas the left one couldn't be reduced with external maneuvers (Fig. 2). In the following days the patient was diagnosed with diffuse axonal injury with a series of encephalic CT scans.

In consequence of the neurological condition the left hip was surgically reduced and the fracture of the left pelvis fixed fifteen days later together with the clavicle fracture. The posterior wall fracture was fixed with two plates using a posterior approach.

A new pelvis radiograph showed the good outcome of the operation (Fig. 3).

On a pelvis radiograph taken 6 months after the

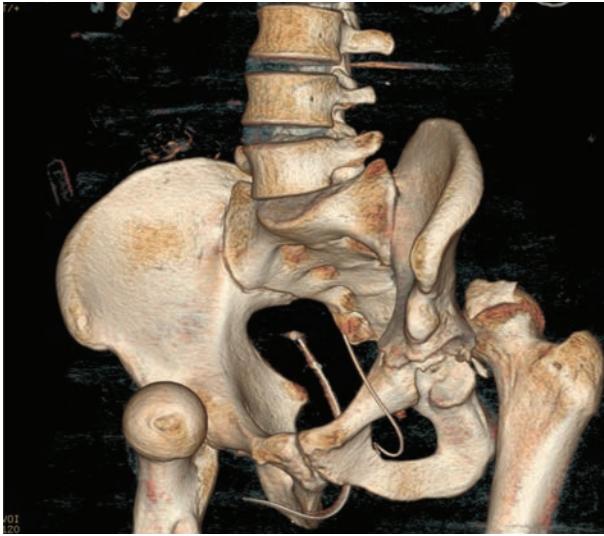


Figure 1. Preoperative TC

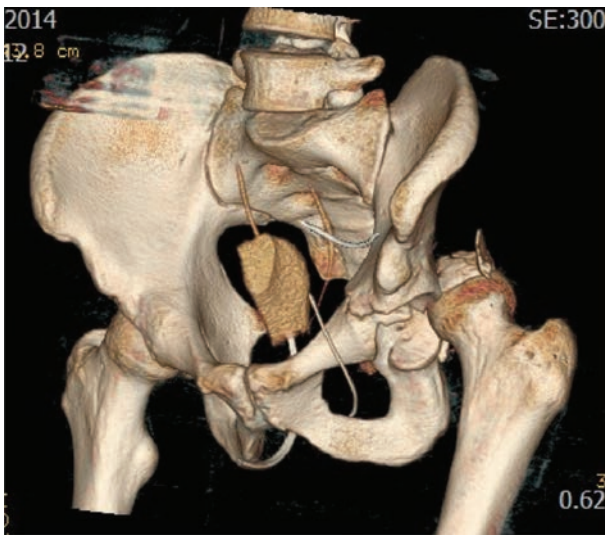


Figure 2. TC after reduction Right Hip

accident the right hip showed no pathological signs whereas the left one showed signs of necrosis of the femoral head (Fig. 4). Because of the neurological situation a clinical assessment could not be performed.

Discussion

Due to the intrinsic stability of the hip joint this type of lesions are usually caused by a high energy trauma such as a car or motorbike accident (10-14).

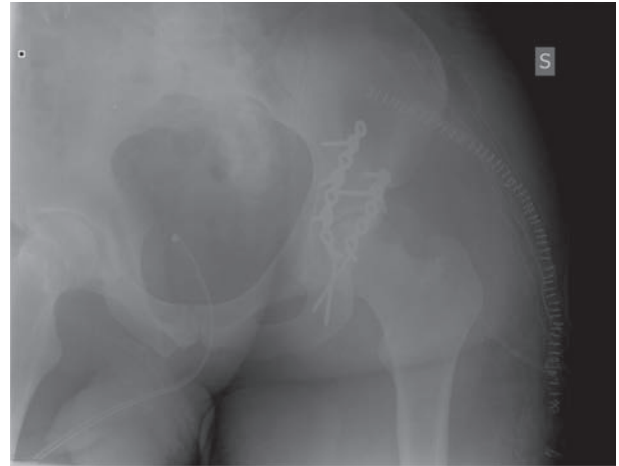


Figure 3. Post-op x-rays

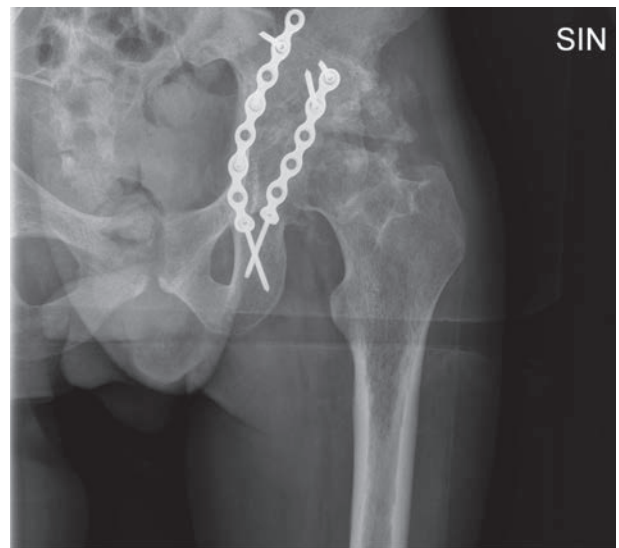


Figure 4. Six months follow up x-rays

The hip joint bases his stability on different elements like the depth of the acetabulum increased by the labrum, a thick capsule and a strong group of muscles. There's also an efficient ligamentous system represented by the capsular ligaments and the teres ligament.

Usually these types of lesions are caused by a dashboard injury (15). A crash with an abducted hip leads to an anterior dislocation whereas an impact with an adducted hip cause a posterior dislocation (16, 17-19).

Associated injuries are always to be looked for carefully. They include femoral fractures (shaft, neck, heads), pelvis and acetabular fractures, fractures of knee, ankle and foot (20-22).

Abdominal, chest and head injuries are also reported to be associated with hip dislocations (22-25), similar to our patient who reported a diffuse axonal injury and a fracture of the left clavicle.

Clinical examination is the most important element to diagnose a hip dislocation.

In a posterior dislocation the hip is internally rotated, flexed and adducted whereas in an anterior dislocation the hip is externally rotated and abducted. A plain radiography of the pelvis is enough to confirm the diagnosis but with a computed tomography associated fractures can be fully examined.

The reduction of the dislocation must be performed as soon as possible to prevent complications such as avascular necrosis (AVN) the incidence of which increases if the reduction is delayed (23).

A closed reduction should always be the first choice unless there are associated hip or pelvis fractures.

A surgical approach is chosen in cases of irreducible dislocation or non concentric reductions.

Usually in posterior dislocations a Kocher-Langenbach approach is used, anterior dislocations are addressed with an anterior or antero-lateral approach (26). In addition to provide a concentric a stable reduction is important to remove intra-articular bone or cartilage fragments that interpose between the articular surfaces. An arthroscopic approach can be used if the only aim is to remove little fragments without fixing them. After closed reduction weight bearing should be avoided for only 2 weeks starting mobilization as soon as the pain permits (27).

Hip mobilization should be started immediately and weight bearing allowed after 6-8 weeks.

Poorer outcomes are associated with posterior dislocations, associated injuries and a delayed time of reduction (>6 hours) (1, 28-30).

All these elements may have an effect in causing AVN and arthritis which are associated to poor clinical outcomes.

Conclusions

In the case reported the right hip was treated early with closed reduction and at 6 months x-rays shows no pathological signs, for the left one an open reduction and internal fixation were performed after fifteen days because of major neurological problems and at 6 months x-rays shows clear signs of AVN. The time of reduction and the associate lesions could explain the different outcome between the two hips.

References

1. DeLee JC. Fractures and dislocations of the hip. In: Rockwood Ca Jr, Green DP, Bucholz R: Fractures in Adults (4th ed). Philadelphia; Lippincott-Raven, 1996, Vol 2 pp. 1756-1803
2. Epstein HC. Traumatic dislocations of the hip. Clin Orthop Relat Res 1973;92:116-42.
3. Hamilton, David A. Jr. Bilateral asymmetric hip dislocation: a case series and literature review of a rare injury pattern. Journal of Trauma and acute care Surgery 73(4):1018-1023, oct 2012
4. Olcay E, Adanir O, Ozden E, Baris A. Bilateral asymmetric traumatic hip dislocation with bilateral acetabular fracture: case report. Ulus Trauma Acil Cerrahi Derg. 2012 Jul; 19(4): 355-7
5. Janojia RK, Patra SR, Gupta S. Bilateral asymmetric dislocations of hip joints: an unusual mechanism of injury. Case report Orthop. 2013; 2013: 694359
6. Lo BM, Asymmetrical bilateral hip dislocation. West J Emerg Med. 2013 Sep; 14(5): 452
7. Buckwalter J, Westerlind B, Karam M. Asymmetric Bilateral Hip Dislocations: A Case Report and Historical Review of the Literature. Iowa Orthop J. 2015;35:70-91.
8. Alshammari A, Alanazi B, Almogbil I, Alfayez SM. Asymmetric bilateral traumatic hip dislocation: A case report. Ann Med Surg (Lond). 2018;32:18-21. Published 2018 Jun 26. doi:10.1016/j.amsu.2018.06.008
9. Paša L1, Veselý R, Kelbl M. Bilateral Asymmetric Traumatic Dislocation of Hip Joints Acta Chir Orthop Traumatol Cech. 2017;84(1):66-69.
10. Deakin DE, Porter K. Traumatic hip dislocation in adults. Trauma. 2009;11(3):189-197.
11. Giordano V, Costa PR, Esteves JD, Félix J, Júnior, Franklin CE, Amaral NP. Luxações traumáticas do quadril em pacientes esqueléticamente maduros. Rev Bras Ortop. 2003;38(8):462-472.
12. Onyemaechi NO, Eyichukwu GO. Traumatic hip dislocation at a regional trauma centre in Nigeria. Niger J Med. 2011;20(1):124-130.

13. Tornetta P, Mostafavi HR. Hip Dislocation: Current Treatment Regimens. *J Am Acad Orthop Surg*. 1997;5(1):27-36
14. Lima, Luciana Cascão et al. "Epidemiology of Traumatic Hip Dislocation in Patients Treated in Ceará Brazil." *Acta Ortopedica Brasileira* 22.3 (2014): 151-154. PMC. Web. 11 Feb. 2015.
15. Epstein Hc, Wiss DA, Cozen L. Posterior fracture-dislocation of the hip with fracture of the femoral head. *Clin Orthop*. 1985; 201: 9-17.
16. Hougaard K, Thomsen PB Traumatic posterior fracture-dislocation of the hip with fracture of the femoral head or neck, or both. *J Bone Joint Surg Am*. 1988 Feb; 70(2):233-9.
17. Goddard NJ. Classification of traumatic hip dislocation. *Clin Orthop Relat Res* 2000;(377):11-4.
18. Phillips AM, Konchwalla A. The pathologic features and mechanism of traumatic dislocation of the hip. *Clin Orthop Relat Res* 2000;(377):7-10.
19. Brooks RA, Ribbans WJ. Diagnosis and imaging studies of traumatic hip dislocations in the adult. *Clin Orthop Relat Res* 2000;(377):15-23
20. Gillespie WJ. The incidence and pattern of knee injury associated with dislocation of the hip. *J Bone Joint Surg Br*. 1975 Aug;57(3):376-8.
21. Suraci AL. Distribution and severity of injuries associated with hip dislocations secondary to motor vehicle accidents. *J Trauma*. 1986 May;26(5):458-60.
22. Wu CC, Shih CH, Chen LH. Femoral shaft fractures complicated by fracture-dislocations of the ipsilateral hip. *J Trauma*. 1993 Jan;34(1):70-5.
23. Hak, David J. MD; Goulet, James A. MD Severity of Injuries Associated with Traumatic Hip Dislocation as a Result of Motor Vehicle Collisions *The Journal of Trauma* 1999; (47): 60-63.
24. Yue, James J.; Sontich, John K; Miron, Stefan D. et al. Blood flow Changes to the femoral head after acetabular fracture or dislocation in the acute injury and perioperative periods. *J. of orthopaedic Trauma*, 2001 15(3): 170-176
25. Jaskulka RA, Fisher G, Fenzl G. Dislocation and fracture-dislocation of the hip. *J Bone Joint Surg Br*. 1991; 73: 465-469.
26. Sanders S, Tejwani N. Traumatic hip dislocation, a review. *Bull NYU Hosp Jt Dis*. 2010; 68(2): 91-96
27. Yang EC, Cornwall R. Initial treatment of traumatic hip dislocations in the adult. *Clin Orthop Res* 2000 (377): 24-31
28. Epstein HC. Posterior fracture-dislocations of the hip: long term follow up. *J Bone J Surg Am* 56:1103-1127
29. Rodriguez-Merchan EC. Osteonecrosis of the femoral head after hip dislocation in the adult. *Clin Orthop Relat Res* 2000; (377): 68-77
30. Alonso JE, Volgas DA, Giordano V et al. A review of the treatment of hip dislocations associated with acetabular fractures. *Clin Orthop Res* 2000;(377): 32-43

Received: 26 October 2018

Accepted: 10 December 2018

Correspondence:

Stefano Giaretta, MD

Orthopedic and Traumatology Unit,

Ospedale San Bortolo – Vicenza, Italy

E-mail: stefano.giaretta@gmail.com