

C A S E R E P O R T

Isolated superficial vein thrombosis in multiple thrombotic defects

Carmine Siniscalchi, Anna Rocci

Angiology and Internal Medicine Unit, Department of Internal and Emergency Medicine, Parma University Hospital, Parma, Italy

Summary. Superficial Vein Thrombosis (SVT) is generally a benign, self-limited disorder; however, when larger veins are involved, propagation into deep vein system can occur. Thrombophilic disorders denote several risk factors that predispose individuals to develop venous thromboembolism. It includes inherited thrombophilia, acquired thrombophilia and hyperhomocysteinemia. For thrombophilic patients who develop SVT, the current guidelines don't clarify for how long time anticoagulation therapy must be performed. We describe a case of SVT in a patient with multiple thrombotic defects, for which we starting Fondaparinux 2.5 mg/die and stopped it when the SVT was solved. During the follow-up period (eighteen months) no Deep Vein Thrombosis or Superficial Vein Thrombosis were detected. Clinical surveillance seems to have been the best strategy for this patient. We believe that this single case report emphasizes the needed of prospective studies to verify the risk of thromboembolic recurrence in thrombophilic patients with SVT. (www.actabiomedica.it)

Key words: anticoagulation, low molecular weight heparin, phlebitis, thrombophilia, ultrasound, symptomatic, risk factors

Abbreviation list

SVT=Superficial Vein Thrombosis
APS=Antiphospholipid Syndrome
VTE=Venous Thromboembolism
aPLs=Antiphospholipid Antibodies
DVT=Deep Vein Thrombosis
aCL=Anticardiolipin
B2GPI=beta 2-glycoprotein I
LAC=Lupus Anti Coagulant
Ig=Immunoglobulin
PE=Pulmonary Embolism

Background

Superficial Vein Thrombosis (SVT) is generally a benign, self-limited disorder; however, when larger veins are involved, propagation into deep vein system, as Deep Vein Thrombosis (DVT) and even Pulmonary Embolism (PE) can occur (1). Treatment is aimed at relieving local symptoms and preventing thromboem-

bolic complications. SVT has been less well studied than DVT but is estimated to occur more often (2, 3). It usually affects lower limbs, often involves varicose veins. Can be unprovoked or associated with several conditions such as malignancy, chronic venous insufficiency, pregnancy or estrogen therapy, sclerotherapy, obesity, history of VTE, long-distance travel, thrombophilia (2-4).

Thrombophilic disorders denote several risk factors that predispose individuals to develop venous thromboembolism. It includes inherited thrombophilia, acquired thrombophilia and hyperhomocysteinemia.

Regarding the inherited form, mutation of Factor V gene is the most common (more often in the heterozygous form), while the prothrombin gene mutation, protein S, protein C, and antithrombin deficiencies account for most of the remaining cases.

The most common acquired form of thrombophilia is the antiphospholipid syndrome (APS). APS

is characterized by venous or arterial thrombosis and/or pregnancy morbidity in the presence of persistent laboratory evidence of antiphospholipid antibodies (aPLs) (5). In APS patients can present with both venous and arterial thrombosis.

Severe hyperhomocysteinemia is generally due to a rare autosomal recessive disorder characterized by severe elevations in plasma and urine homocysteine concentrations. It is related to MHTFR gene mutation in homo or heterozygosis. There is increasing evidence that hyperhomocysteinemia is a risk factor for VTE (6).

For thrombophilic patients who develop SVT, the current guidelines don't clarify for how long time anticoagulation therapy must be performed.

Case Report

A 48 years-old woman was admitted to our ward for erythema and swelling of the left lower limb, suspected of DVT. We perform thrombophilic screening and a venous ultrasound of the lower limbs.

Thrombophilic screening highlighting heterozygous mutation for the Factor V gene, the homozygous mutation for MTHFR C677T gene, the increase of anti-beta 2-glycoprotein I (B2GPI) antibody IgM and anti-cardiolipin (aCL) antibody IgM. Remaining tests were in the normal range (Table S1 summarize all blood test performed). The venous ultrasound doesn't highlight any acute thrombotic events. We don't start any anticoagulation therapy.

As current guidelines recommended, the laboratory tests for aPLs were repeated at 12 weeks. A downward trend was observed (Figure 1, Table 2).

Table 1. Blood tests performed at the first clinical observation

Blood tests performed	Patient values	Normal values
WBC	5,91	4000-10000/mm ³
RBC	3,57	3900000-5200000/mm ³
HB	11,7	12-16 g/dl
HT	34,5	36-46%
PLT	178000	150-400000/mm ³
PT INR	0,94	0.86-1.14
aPTT ratio	1,01	0.82-1.18
ATIII	124	>83%
C-Protein	106	>70%
S-Protein	85	>60%
aCL IgM	45,5	< 10 MPL-U/ml
aCL IgG	2,42	< 10 GPL-U/ml
B2GPI IgM	59,6	<7 U/ml
B2GPI IgG	1,76	<7 U/ml
LAC	0,97	<1.2 ratio
Leiden's Factor	Heterozygous mutation	Omozygous normal
Factor II	Omozygous normal	Omozygous normal
Homocysteinemia	12,5	<15 micromol/L

WBC=White Blood Cell; RBC=Red Blood Cell; HB=Hemoglobin; HT=Hematocrit; PLT=Platelets; PT=Prothrombin Time; aPTT=activated Partial Thromboplastin Time; INR=International Normalized Ratio; LAC=Lupus Anti Coagulant; aCL=Anticardiolipin; B2GPI=beta 2-glycoprotein I; ATIII=Antithrombin III; Ig=immunoglobulin

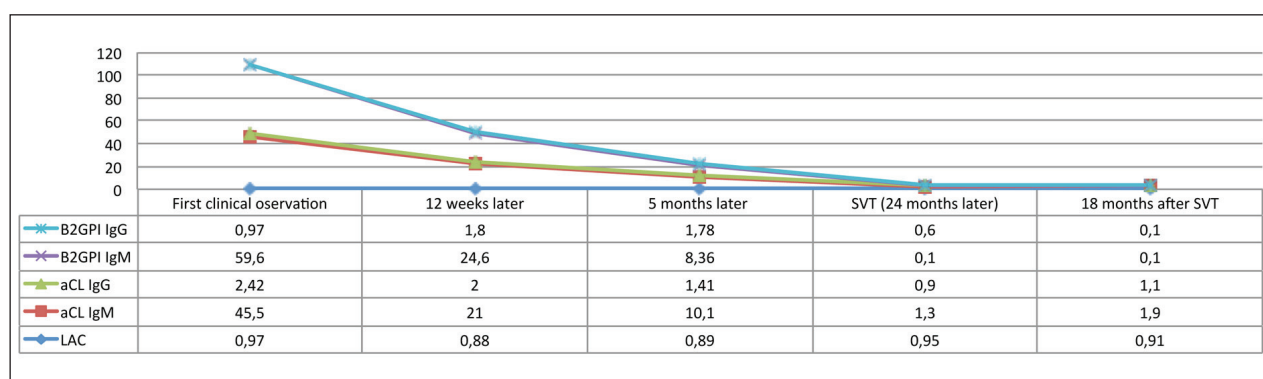


Figure 1. Trend of laboratory antiphospholipid antibodies; B2GPI=beta2 glycoprotein I; aCL Anticardiolipin antibody; LAC=Lupus AntiCoagulant antibody

After 5 months patient repeated aPLs blood test: AB2GPI IgM and aCL IgM were decreasing but aCL IgM was still over the normal range (Figure 1, Table 3).

Two years later, patient comes again at our attention for swelling of the left lower limb. A venous ultrasound detects Superficial Vein Thrombosis (SVT) of Leonardo's vein (collateral posterior vein of Great Safenian). No travel, no immobilization or any risk's conditions are present in the previous days. Patient's didn't suffer from varicose veins. Then, SVT has been baptized as "idiopathic". Fondaparinux 2.5 mg/die was started and after 30 days of treatment SVT was completely regressed and Fondaparinux stopped. A new thrombophilic screening was sent at the time of SVT, but the results weren't available when Fondaparinux was stopped. Only 15 days after, we discovered that aPLs were in the normal range at the time of SVT (Figure 1, Table 4).

Eighteen months after SVT, patient comes for follow up visit. We have repeated laboratory aPLs screening and venous ultrasound of the lower limbs. No DVT or SVT were detected. aCL and B2GPI were again in the normal range (Figure 1, Table 5).

Table 2. Blood tests performed 12 weeks later

Blood tests performed	Patient values	Normal values
aCL IgM	21	<10 MPL-U/ml
aCL IgG	2	<10 GPL-U/ml
B2GPI IgM	24,6	<7 U/ml
B2GPI IgG	1,8	<7 U/ml
LAC	0,88	<1.2 ratio

aCL=Anticardiolipin; B2GPI=beta 2-glycoprotein I; LAC=Lupus Anti Coagulant; Ig=immunoglobulin

Table 3. Blood tests performed 5 months later

Blood tests performed	Patient values	Normal values
aCL IgM	10,1	<10 MPL-U/ml
aCL IgG	1,41	<10 GPL-U/ml
B2GPI IgM	8,36	<7 U/ml
B2GPI IgG	1,78	<7 U/ml
LAC	0,89	<1.2 ratio

aCL=Anticardiolipin; B2GPI=beta 2-glycoprotein I; LAC=Lupus Anti Coagulant; Ig=immunoglobulin

Table 4. Blood tests performed during Superficial Vein Thrombosis

Blood tests performed	Patient values	Normal values
aCL IgM	1,3	<10 MPL-U/ml
aCL IgG	0,9	<10 GPL-U/ml
B2GPI IgM	0,1	<7 U/ml
B2GPI IgG	0,6	<7 U/ml
LAC	0,95	<1.2 ratio

aCL=Anticardiolipin; B2GPI=beta 2-glycoprotein I; LAC=Lupus Anti Coagulant; Ig=immunoglobulin

Table 5. Blood tests performed 18 months after SVT

Blood tests performed	Patient values	Normal values
aCL IgM	1,9	<10 MPL-U/ml
aCL IgG	1,1	<10 GPL-U/ml
B2GPI IgM	0,1	<7 U/ml
B2GPI IgG	0,1	<7 U/ml
LAC	0,91	<1.2 ratio

aCL=Anticardiolipin; B2GPI=beta 2-glycoprotein I; LAC=Lupus Anti Coagulant; Ig=immunoglobulin

Discussion and review of the litterature

The patient's thrombotic pattern known at the time of SVT was: a positivity of aPLS (although in decreasing, considering the last laboratory test performing 2 years before), heterozygous mutation of Factor V gene, Homozygous mutation of MTHFR C677T gene. The above-mentioned gene's mutations don't identify a reason for long-term anticoagulation, although in SVT or DVT. We wondered if aPLs increase could have a role in the long-term therapeutic choice when we decide to stopped Fondaparinux.

The clinical criteria to diagnose APS (7) include objectively confirmed venous (DVT or Pulmonary Embolism), arterial or pregnancy complications associated with a positive laboratory test for 1 or more aPLs found on 2 or more occasions at least 12 weeks apart. The aPLs recognized in the international criteria include 1) lupus anticoagulant (LAC) detected according to guidelines published by the International Society on Thrombosis and Haemostasis (ISTH), (8), 2) anticardiolipin (aCL) antibody (IgG or IgM) exceeding 40 IgG or IgM phospholipid units, 3) anti-

beta2GPI antibody (IgG or IgM) at titers exceeding the 99th percentile.

In the patient of our case report, aPLs abnormality was confirmed at 12 weeks and at 5 months, although in decreasing.

In APS long life anticoagulation therapy using Warfarin or Acenocoumarol is recommended, while the use of Direct Anticoagulants (DOACs) are, at time, debated (9, 10).

When Fondaparinux was stopped, we had to take a difficult therapeutic choice considering patient's anamnestic positivity for aPLs.

Can isolated SVT change the long-term risk profile in patients with aPLs without VTE? Can SVT be compared to PE or DVT in this group of patients? Zuilly et al. performed a prospective cohort study on 92 patients without anticoagulant treatment (follow up period 35 months) to determine risk factors for thrombotic events in patients with aPLs and/or systemic lupus erythematosus. In multivariate analysis, SVT (HR, 7.45 [95% confidence interval, 2.25 to 24.66]) was an independent risk factor for thrombotic events (11).

The authors highlighting an increased risk of VTE in patients with SVT and thrombotic defect, but don't clarify whether long-life anticoagulation is justified in this patients.

The guidelines of the British Committee for Standards in Haematology recommend that confirmed SVT should be considered for therapeutic anticoagulation, although the optimal duration is uncertain (12).

For the patient of this case report, we decided to stop Fondaparinux when SVT was solved. We don't start long-term anticoagulation or prophylaxis, preferring the clinical surveillance. Our reasons were: first, although SVT shares some risk factors with DVT, it doesn't define APS when associated with aPLs. The anticoagulation-related long-term bleeding risk is not justified in SVT although occur in thrombophilic patients. Second, prospective studies on the long-term risk of thromboembolic recurrence in this subgroup of patients have not been performed. This risk is, at time, unknown. Third, aPLs at time of diagnosis was over the normal range, but in decreasing. We have preferred to check again aPLs in order to verify the auto-antibodies trend. Finally, the homozygous mutation of

MTHFR C677T gene and the heterozygous mutation of Factor V gene, the latter common in the general population with the prevalence of 3-5% (13), doesn't justify long-term anticoagulation in case of DVT or SVT. Appropriate antithrombotic prophylaxis in all high thrombotic risk conditions (such as pregnancy, long-distance travel, immobilization for any causes, surgery) is enough in this subgroup of patients.

Conclusion

We believe that this single case report emphasizes the needed of prospective studies to verify the risk of thromboembolic recurrence in thrombophilic patients with SVT. For the patient of this case report, clinical surveillance seems to have been the best strategy.

Disclosure of Conflict of Interests:

Dr. Carmine Siniscalchi received speaker's fee for congress presentation by MediK.

References

1. Decousus H, Quéré I, Presles E, et al. Superficial venous thrombosis and venous thromboembolism: a large, prospective epidemiologic study. *Ann Intern Med* 2010; 152: 218
2. Decousus H, Epinat M, Guillot K, et al. Superficial vein thrombosis: risk factors, diagnosis, and treatment. *Curr Opin Pulm Med* 2003; 9: 393-397
3. Wichers IM, Di Nisio M, Büller HR, et al. Treatment of superficial vein thrombosis to prevent deep vein thrombosis and pulmonary embolism: a systematic review. *Haematologica* 2005; 90: 672-677
4. Quenet S, Laporte S, Décousus H, et al. Factors predictive of venous thrombotic complications in patients with isolated superficial vein thrombosis. *J Vasc Surg* 2003; 38: 944-949
5. Lim W. Antiphospholipids Syndrome *Haematology Am Soc Hematol Educ Program* 2013; 2013: 675-80
6. Den Heijer M, Koster T, Blom HJ, et al. Hyperhomocysteinemia as a risk factor for deep-vein thrombosis. *N Engl J Med* 1996; 334: 759
7. Miyakis S, Lockshin MD, Atsumi T, et al. International consensus statement on an update of the classification criteria for definite antiphospholipid syndrome (APS). *J Thromb Haemost* 2006; 4: 295-306
8. Pengo V, Tripodi A, Reber G, et al; Subcommittee on Lupus Anticoagulant/Antiphospholipid Antibody of the Scientific and Standardisation Committee of the International Society on Thrombosis and Haemostasis. Update of the guidelines

- for lupus anticoagulant detection. Subcommittee on Lupus Anticoagulant/Antiphospholipid Antibody of the Scientific and Standardisation Committee of the International Society on Thrombosis and Haemostasis. *J Thromb Haemost* 2009; 7: 1737-1740
9. Malec K, Góralczyk T, Undas A. The use of direct oral anticoagulants in 56 patients with antiphospholipid syndrome. *Thromb Res* 2017; 152: 93-97.
10. Dufrost V, Risse J, Zuily S, et al. Direct Oral Anticoagulants Use in Antiphospholipid Syndrome: Are These Drugs an Effective and Safe Alternative to Warfarin? A Systematic Review of the Literature. *Curr Rheumatol Rep* 2016; 18: 74.
11. Zuily S, Regnault V, Guillemin F, et al. Superficial vein thrombosis, thrombin generation and activated protein C resistance as predictors of thromboembolic events in lupus and antiphospholipid patients. A prospective cohort study. *Thromb Res* 2013; 132: e1-7. Doi: 10.1016/j.thromres.2013.04.012. Epub 2013 May 12. PubMed PMID: 23676348
12. Tait C, Baglin T, Watson H, et al; British Committee for Standards in Haematology Committee for Standards in Haematology. Guidelines on the investigation and management of venous thrombosis at unusual sites. *Br J Haematol* 2012; 159: 28-38
13. Ridker PM, Miletich JP, Hennekens CH, et al. Ethnic distribution of factor V Leiden in 4047 men and women. Implications for venous thromboembolism screening. *JAMA* 1997; 277: 1305-7.

Received: 11 December 2018

Accepted: 23 January 2019

Correspondence:

Dr. Carmine Siniscalchi MD, PhD
Angiology and Internal Medicine Unit,
Department of Internal and Emergency Medicine
Parma University Hospital
Via Gramsci, 14 - 43124 Parma, Italy
Tel.+393382984001
E-mail csiniscalchi84@gmail.com