

# Development and usefulness of the new endoscopic classification: DICA

*Ginevra Cambiè<sup>1</sup>, Alessandra Violi<sup>1</sup>, Chiara Miraglia<sup>1</sup>, Alberto Barchi<sup>1</sup>, Antonio Nouvenne<sup>1</sup>, Mario Capasso<sup>1</sup>, Giocchino Leandro<sup>2</sup>, Tiziana Meschi<sup>1</sup>, Gian Luigi de' Angelis<sup>1</sup>, Francesco Di Mario<sup>1</sup>*

<sup>1</sup>Department of Medicine and Surgery, University of Parma, Parma, Italy; <sup>2</sup>National Institute of Gastroenterology "S. De Bellis" Research Hospital, Castellana Grotte, Italy

**Summary.** Colonic Diverticulosis is one of the most common anatomical findings during colonoscopy. This condition has 60% incidence in the population over 60 years old. About 20% of patients will develop Diverticular Disease, and 5% of them will evolve into Diverticulitis. Until the last years there weren't any approaches for the endoscopic classification of this pathology. In 2013, in Florence, the first endoscopic classification was developed: DICA (Diverticular Inflammation and Complication Assessment). The aim of this article is to focus on the process of the development and the validation of the classification by the pool of gastroenterology experts, and, as well, its usefulness during the clinical practice. ([www.actabiomedica.it](http://www.actabiomedica.it))

**Key words:** DICA classification, diverticular disease, endoscopy, colonoscopy, colonic diverticulosis, diverticulitis

## Diverticular Disease

Colonic Diverticulosis is one of the most common clinical-anatomical alterations of the Western world.

Diverticular Disease involves multiple clinical conditions, where at the pathogenesis there is always the same lesion, the colonic diverticula, that goes from the asymptomatic form to the symptomatic not complicated one, including episodes of acute inflammation (1).

This pathology shows a 60% incidence in the population over 60 years old; about 20% of these patients will develop the symptomatic form of it, called Diverticular Disease (DD), and about 5% will develop to complications, such as acute Diverticulitis (2, 3).

It's important to be able to differentiate the different scenarios in which the diverticula could be identified, according to the current definitions (4): Colonic Diverticulosis, also known as simple presence of diverticula in the colon; Diverticular Disease which is the symptomatic form of Diverticulosis and could

range from a mostly functional form to a really debilitating condition; the Uncomplicated Symptomatic Diverticular Disease is classified like a subtype of DD and it is characterized by abdominal pain (mostly in the left lower region) associated with the presence of diverticula, without any signs of inflammation; finally, Diverticulitis is characterized by macroscopic acute inflammation of the diverticulum (5).

The clinical classification of the Diverticula Disease is currently based on the EAES criteria (European Association for Endoscopic Surgery), dividing this condition in:

- Chronic Symptomatic Diverticular Disease;
- Symptomatic Uncomplicated Diverticula Disease (SUDD);
- Symptomatic Complicated Diverticular Disease (6).

EAES classifies as complicated all those conditions that go from the acute episode of Diverticulitis to the diverticular bleeding, stenosis or diverticular perforation (6).

The technique that, nowadays, has the major role in the diagnosis and in the management of DD is the endoscopic procedure. The benefit of the colonoscopy is that has a role in both diagnosis and treatment of some of the complications, such as diverticular bleeding when the localization is known (7).

Colonic Diverticulosis is one of the most common findings during routine colonoscopy, as well as during screening exams (8).

Moreover, the colonoscopy, when performed in early stages, is able to recognize the first signs of Diverticulitis; a recent study shows how premature findings of Diverticulitis with few accompanying symptoms could be individuated in the 2% of patients that made the endoscopic exam without any evident clinical complain (9). The most common endoscopic finding, in this case, would be the presence of hyperaemia and oedema (10).

However, the role of the colonoscopy is controversial and this technique is not indicated in cases where there are evident clinical signs of Diverticulitis because this exam could lead to some complications. The most convenient waiting period, before being able to make an endoscopic exam, is at least 6 weeks after the acute episode (11). On the other hand, there is a study that underlines that, after excluding with the CT-scan the presence of free air in the abdomen, the colonoscopy done before 6 weeks doesn't lead to any complications (12). When the Diverticulitis is not complicated, the episode should be resolved in a few days; but, if after 10 days there isn't an improvement of the conditions, the endoscopic examination should be performed in order to exclude some other possible conditions that could explain the persistence of the symptoms (13). Lahat et al., conducted a study that demonstrated that with an early colonoscopy performed to the patients that still had abdominal symptomatology, in 17% of the cases other comorbidities in addition to Diverticular Disease were found (14).

### **DICA classification**

Until the last years, there wasn't any approach for the classification of Diverticular Disease. Some of the classifications are based just on the manifestations

of acute episodes of Diverticulitis showed by CT scan (like the Hinchey modified classification (15)), some others are just depending on the clinical picture of the pathology (like the Scientific Committee of European Association for Endoscopic Surgery); but, the majority of these classifications are mostly focused on the severity of the acute episode of on Diverticulitis instead of the comprehension of the whole spectrum of DD.

Until 2013 an endoscopic classification is missing, and as well it is known that some of the endoscopic findings are able to predict the evolution of the pathology (15). It is also known that patients with Diverticular Disease could present different clinical and endoscopic pictures of the same condition; for example, a patient with just some rare diverticula in the sigma is different from a patient with sigmoid rigidity and many diverticula but there is no evidence that these differences have any prognostic meaning (16). It's difficult to give a real prognostic value to conditions described like "diffuse diverticula of the colon" or just "inflammation of the diverticulum".

The aim of the DICA classification is to define, through the colonoscopy, a simply, validated and reproducible score of Diverticular Disease (15).

The acronym DICA means Diverticular Inflammation and Complication Assessment. DICA score is the sum of different parameters, like the extension of Colonic Diverticulosis, the number of Diverticula per region, the presence and the type of inflammation, the presence and the type of possible complications (15).

The elaboration of the DICA classification was made in Florence in the 2013, and the process was divided in three parts; in the first phase were identified the most common endoscopic findings, observed during the colonoscopy and to each of them were attributed the scores, during the second part the classification's reproducibility was verified and the set of items was modified in order to improve the simplicity, finally, in the third moment was measured the closeness of agreement (15).

The main steps in the implementation process of the development have been: the choice of the pool of endoscopic doctors and gastroenterologists, coming from different backgrounds such as university hospitals, endoscopic centers and first, second and third level hospitals (15); the choice of the endoscopic videos

that the doctors had to watch and the assignment of the different endoscopic items to take in consideration for the drafting of the classification (15).

In order to choose the entire different endoscopic elements to be included in the classification, the pool of experts watched 300 videos of colonoscopy where Diverticular Disease was presented in all of its forms (15). After the view of the videos, the most frequent findings were reported by the gastroenterologists. The identified items were: the extension of the Colonic Diverticulosis, the number of diverticula for each colonic segment, the type of inflammation and the possible complications (15). These items were the result of a careful review of all the colonoscopies, respecting the importance and the reproducibility of the most relevant characteristics of the pathology.

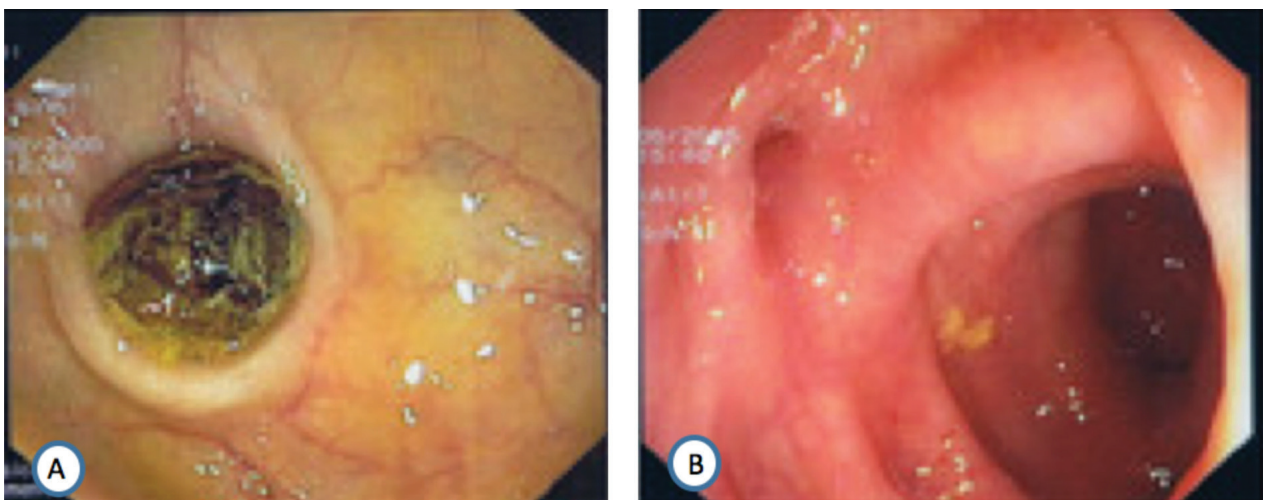
Then, the chosen items were further developed: when referring about the extension of Diverticulosis it was used the four anatomical parts of the colon (ascending, transverse and descending colon and the sigma); for the number of diverticula four different grades were established (I<sup>st</sup> grade less than 5 diverticula, II<sup>nd</sup> grade from 5 to 10, III<sup>rd</sup> grade 10-20, IV<sup>th</sup> grade more than 20 diverticula); for the inflammation they identified the presence of oedema (congestion of the diverticula with loss of the vascular structure of the submucosae), hyperaemia (fig. 1), erosions (fibrinous ulcers with a diameter less than 0.5cm of the peri-diverticular and diverticular mucosae) and pus (purulent

material coming from the diverticulum opening) (fig. 2); for the complications they focused on colonic rigidity, stenosis (fig. 3), Segmental Colitis associated with Diverticula (SCAD) and diverticular bleeding (15).

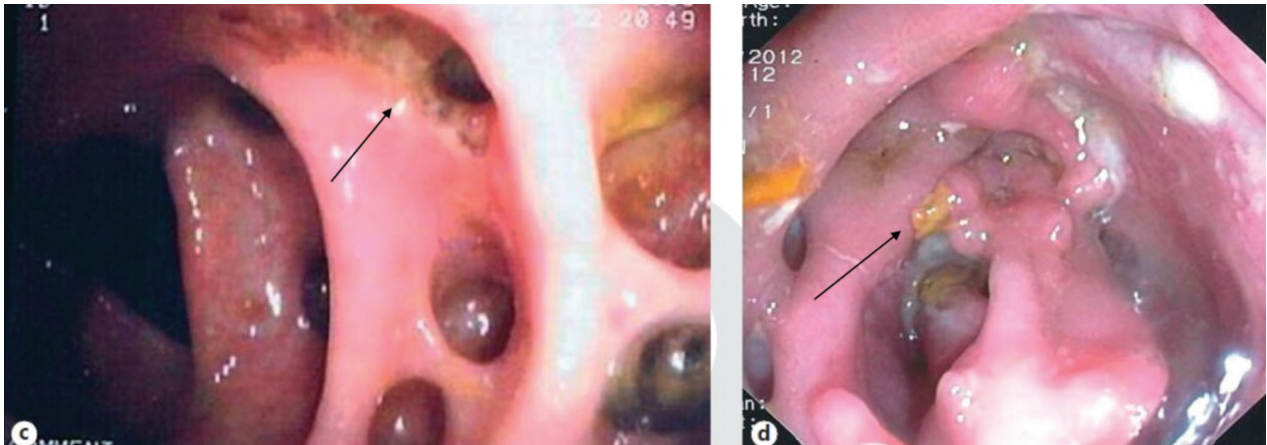
After detecting the items subjects to the classification, the next step was to attribute the score for each one of them, corresponding to their importance (15), meaning that a detection of an increase of severity in the inflammation and endoscopic complication led to higher points (15).

At the end of the process, 4 different scores were individuated: DICA 1, when the sum of the points was less than 4; DICA 2, between 5 and 7; DICA 3, between 8 and 12; DICA 4, more than 13 (15).

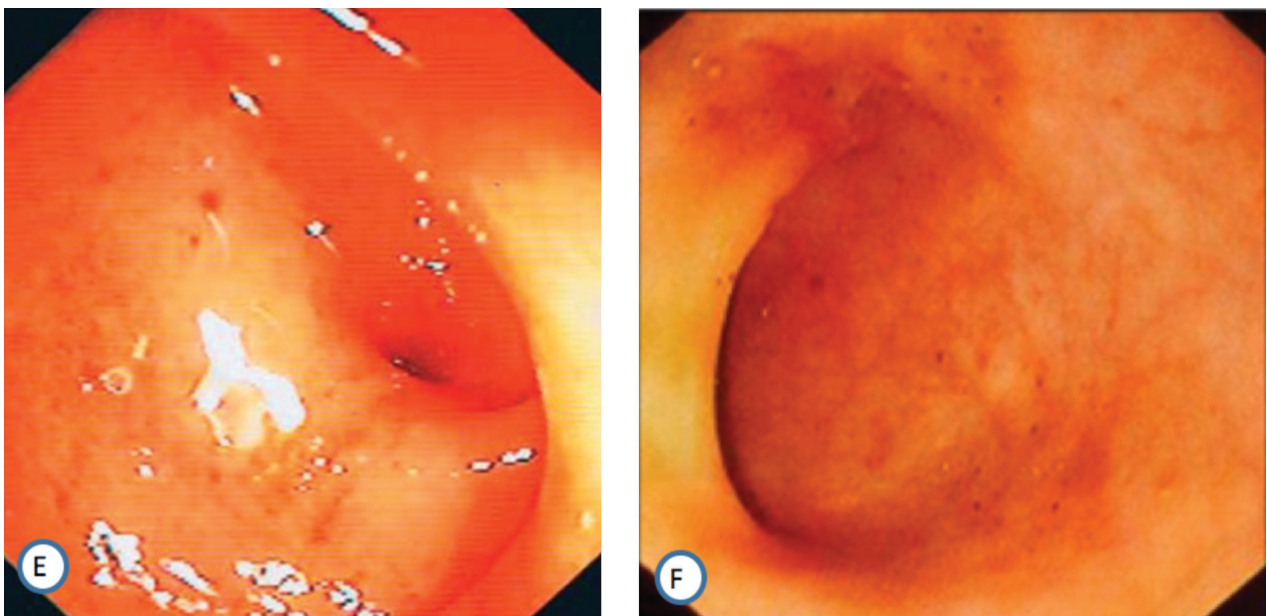
For the development of the classification, 70 patients were diagnosed with Diverticulosis and, from them, 30 videos were selected, based on the quality of the imaging (the endoscopic exploration of the colon had to be completed reaching the ileum and the bowel cleanse had to be adequate). All the videos were watched divided in 5 blocks and, at the end of each of them, a discussion was opened. From those discussions it resulted that the last score, DICA 4, was too complex to be used in the clinical practice, and that to differentiate a low and a medium number of diverticula (5 and 10 correspondingly, during the whole colonoscopy) was too pretentious, along with the discrimination of all the four colonic regions (15). The presence of pus coming from the opening of the diverticulum



**Figure 1.** A: Oedema of the diverticular opening; B: Hyperaemia of the peri-diverticular colonic wall (15)



**Figure 2.** C: Erosions, small fibrinous ulcerations surrounding and involving the diverticular opening (arrow); D: Purulent material coming from diverticular opening (arrow) (15)



**Figure 3.** E: Stenosis of the colonic lumen; F: Rigidity (15)

was, as well, shifted from the inflammation category to the complication one; on the other hand, the presence of SCAD was moved to the inflammation group, because the gastroenterologists thought that it wasn't correct to define it like a complication of Diverticular Disease (15).

The final DICA classification includes:

- The extension of Diverticulosis: dividing the bowel in descendent and ascendant colon;

- The number of diverticula per region: choosing 15 like the cut-off (Grade I<15, Grade II>15);
- The presence of inflammation: including oedema and hyperaemia, erosions and SCAD; and in the case in which more signs of inflammation are found a higher point has to be indicated;
- The presence of endoscopic complications, such as rigidity, stenosis, diverticular bleeding and pus (15) (Table 1).

The DICA's score results:

- o DICA 1, when the sum of the points is less than 3, and it indicates Diverticulosis, the presence of diverticula without any endoscopic signs of inflammation and, mainly, without any probability of clinical complications;
- o DICA 2, when the sum of the points is between 4 and 7; this defines a moderate Diverticular Disease with low chance of clinical complications;
- o DICA 3, when the sum of the points is equal or greater than 8 that it determines a severe Diverticular Disease with a higher risk of complications (15) (table 2).

The closeness of agreement in the assessment of the endoscopic findings was defined by the statistic Kappa coefficient, that valued with a negative score the disagreement and with +1 the total agreement between the experts. Overall, 30 videos were assessed by 32 gastroenterologists, with a total of 960 judgements. After the modification of the classification, obtained in the second phase of the development, the K resulted for DICA 1 0.878, for DICA 2 0.765 and for DICA 3 0.891, detecting a positive closeness of agreement (15).

It's important to underline how this result came from a pool of varied experts (endoscopic doctors coming from University and community hospitals, etc.) indicative of a high grade of reproducibility.

**Table 1.** Numeric value of the items taken in consideration for the development of the DICA classification

	Left Colon (2pnt)	Right Colon (1pnt)
Diverticululosis grade I	0	0
Diverticululosis grade II	1	1
Absence of inflammation	0	0
Oedema- Hyperaemia	1	1
Erosions	2	2
SCAD	3	3
Rigidity	4	4
Stenosis	4	4
Pus	4	4
Diverticula bleeding	4	4

**Table 2.** Numerical DICA classification

DICA SCORE	Numeric values
DICA1	1-3 points
DICA 2	4-7 points
DICA 3	>7 points

Moreover, the link between the classification and the clinical findings was studied; some inflammation index, such as ESR and CRP, and it showed that both of them were correlated, with a statistical significance ( $P < 0.001$ ), to the different DICA scores (15).

DICA classification was, as well, validated choosing a group of 50 patients with a 1 year follow-up. Thirty of the 50 patients were classified with DICA 1 (68%), 20 with DICA 2 (32%). The onset and the recurrence of the complication occurred overall in 29 patients (58%), 10 of them classified with DICA 1 and 32 with DICA 2; in particular, SUDD occurred in 23 patients (9 DICA 1 and 14 DICA 2,  $p = 0.238$ ), Acute Diverticulitis in 6 patients (1 DICA 1 and 5 DICA 2,  $p = 0.083$ ) (15). The numeric classification resulted to simplify the classification of Diverticular Disease, being a user-friendly item in the clinical practice.

For the first time, the endoscopic classification of Diverticular Disease was developed, taking in consideration all the possible items identifiable with the colonoscopy and being able with three scores to have a clear definition of the extension and the severity of this pathology.

## References

1. Pfulzer RH, Kruis W: Management od diverticular disease. *Nat Rev Gastroenterol Hepatol.* 2015;12:629-638.
2. N. a. D. Burkitt, «Diverticular disease of the colon: a deficiency disease of Western civilization»,» *medical journal*, vol. 2, pp. 450-4, 1971.
3. Boles JRRS, Jordan SM. The clinical significance of diverticulosis. *Gastroenterology* 1958; 35: 579-82.
4. Tursi A, Brandimarte G, Giorgetti G, Elisei W, Maiorano M, Aiello F. "The clinical picture of uncomplicated versus complicated diverticulitis of the colon." *Digestive Disease and Science* 2008; 53: 2474- 9.
5. A. Tursi, A. Papa, and S. Danese, "Review article: The pathophysiology and medical management of diverticulosis and diverticular disease of the colon," *Aliment. Pharmacol. Ther.*, vol. 42, no. 6, pp. 664-684, 2015.
6. Köhler, L., Sauerland, S. and Neugebauer, E. (1999) Diagnosis and treatment of diverticular disease: result of a Consensus development conference. The Scientific Committee of the European Association for Endoscopic Surgery. *Surg Endosc* 13: 430-436.
7. A. Tursi, M. Picchio, W. Elisei, F. Di Mario, C. Scarpignato, and G. Brandimarte, "Management of patients with diverticulosis and diverticular disease: consensus statements from the

- 2nd international symposium on diverticular disease," *J. Clin. Gastroenterol.*, vol. 50, no. October, pp. S101-S107, 2016.
8. Strate LL, Modi R, Cohen E, Spiegel BM. Diverticular disease as a chronic illness: evolving epidemiologic and clinical insights. *Am J Gastroenterol* 2012; 107: 1486-93.
  9. Tursi A, Elisei W, Giorgetti GM, Aiello F, Brandimarte G. Inflammatory manifestations at colonoscopy in patients with colonic diverticular disease. *Aliment Pharmacol Ther* 2011; 33: 358-65.
  10. Tursi A. (2015). The role of colonoscopy in managing diverticular disease of the colon. *Journal of Gastrointestinal and Liver Diseases*, 24(1), 85-93.
  11. Lahat A, Yanai H, Menachem Y, Avidan B, Bar-Meir S. The feasibility and risk of early colonoscopy in acute diverticulitis: a prospective controlled study. *Endoscopy* 2007; 39: 521-524.
  12. Lahat A, Yanai H, Menachem Y, Avidan B, Bar-Meir S. The feasibility and risk of early colonoscopy in acute diverticulitis: a prospective controlled study. *Endoscopy* 2007; 39: 521-4.
  13. Tursi, A. (2015). The role of colonoscopy in managing diverticular disease of the colon. *Journal of Gastrointestinal and Liver Diseases*, 24(1), 85-93.
  14. Lahat A, Yanai H, Sakhnini E, Menachem Y, Bar-Meir S. Role of colonoscopy in patients with persistent acute diverticulitis. *World J Gastroenterol* 2008; 14: 2763-2766.
  15. Ambrosetti P, Becker C, Terrier F: Colonic diverticulitis: impact of imaging on surgical management - a prospective study of 542 patients. *Eur Radiol* 2002;12:1145-1149.
  16. Tursi A, Brandimarte G, Di Mario F et al. Development and Validation of an Endoscopic Classification of Diverticular Disease of the Colon: The DICA Classification. *Dig Dis* 2015;33:68-76.
- 
- Correspondence:  
Cambiè Ginevra  
Department of Medicine and Surgery,  
University of Parma, Parma, Italy  
Tel. +393383300809  
E-mail: ginevra.cambie@gmail.com