

C A S E R E P O R T

De Garengeot hernia: laparoscopic treatment in emergency

Alessio Rollo, Christian Franzini, Lorenzo Casali, Caterina Santi, Eugenio Lombardo, Vincenzo Violi

Azienda Unità Sanitaria Locale di Parma, Ospedale di Fidenza, Parma, Italy; E-mail: arollo@ausl.pr.it

Summary. *Introduction:* De Garengeot Hernia is described as the presence of an appendix within a femoral hernia. *Case Report:* We report the case of an elderly woman, who presented with incarcerated femoral hernia without signs of bowel obstruction. CT showed a femoral hernia with appendix in the femoral canal with signs of strangulation. The patient underwent emergency surgery. Diagnostic laparoscopy revealed a non-reducible appendix in the femoral canal, in the absence of signs of peritonitis. An infrainguinal incision was performed. A gangrenous appendix within the sac was revealed, detached from the sac and reintroduced into the abdomen through the femoral canal. The laparoscopic appendectomy was then performed. The hernia repair was performed by suturing the iliopubic tract to Cooper's ligament. Patient had a regular course. *Discussion:* De Garengeot's hernia is a rare occurrence. After the year 2000 a total of 32 articles, which presented 34 cases of de Garengeot's hernia have been published. Due to the rarity of this disease there is no standard procedure; laparoscopy may be a valid technique for determining the condition of the hernia, but due to the difficulty of preoperative diagnosis it is unlikely to be the first choice for the surgical approach. The use of CT can therefore be decisive to help the surgeon in the choice of the approach. *Conclusion:* De Garengeot's hernia can be approached in urgent laparoscopy even in the complicated forms of appendicular inflammation. (www.actabiomedica.it)

Key words: De Garengeot, femoral hernia, appendicitis, laparoscopy

Introduction

Femoral hernia consists in a projection of the sac through the femoral triangle, below the inguinal ligament and presents with incarceration in about 50% of cases. The femoral hernias account for less than 3% of all hernias, have a rate of incarceration ranging between 5 and 20% and their content is typically omentum (1).

De Garengeot Hernia is described as the presence of an appendix within a femoral hernia, usually discovered incidentally during femoral hernia repair. This phenomenon occurs in 0,5-5% of all femoral hernias, while the presence of an appendicitis within a femoral hernia is even more rare, occurring in 0,08% to 0,13% of all cases (2).

This rare condition was first described in 1731 by the French surgeon René Jacques Croissant de Garengeot (3).

But only in 1975 Hervin performed the first appendectomy in an incarcerated femoral hernia (4). To date there have been approximately less than 100 cases reported in the literature (5).

Case Report

MO, a 82-year-old female was admitted in our hospital with an irreducible swelling in the right groin region associated with localized pain and fever about 10 days. There were no abdominal pain, nausea, vomiting.

The medical history of patient reported hypertension and no previous abdominal surgery. The abdominal medical examination revealed only a painful and irreducible lump in the right inguino-crural region with overlying skin erythema. Her abdomen was soft, non-distended with normal bowel sounds on auscultation and no signs of bowel obstruction.

A small increase of inflammatory markers was noted on her blood tests (WBC=13,270 $\times 10^9/L$, CRP =11,98/dl).

The patient's pulse rate was 110/min, blood pressure of 110/70 mmHg, respiratory rate of 15/min, body temperature of 37,2°C, and oxygen saturation of 98.% on room air.

The abdominal X ray did not show signs of bowel obstruction.

The CT scan showed a femoral hernia with appendix in the femoral canal anteromedial to the femoral vessels with signs of strangulation, air bubbles and fluid in the hernia sac (Figs. 1, 2, 3, 4); the patient underwent emergency surgery.

The decision was taken to perform laparoscopic surgery with general anaesthesia. An infraumbilical incision was made, and a pneumoperitoneum was obtained using Hasson's open technique. Two 5-mm abdominal ports were placed suprapubically and in right lumbar quadrant. A 12-mm port in the left iliac fossa. A 10-mm, 30-degree telescope was used to examine the abdominal cavity. Diagnostic laparoscopy revealed a

non-reducible appendix in the femoral canal, in the absence of signs of peritonitis (Fig. 5). An infrainguinal incision was performed. The femoral hernia was found out and was opened. A gangrenous appendix within the sac was revealed, detached from the sac and reintroduced into the abdomen through the femoral canal. The laparoscopic appendectomy was then performed with electrodissection of the mesenteriolum, endoloop placement at the base and extraction of the appendix in

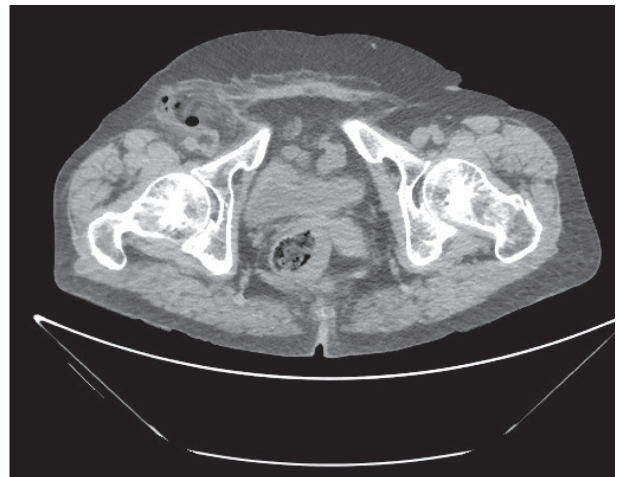


Figure 2.

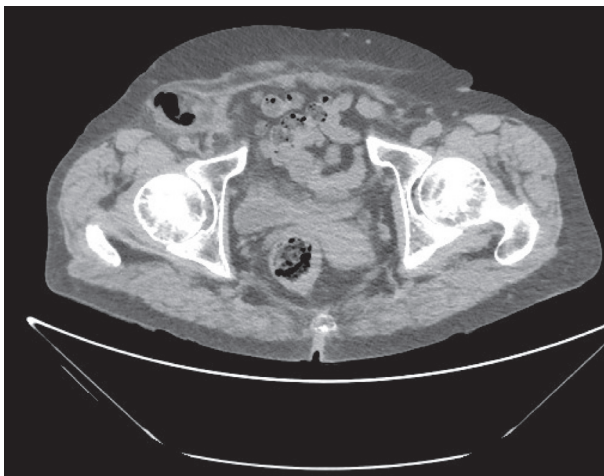


Figure 1.

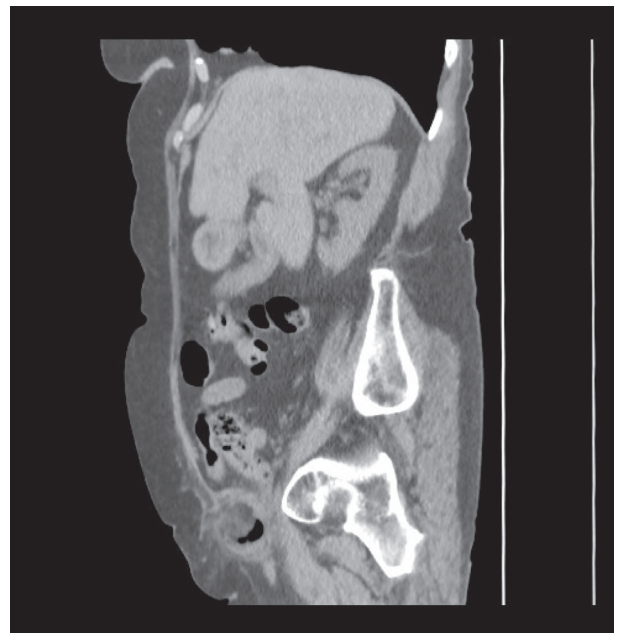

Figure 3.

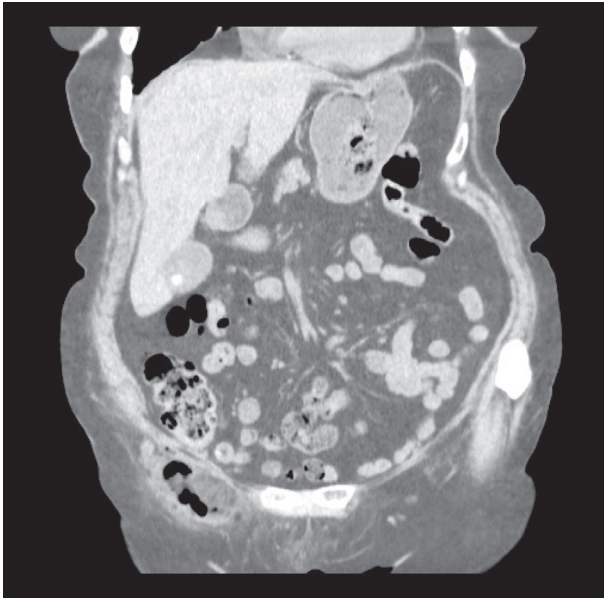


Figure 4.

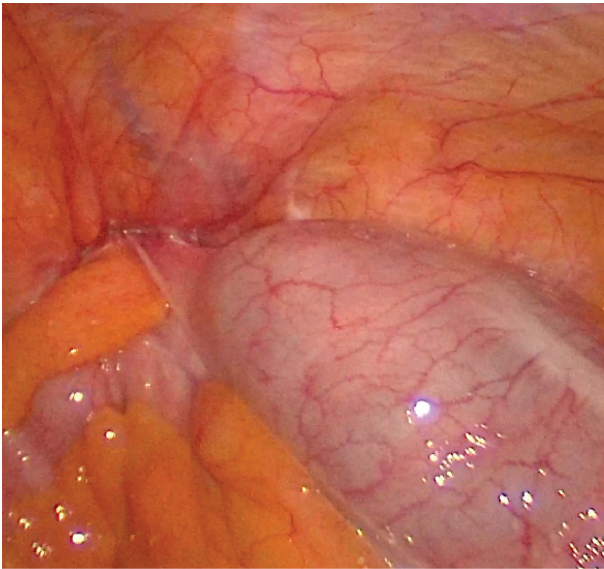


Figure 5.

endobag through the trocar. a drainage tube was placed through the right trocar, then removed on the fifth day.

The hernia repair was performed by suturing the iliopubic tract to Cooper's ligament with non-absorbable suture materials after sac removal, without use of a mesh. The histological examination confirmed a gangrenous appendicitis.

Patient had a regular course and was discharged on the eighth postoperative day.

Discussion

De Garengeot's hernia is a rare occurrence. The inflammatory process of the appendix is usually caused by the extraluminal obstruction of the appendix at the hernial neck, rather than by the more usual cause of intraluminal obstruction (6). The obstruction of the neck leads to a vascular compromise which allows bacterial overgrowth (7). The anatomy of the femoral canal usually prevents intraperitoneal spread of infection and the patient does not present signs of peritonitis (8).

After the year 2000 a total of 32 articles, which presented 34 cases of de Garengeot's hernia and histology proven appendicitis have been published. Several surgical approaches have been described. Most surgical strategies began with an inguinal incision with appendectomy performed through the hernial defect and subsequent repair of the hernia with or without mesh (9-11). Six patients had a laparotomy with a lower midline incision, because of a high possibility of abscess or perforation (9). Only in 2 published cases a laparoscopic approach was performed: in both cases, unlike the case that we present in this report, the appendix was reducible in the abdomen during the laparoscopic surgery and proceeded both to the appendectomy and to the repair of the hernial defect in laparoscopy, in a case with mesh (TAPP) and in a case with direct repair (12, 13).

Due to the rarity of this disease there is not standard procedure (13); laparoscopy may be a valid technique for determining the condition of the hernia, but due to the difficulty of preoperative diagnosis it is unlikely to be the first choice for the surgical approach (14).

The use of CT, not always practiced in published cases, for the early diagnosis in the preoperative phase of this type of hernia, can therefore be decisive to help the surgeon in the choice of the approach (15).

The use of the mesh is controversial: for many authors it should be reserved for cases in which there is no appendix inflammation and risk of infection (16) although some studies prove the feasibility of implantation of mesh even in infected wounds (12, 17).

Conclusion

De Garengot's hernia can be approached in urgent laparoscopy even in the complicated forms of appendicular inflammation, especially when a preliminary CT study leads to correct diagnosis. The execution of the appendectomy by laparoscopy, can be advantageous going to avoid the execution of a median laparotomy in cases where it is not possible to safely perform the appendectomy through the inguinal incision.

Consent: Informed consent was obtained from the patient for publication and available upon request.

Conflict of interest: Each author declares that he or she has no commercial associations (e.g. consultancies, stock ownership, equity interest, patent/licensing arrangement etc.) that might pose a conflict of interest in connection with the submitted article

References

1. Akbari K, Wood C, Hammad A, Middleton S. De Garengot's hernia: our experience of three cases and literature review. *BMJ Case Rep* 2014.
2. Kalles V, Mekras A, Mekras D, Papapanagiotou I, Al-Harethee W, Sotiropoulos G, Liakou P, Kastania A, Piperos T, Mariolis-Sapsakos T. De Garengot's hernia: a comprehensive review. *Hernia* 2013 Apr; 17(2): 177-82. doi: 10.1007/s10029-012-0993-3. Epub 2012 Sep 16.
3. Talini C, Oliveira LO, Araújo AC, Netto FA, Westphalen AP. De Garengot hernia: case report and review. *Int J Surg Case Rep* 2015; 8C: 35-37.
4. Sharma H, Jha PK, Shekhawat NS, Memon B, Memon MA. De Garengot hernia: an analysis of our experience. *Hernia* 2007 Jun; 11(3): 235-8. Epub 2007 Mar 6.
5. Al Abboudi YH, Busharar HA, Alozaibi LS, Shah A, Ahmed R. A french hernia in Dubai: A case report *Int J Surg Case Rep* 2018; 48: 135-138. doi: 10.1016/j.ijscr.2018.05.018. Epub 2018 May 31.
6. Zissin R, Brautbar O, Shapiro-Feinberg M. CT diagnosis of acute appendicitis in a femoral hernia. *Br J Radiol* 2000; 73(873): 1013-1014.
7. Muffak K, Ramia JM, Palomeque A, Segura M, Muñoz N, Garrote D, Ferron JA. Hernia de Aymand. *Cir And* 2004; 15: 155-156.
8. Shah A, Sira Janardhan H. De garengot hernia: a case report and review of literature. *Indian J Surg* 2013 Jun; 75(Suppl 1): 439-41.
9. Misiakos EP, Paspala A, Prodromidou A, Machairas N, Domi V, Koliakos N, Karatzas T, Zavras N, Machairas A. De Garengot's Hernia: Report of a Rare Surgical Emergency and Review of the Literature. *Front Surg* 2018 Feb 16; 5: 12.
10. Konofaos P, Spartalis E, Smirnis A, Kontzoglou K, Kouraklis G. De Garengot's hernia in a 60-year-old woman: a case report. *J Med Case Rep* 2011 Jun 30; 5: 258.
11. Ebisawa K, Yamazaki S, Kimura Y, Kashio M, Kurito K, Yasumuro S, Nishida S, Takayama T. Acute Appendicitis in an Incarcerated Femoral Hernia: A Case of De Garengot Hernia. *Case Rep Gastroenterol.* 2009 Nov 20; 3(3): 313-317.
12. Comman A, Gaetzschmann P, Hanner T, Behrend M. DeGarengot hernia: transabdominal preperitoneal hernia repair and appendectomy. *JLS* 2007 Oct-Dec; 11(4): 496-501.
13. Garcia-Amador C, De la Plaza R, Arteaga V, Lopez-Marcano A, Ramia J. Garengot's hernia: two case reports with CT diagnosis and literature review. *Open Med (Wars)* 2016; 11(1): 354-360. Published 2016 Oct 7. doi:10.1515/med-2016-0065.
14. Beysens M, Haeck L, Vindevoghel K. Laparoscopic appendectomy combined with TEP for de Garengot hernia: case report. *Acta Chir Belg* 2013 Nov-Dec; 113(6): 468-70.
15. Fukukura Y, Chang SD. Acute appendicitis within a femoral hernia: multidetector CT findings. *Abdom Imaging* 2005 Sep-Oct; 30(5): 620-2
16. Jones JW, Jurkovich GJ. Polypropylene mesh closure of infected abdominal wounds. *Am Surg* 1989 Jan; 55(1): 73-6.
17. Saggarr VR, Singh K, Sarangi R. Endoscopic total extraperitoneal management of Amyand's hernia. *Hernia* 2004 May; 8(2): 164-5. Epub 2003 Nov 19.

Received: 3 December 2018

Accepted: 3 January 2019

Correspondence:

Alessio Rollo

Azienda Unità Sanitaria Locale di Parma,

Ospedale di Fidenza, Parma, Italy

E-mail: arollo@ausl.pr.it