

## C A S E R E P O R T

# Symptomatic pseudoarthrosis secondary to a stress fracture of the acromion

*Jacopo Tagliapietra<sup>1</sup>, Ilaria Fantoni<sup>1</sup>, Giuseppe Tagliavoro<sup>1</sup>, Andrea Angelini<sup>1</sup>, Antonio Berizzi<sup>1</sup>, Elisa Belluzzi<sup>1,2</sup>, Assunta Pozzuoli<sup>1,2</sup>, Pietro Ruggieri<sup>1</sup>*

<sup>1</sup>Department of Orthopaedics and Orthopaedic Oncology, University of Padova, Padova, Italy; <sup>2</sup>Musculoskeletal Pathology and Oncology Laboratory, Department of Orthopaedics and Orthopaedic Oncology, University of Padova, Padova, Italy

**Summary.** Fractures of the acromion are uncommon clinical entities, and stress fractures are even more rare, with few cases reported. Due to their rarity, stress fractures are often misdiagnosed. Here, we report a case of an elderly patient with an acromion stress fracture, which was overlooked, resulting in nonunion followed by the displacement of the distal portion of the acromion. The purpose of this report was to discuss this rare fracture, highlighting the importance of an accurate evaluation of radiological imaging as well as clinical data. ([www.actabiomedica.it](http://www.actabiomedica.it))

**Key words:** acromion, elderly patient, pseudoarthrosis, rotator cuff arthropathy, stress fracture

## Introduction

Fractures of the acromion are uncommon (1) and mainly caused by significant trauma usually involving a direct downward force applied to the apex of the shoulder (2). Otherwise, they can result from an indirect force acting on the deltoid, or derive from overuse (3). Stress fractures of the acromion are even more rare with only few cases described in literature (2, 3). Most papers on stress injuries reported minimally displaced fractures diagnosed by radiographs and healed after a conservative treatment (3-7).

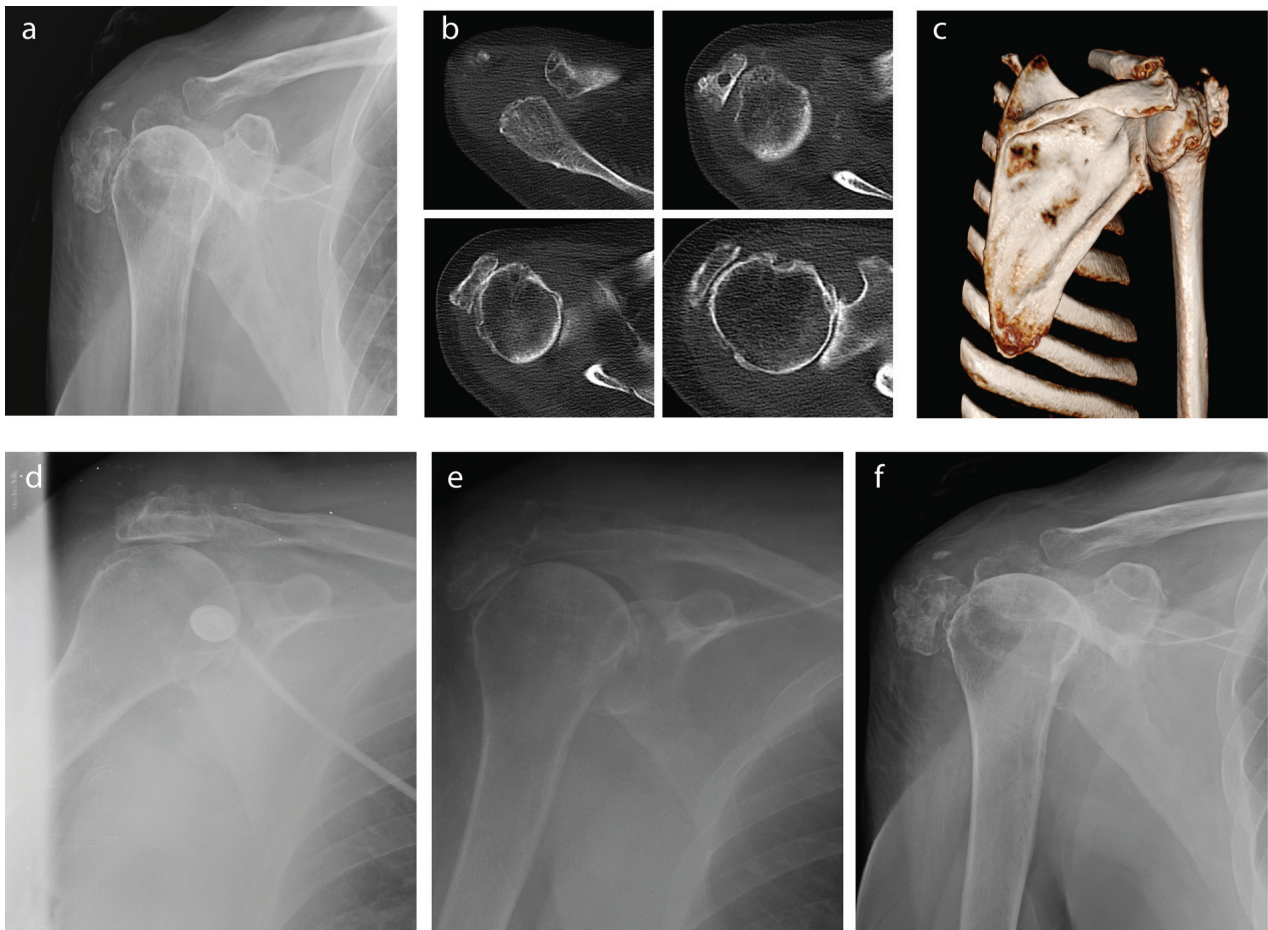
This report describes a case of a stress fracture of the acromion resulting in a nonunion in an elderly patient with a severe rotator cuff arthropathy.

## Case Presentation

A 80 years-old right-handed lady came to our attention on March 2017 due to a 3-months history of severe pain and impairment on the right shoulder. Medical history included hypertensive cardiopathy,

atrial fibrillation, and chronic kidney disease. She denied any previous and recent significant trauma, but reported a long history of pain and functional limitation due to a mild right rotator cuff arthropathy, managed by her family doctor with painkillers and physical therapy.

At the time of our examination, a mild swelling was observed above the acromion. Palpation of the acromial margins evoked acute pain. In addition, a hard and painful mobile body was palpable just few centimeters below the acromion. Passive mobilization of the shoulder was highly painful in all plans of movement, whereas active mobilization was seriously impaired. Standard radiographs revealed a substantial cranialization of the humeral head and a radiopaque body located laterally to the acromion described as a periarticular calcification (Figure 1a). A CT-scan was then performed (Figure 1b-c), showing a clear interruption of the distal portion of the acromion, with a free-flattened fragment located posterior-laterally. Since a displaced acromial fracture was suspected, previous radiological documentation of the patient was analyzed. The oldest available exams showed gleno-humeral and acro-



**Figure 1.** **a)** Radiographs of the shoulder show a periarticular calcified lesion; **b)** CT-scan of the shoulder, show a clear interruption of the distal extremity of the acromion and a free fragment located on the lateral aspect of the humeral head; **c)** 3D reconstruction of the CT-scan shows the posterior unusual aspect of the shoulder; **d-e-f)** progressive detachment of the acromial fragment during follow-up (Feb 2015, Dec 2016, Mar 2018, respectively)

mio-clavicular osteoarthritis, exclusively. On the other hand, chest radiographs performed two years (Figure 1d) and three months (Fig. 1e) before our visit, revealed an undisplaced fracture of the acromion and its subsequent lateral fragment detachment, respectively. Since the patient had not previous trauma, the lesion was recognized as a stress fracture of the acromion. Surgical fixation was proposed, considering fracture displacement and symptoms, but it could not be performed due to the poor patient's general conditions. At one year follow-up, the patient complained no pain at rest and slight pain during movements. She had a severe reduction in shoulder function: active extrarotation, flexion and abduction were particularly impaired,

with a Constant score of 37/100 and a QuickDASH score of 45/55.

On palpation, the distal fragment of the acromion was still appreciable against the lateral aspect of the humeral head. At last follow-up, radiographs of the shoulder showed a partial reabsorption of the fragment (Fig. 1f), probably related to chronic friction.

## Discussion

Several causes for acromial stress fractures have been described in literature: rotator cuff arthropathy (4, 5), history of reverse arthroplasty (8), manual lift-

ing work (3), carrying weight on the shoulder (9), and sport activities (2, 6, 7). As Dennis et al. and Roy et al. suggested, in the set of a rotator cuff arthropathy, the abnormal pressure of the humeral head on the acromion, could lead to acromial fracture (4, 10).

In the present case, despite symptoms were highly suggestive of an exacerbation of rotator cuff arthropathy, physical and radiological examination hinted a more complex lesion. The revision of the previous radiographs and their comparison with the clinical history enabled to reconstruct the pathogenesis of the lesion. Rotator cuff arthropathy led to a progressive cranial migration of the humeral head, causing prolonged subacromial friction and a consequent stress fracture of the acromion, which was facilitated by age-related osteoporosis. This occurred two years before our clinical check. Failure to recognize and treat the fracture, first led to the development of the nonunion and secondarily to the displacement of the distal fragment causing the sudden worsening of pain and loss of function characterized in the last 3 months.

This case represents a clear example of how these lesions can be easily overlooked, as a consequence of their rarity. A stress fracture should be suspected, and further studied, in patients complaining of sudden increase in rotator cuff-related pain. If the patient had been suitable for surgery, a reduction and fixation of the fragment should be considered to avoid the functional impairment of a nonunion. In conclusion, this rare condition should be kept in mind in absence of a proper resolution of symptoms.

**Informed Consent:** Informed consent was obtained from all individual participants included in the study.

**Ethical approval:** All procedures were in accordance with the ethical standards of the institutional and/or national research committee and with the 1964 Helsinki declaration and its later amendments or comparable ethical standards.

**Conflict of interest:** Each author declares that he or she has no commercial associations (e.g. consultancies, stock ownership, equity interest, patent/licensing arrangement etc.) that might pose a conflict of interest in connection with the submitted article

## References

1. Kuhn JE, Blasler RB, Carpenter JE. Fractures of the acromion process: a proposed classification system. *Journal of orthopaedic trauma* 1994; 8(1): 6-13.
2. Hall RJ, Calvert PT. Stress fracture of the acromion: an unusual mechanism and review of the literature. *The Journal of bone and joint surgery British volume* 1995; 77(1): 153-154.
3. Rask MR, Steinberg LH. Fracture of the acromion caused by muscle forces. A case report. *The Journal of bone and joint surgery American volume* 1978; 60(8): 1146-1147.
4. Roy N, Smith MG, Jacobs LG. Stress fracture of base of the acromion. *Annals of the rheumatic diseases* 2002; 61(10): 944-945.
5. Schils JP, Freed HA, Richmond BJ, Piraino DW, Bergfeld JA, Belhobek GH. Stress fracture of the acromion. *AJR American journal of roentgenology* 1990; 155(5): 1140-1141.
6. Taneja AK, Negromonte FP, Skaf A. Stress injury of the acromion: case report and literature review. *European journal of orthopaedic surgery & traumatology : orthopedie traumatologie* 2013; 23 Suppl 2: S189-192.
7. Ward WG, Bergfeld JA, Carson WG, Jr. Stress fracture of the base of the acromial process. *The American journal of sports medicine* 1994; 22(1): 146-147.
8. Wahlquist TC, Hunt AF, Braman JP. Acromial base fractures after reverse total shoulder arthroplasty: report of five cases. *Journal of shoulder and elbow surgery* 2011; 20(7): 1178-1183.
9. Malavolta EA, Assuncao JH, Sunada EE, Gracitelli ME, Ferreira Neto AA. A stress fracture of the base of the acromion: a case report. *BMC musculoskeletal disorders* 2014; 15: 302.
10. Dennis DA, Ferlic DC, Clayton ML. Acromial stress fractures associated with cuff-tear arthropathy. A report of three cases. *The Journal of bone and joint surgery American volume* 1986; 68(6): 937-940.

Received: 26 October 2018

Accepted: 13 February 2019

Correspondence:

Andrea Angelini

Department of Orthopaedics and Orthopaedic Oncology,  
University of Padova, Padova, Italy

Tel: +390498213354

E-mail: andrea.angelini@unipd.it