

C A S E R E P O R T

Treatment of postoperative accessory bile duct injury by fibrin glue and balloon tamponade: a case report

Elena Bonati¹, Alessandro Gnocchi², Elena Cremaschi¹, Lorenzo Viani¹, Paolo Dell'Abate¹

¹OU General Surgery and Organ Transplantation, Department of Surgical Sciences, University Hospital of Parma, Parma, Italy; ²OU Gastroenterology and Digestive Endoscopy, Maternal Child Department, University Hospital of Parma, Parma, Italy

Summary. Laparoscopic cholecystectomy has become the gold standard for the treatment of symptomatic cholelithiasis. Iatrogenic bile duct injuries are still a diagnostic and therapeutic problem and their incidence increased with the introduction of laparoscopic technique. This case report documents a patient with a biliary fistula from an accessory bile duct - Lushka's duct - after routine laparoscopic cholecystectomy, unresponsive to relaparoscopy, ERCP with papillosphincterotomy, biliary stent and nosobiliary tube placement and finally treated with injection of fibrin glue and balloon tamponade through the external drain. Iatrogenic bile duct injuries remain a challenging problem, in particular when they do not communicate with central biliary tree. The detection of this fistulas is more difficult and their management should be multidisciplinary. This case presentation is to emphasize importance of correct diagnostic evaluation and timely and adequate non-surgical methods of treatment of biliary fistulas. (www.actabiomedica.it)

Key words: laparoscopic cholecystectomy, postoperative biliary fistula, Luschka's subvescical duct, balloon tamponade, fibrin glue

Introduction

Gallstone disease is one of the most common disorders of the digestive system in the Western societies. Approximately 10 to 15% of the population has gallstones. Laparoscopic cholecystectomy is considered the gold standard surgical procedure (1) and it is associated with a two-to-four times higher risk of bile duct injury than open cholecystectomy. Bile leak remains a significant cause of morbidity for patients undergoing this procedure and it occurs in 0.2-2% of cases. Injury to the mid-common hepatic duct and to the accessory bile duct - Lushka's duct - are the first and the second causes of bile leaks respectively (5, 6).

The clinical presentation of biliary fistulas may vary. Factors associated with this variability include the volume and the distribution of bile in the peritoneal

cavity, presence of sterile or infected bile and presence or absence of drainage. A minority of patients will be asymptomatic.

We now report a case of post-cholecystectomy bile leakage from a duct of Lushka in a 45-year-old female patient who presented persistent dull abdominal pain 7 days after laparoscopic cholecystectomy.

Case report

A forty-five-year-old female patient was admitted to our Clinic for symptomatic gallstones and laparoscopic cholecystectomy was performed without any drainage placement. On the second post-operative day the patient had abdominal pain on the right side; ultrasound showed a small subhepatic fluid collection

compatible with laparoscopic surgery. Next day the patient was discharged without any problem.

Because of severe abdominal pain, the seventh postoperative day the patient referred to our Clinic.

On admission laboratory tests were performed and showed slightly elevated values of liver transaminase and alkaline phosphatase. Ultrasound identified minor subhepatic fluid collection. On the third day after admission the patient presented increase in body temperature of 38 degrees. Abdominal computer tomography revealed abundant free fluid in all the recesses, and in particular sub-hepatic, so a biliary fistula was suspected. The same day urgent laparoscopic revision was decided and intraabdominal bile collection with biliary peritonitis was found. After careful washing and drainage placement, an endoscopic retrograde cholangiopancreatography (ERCP) showed contrast spreading from the cystic duct. Sphincterotomy (PST) and 10-French endobiliary stent placement were performed.

In the course of the next few days, the patient was treated with antibiotic therapy and was pain free. After three days she developed fever and the amount of drainage output increased. Computer tomography revealed abdominal free fluid and two subhepatic and perigastric collection, respectively 69x31 mm and 61x27 mm. A laparoscopic peritoneal toilette was performed and four drainages were placed.

During the following days, bile flow through the external drainages did not decreased in spite of fasting; an ERCP allowed visualization of contrast spreading upstream of the stent (Figure 1). After its removal a contrast spreading from the cystic duct was noticed too (Figure 2). A nasobiliary tube was placed at the biliary bifurcation.

For the detection of the leak, HIDA scintigraphy was performed but it did not showed extravasation of radionuclide. Furthermore, magnetic resonance cholangiopancreatography (MRCP) described several bile collections, the largest in perigastric region, and the bile leak from the cystic duct, near to an external drainage.

Due to the radiological finding, compatible with a cystic duct leak without any other bile spreading, an ultrasound-guided drainage of the major collection was performed.

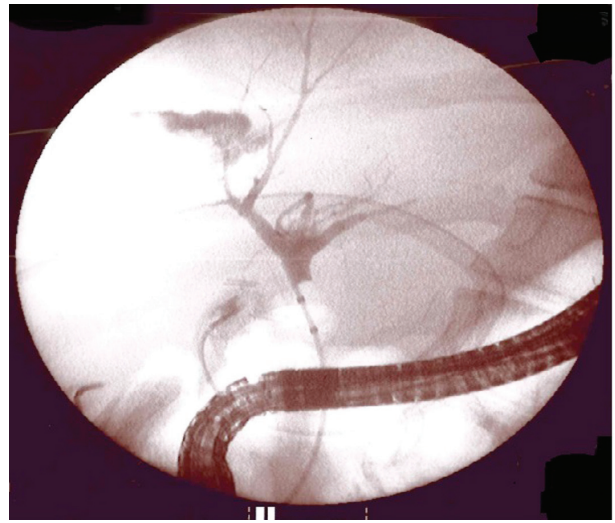


Figure 1. ERCP: contrast spreading upstream of the stent

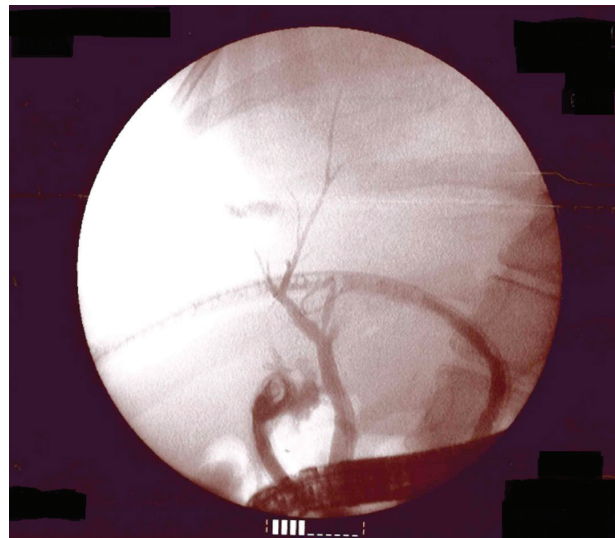


Figure 2. ERCP: contrast spreading from the cystic duct

Contrast injection through the nasobiliary tube showed spreading from the cystic duct so an ERCP was performed, nasobiliary tube was removed and a 30-French metal self-expanding stent was placed.

Even if the patient presented decrease in body temperature, the drainage output remained constant in the course of the next days both fasting and feeding so a check-up with ERCP was performed; no contrast spreading was detected. A nasobiliary tube was re-placed.

Control abdominal ultrasound described reduction of the size of the bile collections. Fifteen day after metal stent placement, this was removed, and the nasobiliary tube too; no contrast spreading was identified, neither from the cystic duct or from secondary ducts, even with injection under pressure.

Five days after the patient was discharge; a sub-hepatic drainage was still in place and the bile flow through this was 100 ml/day.

One month later the patient had still constant drainage output; she was readmitted to our Clinic and ERCP was performed. Intra- and extra-hepatic biliary ducts were regular, without dilatation nor filling defects; there were no contrast spreading after injection under pressure. A Fogarty catheter was placed through the external drainage and a fistulography was performed by contrast injection through it, without any visualization of the biliary tree. Fibrin glue (4 cc) was injected through the Fogarty catheter, the balloon was inflated and it was left in place.

Three days after the manovre, biliary spilling was noticed and it was caused by the reduction of the balloon expansion so it was re-inflated, after fibrin glue application. No biliary loss was further detected. The patient was discharged and one week later both the drainage and the catheter were remove without any further problem.

Discussion

Postoperative biliary fistulas, if improperly treated, can lead to high morbidity and mortality. The ducts of Lushka, or subvescical ducts, are small biliary ducts which originate from the right hepatic lobe, course along the gallbladder fossa, and usually drain in the extrahepatic bile ducts. They occur in 20-50% of the population (8-10). Subvescical duct leaks follow those of the cystic duct as the most common cause of postcholecystectomy bile leaks. The incidence of this particular type of injury has not decreased despite the large collective experience in laparoscopic cholecystectomy as it might be expected; on the contrary, injuries to these ducts have occurred more frequently in laparoscopic era. The preoperative diagnosis (acute cholecystitis vs symptomatic cholelithiasis) nor the surgical

setting (elective vs urgent) seems to predispose to subvescical duct injury (6).

The amount of bile that extravasates after subvescical duct injury is variable. If the injured duct does not communicate with the central biliary tree, the leak is usually self-limiting and small in volume. When it communicates with the extrahepatic bile ducts, the volume of extravasated bile may be larger. The volume of bile can range from 100 ml to more than 2 l (11-13). All factors that increase intra-ductal pressure may pose an additional problem and perpetuate a subvescical duct leak, such as coledocolithiasis or sphincter of Oddi spasm or biliary stent, like in this case (6, 9). Direct visualization of injured subvescical ducts was reported during the era of open cholecystectomy; in most cases the time of presentation of such leaks is within the first postoperative week and in a minority of cases leaks present several weeks after surgery (7).

When a postoperative biliary fistula is suspected an abdominal ultrasound and CT scan are indicated. If a fluid collection is observed, this should be drained under radiologic guidance. If the collection contains bile, an external drainage catheter should be placed.

Fistulography is one of the simplest methods to identify a biliary leak, by retrograde instillation of contrast through a drain. This is performed to demonstrate communication with the biliary tree. Several authors maintain that this should be the initial study performed in suspected cases (6). HIDA scintigraphy is a dynamic study in which an ongoing bile leak may be detected. However, it provides suboptimal anatomic detail. A subvescical duct injury will be shown as extravasation of radionuclide from the gallbladder fossa.

Anatomic details of the biliary tree with functional evaluation of biliary secretion can be obtained with a magnetic resonance cholangiogram (MRC). In addition, it can detect leaks that not communicate with the central biliary tree.

Endoscopic retrograde cholangiopancreatography (ERCP) is the most commonly used modality in which subvescical duct leaks are diagnosed. It can also provide a therapeutic solution with sphincterotomy, endobiliary stent or nasobiliary tube placement, that will lower the biliary tree pressure gradient with preferential bile flow through the papilla. Detection of bile duct leaks with ERCP mandates that these communi-

cate with the central biliary tree.

Reoperation and, specifically, relaparoscopy, can be performed in patients with severe symptoms and in those in which leakage continues despite endoscopic treatment. If an injured subvescical duct is noted, ligation should be performed.

In literature has been reported a case of resolution of a subvescical duct leak with intraoperative application of fibrin glue to the gallbladder fossa during relaparoscopy. Fibrin glue is a biodegradable, absorbable biological agent, which is widely used in surgery to reduce leakage and bleeding from the wound, promote wound healing and prevent adhesion. In the case that we have reported a Fogarty catheter was inserted in the external drain and fibrin glue was instilled through it till the gallbladder fossa. The Fogarty balloon was left in place to keep fibrin glue in contact with the gallbladder fossa and to tamponade the injured subvescical duct.

In literature there are no cases of treatment of bile leaks with extraductal balloon tamponade reported, while occlusion balloon (OB) is used in association with percutaneous transhepatic biliary drainage (PTBD) and it is placed through it in the biliary tree to block the biliary flow (2). The aim of the balloon is to avoid contact between bile and the fistula and to promote the healing process by shortening the healing time in the fistula.

Cozzaglio L. et al. (3) reported six cases of management of duodenal fistula after gastrectomy. The bile ducts were punctured using right intercostal percutaneous approach under fluoroscopic or ultrasonographic guidance. Over the first guide, a balloon specifically designed for vessel occlusion was positioned in the common bile duct between the confluence of the cystic duct and the sphincter of Oddi and it was manually inflated to the size deemed sufficient to stop the bile flow. Later, a drainage catheter was positioned above the balloon in order to obtain complete external drainage of bile. The catheter was left to gravity drainage. When fistula was clinically healing, a cholangiography was performed before PTBD-OB and surgical drainage removal. In case of displacement or obstruction of the drain, or deflation of the OB with the persistence of a biliary leak, patients underwent a new procedure to replace the device or reinflate the OB. They showed

that PTBD-OB can stay in situ for a long time without any medical problems and it can be an effective alternative to surgery.

In literature some cases of balloon tamponade in penetrating liver lesions are also reported. (4) This method was used with good results as a rapid and easy procedure to manage hepatic transfixing lesions in abdominal trauma.

Conclusions

The use of fibrin glue in association with tamponade balloon is a feasible and safe procedure and could represent a new option in the treatment of persistent biliary leaks (1), in particular in subvescical duct fistulas that do not communicate with central biliary tree.

Further studies should be done to explore indications and timing of fibrin glue and tamponade balloon placement. In fact, better results can be expected if they are placed before the clinical situation gets critical, but not too closer the onset of the leak; in this way it is possible to exploit the formation of adhesions which bar the biliary collection in order to prevent the development of intraabdominal sepsis due to biliary peritonitis.

The use of fibrin glue alone seems to be less effective than its use associated with balloon tamponade placement.

Whatever approach, endoscopic, percutaneous or surgical, is performed, the drainage of extravasated bile is mandatory as first treatment (6).

Conflict of interest: None to declare

References

1. Vinay K. Kapoor. Bile duct injury repair: when? Where? Who? *J Hepatobiliary Pancreat Surg* 2007; 14: 476-9.
2. Pedicini V, Poretti D, Mauri G, et al. Management of post-surgical biliary leakage with percutaneous transhepatic biliary drainage (PTBD) and occlusion balloon (OB) in patients without dilatation of biliary tree: preliminary results. *Eur Radiol* 2010 May; 20(5): 1061-8.
3. Cozzaglio L, Cimino M, Mauri G, Ardito A, Pedicini V, Poretti D, Brambilla G, et al. Percutaneous transhepatic biliary

- drainage and occlusion balloon in the management of duodenal stump fistula. *J Gastrointest Surg* 2011 Nov; 15(11): 1977-81.
4. Pellegrino A, Taronna I, Vento G, Mathison L, Del Medico P, Smitter J, Carretta M. Balloon tamponade in penetrating liver lesions. Technical note. *Minerva Chir* 1999 May; 54(5): 363-6.
 5. Lo Nigro C, Geraci G, Sciuto A, Li Volsi F, Sciume C, Modica G. Bile leaks after videolaparoscopic cholecystectomy: duct of Luschka. Endoscopic treatment in a single centre and brief literature review on current management. *Annal Ital Chir* 2012 Jul-Aug; 83(4): 303-12.
 6. Spanos C P, Syrakos T. Bile leaks from the duct of Luschka (subvesical duct): a review. *Langenbecks Arch Surg* 2006; 391: 441-7.
 7. Strasberg SM, Hertl M, Soper NJ. An analysis of the problem of biliary injury during laparoscopic cholecystectomy. *J Am Coll Surg* 1995; 180: 101-25.
 8. Champetier J, Davin JL, Letoublon C, Laborde Y, Yver R, Cousset F. Aberrant biliary ducts (vasa aberrantia): surgical implications. *Anat Clin* 1982; 4: 137-45.
 9. Mergener K, Strobel JC, Suhocki P, et al. The role of ERCP in diagnosis and management of accessory bile duct leaks after cholecystectomy. *Gastrointest Endosc* 1999; 50: 527-31.
 10. Frakes JT, Bradley SJ. Endoscopic stent placement for biliary leak from an accessory duct of Luschka during laparoscopic cholecystectomy. *Gastrointest Endosc* 1993; 39: 90-2.
 11. Albishri SH, Issa S, Kneteman NM, Shapiro AMJ. Bile leak from the duct of Lushka after liver transplantation. *Transplantation* 2001; 72: 338-40.
 12. Thompson RW, Shuler JG. Bile peritonitis from a cholecystohepatic bile ductule: an unusual complication of cholecystectomy. *Surgery* 1986; 99: 511-13.
 13. Wills VL, Jorgensen JO, Hunt DR. Role of relaparoscopy in the management of minor bile leakage after laparoscopic cholecystectomy. *BR J Surg* 2000; 87: 176-80.

Received: 11 October 2018

Accepted: 11 April 2019

Correspondence:

Elena Bonati,

OU General Surgery and Organ Transplantation,

Department of Surgical Sciences,

University Hospital of Parma

Via Gramsci 14 - Parma, Italy

E-mail: ebonati86@gmail.com