

## C A S E R E P O R T

# Hypersensitivity pneumonia and HIV infection in occupational settings: a case report from northern Italy

Matteo Riccò<sup>1</sup>, Alessandro Vignali<sup>2</sup>, Marco Pesci<sup>3</sup>

<sup>1</sup>AUSL - IRCCS di Reggio Emilia, Dipartimento di Sanità Pubblica - Servizio di Prevenzione e Sicurezza negli Ambienti di Lavoro; Reggio Emilia, Italy; <sup>2</sup>Department of Medicine and Surgery, Unit of Geriatrics, Azienda Ospedaliero-Universitaria di Parma, Parma, Italy; <sup>3</sup>Dipartimento di Medicina e Chirurgia, UO di Clinica e Terapia Medica, Azienda Ospedaliero-Universitaria di Parma, Parma, Italy

**Summary.** We describe a case of relapsing hypersensitivity pneumonitis (HP) manifesting as a reconstitution inflammatory syndrome (IRIS) in a HIV infected patient receiving antiretroviral therapy (HAART). The patient, who works as a farmer since the early 20s, was diagnosed with HP at age 23: after an initial steroid therapy, a long lasting clinical regression followed. At age 32, HIV positivity was diagnosed, with HAART starting only at age 38 (initially, lamivudine 300 mg/daily + zidovudine 300 mg b.i.d.). In the following 15 years, CD4+ count remained <500 cells/ $\mu$ L until therapy was shifted to ritonavir 100 mg b.i.d + fosamprenavir 700 mg b.i.d. A six-months long increase in the CD4+ count (>600 cells/ $\mu$ L) with undetectable viral load then followed. Eventually, the patient developed cough and slowly worsening dyspnoea. Laboratory exams (serum T cell lymphocyte count 83%, CD8+ 45-51%; serum IgG for *M faeni*=78 mg/L and *P notatum* >200 mg/L) and high-resolution computer tomography (HRCT) were compatible with relapsing HP. The working tasks were modified avoiding any contact with allergens, then achieving a 6 months long clinical regression. Detectable HIV load (62 copies/mL) was identified at follow-up, and emtricitabine 200 mg/tenofovir disoproxil fumarate 245 mg s.i.d. was added to HAART. Respiratory involvement newly relapsed. HAART was shifted to emtricitabine 200 mg/tenofovir disoproxil fumarate 245 mg s.i.d. and raltegravir 400 mg b.i.d. Within several weeks, signs and symptoms resolved almost completely (peripheral oxygen saturation >95%: CD4+ count remained >600 cells/ $\mu$ L with CD8+ count steadily <50% and CD4+/CD8+ ratio >55%). ([www.actabiomedica.it](http://www.actabiomedica.it))

**Key words:** immune reconstitution inflammatory syndrome, HIV infections, Farmer's lung, alveolitis, extrinsic allergic, occupational medicine

## Introduction

Hypersensitivity pneumonitis (HP), also known as extrinsic allergic alveolitis (EAA), is a complex syndrome resulting from respiratory exposure to various antigens, such as animal, insect, bacterial, protozoal and fungal proteins, and low-molecular-chemical compounds (i.e. isocyanates, zinc, dyes), triggering an exaggerated immune response with subsequent involvement of small airways and lung parenchyma (1-4). Farmer's lung is a well-known occupational disease, being the classical and most studied example of HP/

EAA (4). Even though available data are significantly heterogeneous, it is estimated that 0.5 to 3% of all farmers will eventually develop HP/EAA during their lifetime (5), with an incidence of 0.9 cases/100,000 person-year (6).

The pathogenesis of HP/EAA is poorly understood, resulting from a combination of immune-complex-mediated (type III) and T-cell mediated (type IV) hypersensitivity reactions in susceptible people (7). In particular, T-cell-mediated immune response is suspected to be the cornerstone of the HP/EAA pathogenesis (7).

T-cells are among the specific targets of the Human Immunodeficiency Virus (HIV). As HIV can directly infect and kill cells directed against specific antigens, leaving decreased numbers of cells available to participate in host defence, it eventually impairs the metabolic or secretory functions of effector cells. As a consequence in patients with advanced HIV, HP/EAA should be very infrequent (8-9). In the last decades, many HIV patients have received highly active anti-retroviral therapy (HAART) and experienced long-lasting improvements in their immune status that ultimately allow a better quality of life. Therefore, HIV patients receiving HAART should be more prone to professional exposition to HP/EAA associated antigens, and the restoration of the immune system should in turn raise the possibility that such exposure may elicit associated hypersensitivity reactions (9).

However, only one case of HP/EAA in HIV patients has been reported (9). Moreover, no case at all has been reported from the WHO European region, where estimated prevalence of adult HIV infection ranges between 0.2% (central Europe) and 0.7% (Eastern Europe) (10), and the relatively easy access to up-to-date anti-retroviral therapies should bring at least some serendipitous associations, making patients with HP/EAA+HIV a far from infrequent report for occupational physicians.

### Case history

The patient is a 54 year-old male farmer. He started working 14 year-old at the parent's farm in Northern Italy, a still active medium-size mixed enterprise, with large cereal and vegetable cultures producing the fodder to feed around 400 milk and beef cattle. During his early 20s, the patients performed directly all tasks associated with animal feeding, in particular managing the stores of hay, grain and fodder.

At the age of 23, he suddenly developed a flu-like syndrome, with fever, chills, myalgia and dry cough. The symptoms were elicited by the managing of the stable, worsened during the first hour of the working day and substantially improved at the end of the working shift. Eventually the patient developed progressive weight loss and dyspnoea, with a late stage of se-

vere breathlessness and cyanosis. A chest X-ray demonstrated a patchy airspace disease, with numerous ill-defined small opacities, sparing apices and bases. Laboratory exams showed high level of IgG, detecting specific serum antibodies for *Micropolispora faeni* and *Penicillium notatum*. A diagnosis of HP/EAA was then proposed. After a prolonged therapy with i.v. steroids, he experienced a significant clinical regression. Since this episode, the patients returned to his daily tasks, all stable tasks performed wearing a filtering facemask. Initially, he achieved a substantial control of clinical symptoms without immunosuppressive therapy.

At age 32, he developed a lymphadenopathy of inguinal region lasting more than 5 months: in the same time period, he lost approximately 10 kg in weight. Laboratory exams identified HIV positivity, with a retrospective staging CDC A2. For undisclosed reasons, the patient delayed starting the HAART until age 38, after the diagnosis of Kaposi sarcoma and subsequent restaging of the HIV infection to AIDS CDC stage C2. As the HAART was started (initially, lamivudine 300 mg/daily + zidovudine 300 mg b.i.d.) a steady state was reached, but the CD4+ count remained largely lower than 500 cells/ $\mu$ L. In April 2012 (CD4+ cell count = 366 cells/ $\mu$ L), therapy was shifted to ritonavir 100 mg b.i.d + fosamprenavir 700 mg b.i.d, achieving a slight but significant improvement in CD4+ cell count, steadily higher than 600 cells/ $\mu$ L, with persistent state of non-detectable HIV load.

Starting November 2012, during the annual health survey performed by the occupational physician, the patients complained that work shift associated cough and dyspnoea had recently reappeared, progressively worsening despite any significant modification of working habits or tasks. At physical examination, the patients showed tachypnea, mild tachycardia, and whole lung decreased fremitus, without crackles or any other pathologic respiratory sound. Oxygen saturation was stable to 92% at rest whereas pulmonary functions tests (Table 1) showed a pattern of obstructive disorder, non-reversible, with slight reduction of FVC (4.04 L) and more severe involvement of FEV1 (2.43 L, 62.3% of reference value) with a FEV1/FVC of 60%. Also FEF<sub>25-75</sub> was involved, with a reduction to 1.05 L\*s<sup>-1</sup> (26.1% of the predicted value). Suspecting a relapse of the HP/EAA, further evaluation was per-

**Table 1.** Time trend of pulmonary function tests values

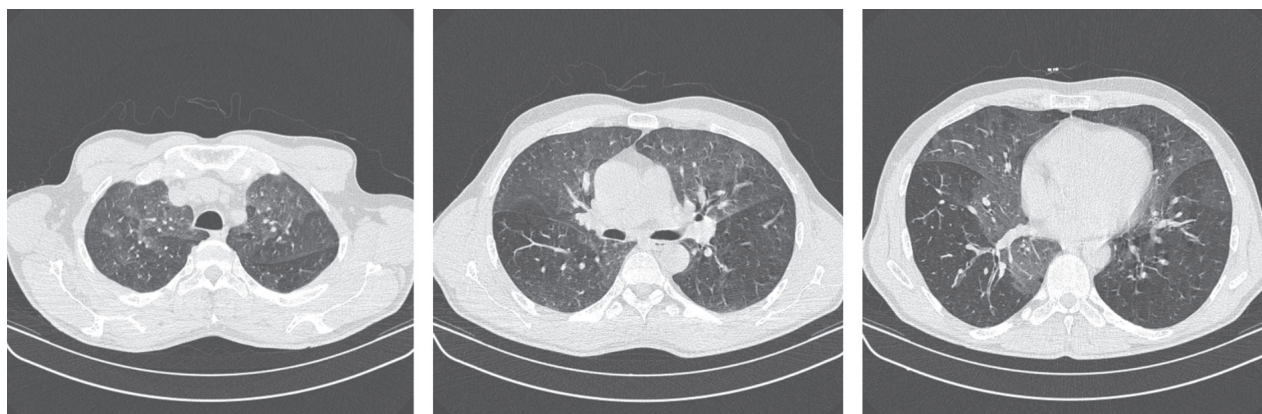		Reference	2011	2012	2013	2014
FVC	L	4.90	3.77	4.04	4.51	3.83
FEV1	L	3.91	2.70	2.43	2.80	2.27
PEF	L*s <sup>-1</sup>	9.21	7.65	7.32	8.00	8.11
FEV1/FVC	%	79.7	71.6	60.0	62.0	59.0
FEF25-75	L*s <sup>-1</sup>	4.03	1.97	1.05	1.29	0.99
DL <sub>CO</sub> (adj)	mL/mmHg*s <sup>-1</sup>	30.8	-	-	23.4	18.2

formed. At the blood count, a persistent leucocytosis was found (WBC >10,000 cells/ $\mu$ L; 63-65% of them neutrophil granulocytes and 25-27% lymphocytes). T cell lymphocytes were at upper normal limit (83%) with a persistent increased representation of CD8+ T cells (45-51%). Specific serum IgG antibodies determinations showed abnormal high values for *M faeni* (78 mg/L, normal values <30 mg/L) and most notably *P notatum* (>200 mg/L; normal limits <30 mg/L). High-resolution computer tomography (HRCT) chest scans showed patchy ground-glass opacities and patchy areas of mosaic perfusion, more profuse at the apices, without evidence of nodular lesions (Figure 1). Eventually, the relapse of HP/EAA was confirmed.

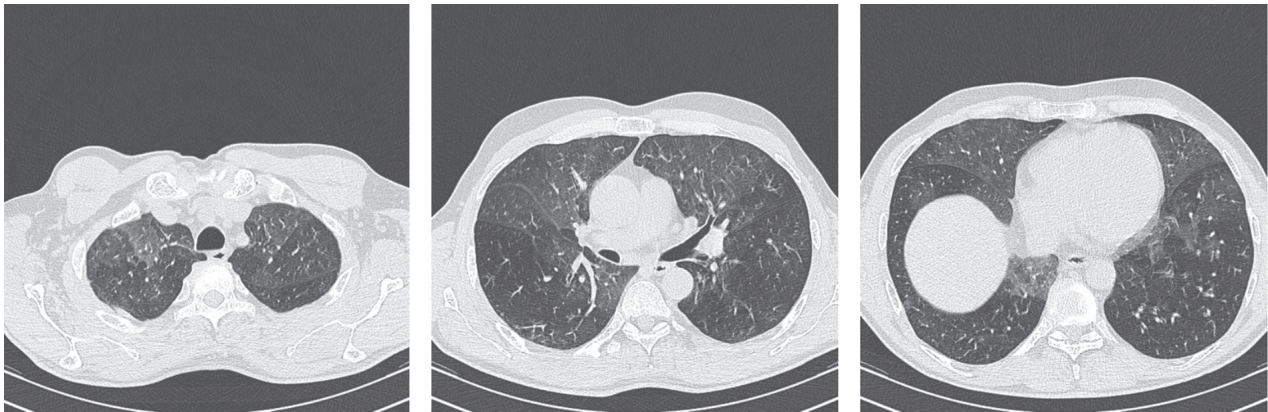
Stating the underlying immunodeficiency status and the previously unsatisfying response to HAART, the patient did not receive any steroid and the doses of the antiviral medications were not changed. Following a consultation with the occupational physician, his tasks were modified in order to avoid any contact with hay or cattle fodder, rather carrying out open-air field activities.

Following this initial intervention, during November 2013 the symptoms apparently regressed: chest physical examination was deprived of any clinical sign; oxygen saturation was stable at 95% at rest and also at pulmonary function tests showed a slight improvement (Table 1). However, DL<sub>CO</sub> stated a moderate reduction of the alveolar transfer rate (23.4 mL/mmHg\*s<sup>-1</sup>). Contextually, CD4 count showed a slight drop, decreasing to 566 cells/ $\mu$ L, associated with the evidence of a detectable HIV load (62 copies/mL in January 2014).

Stating the increased viral count, in February 2014 the antiviral therapy was improved adding a third medication (i.e. emtricitabine 200 mg/tenofovir disoproxil fumarate 245 mg s.i.d.). In the following months, viral load dropped to a non-detectable status and CD4+ count reached 661 cells/ $\mu$ L (March) and eventually 787 cells/ $\mu$ L (April). Unfortunately, HP/EAA symptoms newly relapsed: in May 2014, the patient contacted his occupational physician, who reported diffuse crackles at the upper lung fields, associ-



**Figure 1.** HRCT performed at first HP/EAA relapse, patchy ground-glass opacities and patchy areas of mosaic perfusion, more profuse at the apices, without evidence of nodular lesions. The image, without contrast media, evidenced some reactive lymph node (diameter <15 mm) at the lung ila



**Figure 1.** HRCT performed immediately after the second HP/EAA relapse, showing more diffuse patchy ground-glass opacities and patchy areas of mosaic perfusion, with some nodular lesions and air trapping.

ated with decreased peripheral oxygen perfusion (91% at rest) and severe involvement of pulmonary function tests (Table 1), with worsening obstructive pattern (FEV1 2.27 L, FVC 3.83 L, FEV1/FVC 59%) and a more severe deficit of  $DL_{CO}$  (18.2 ml/mmHg\*s<sup>-1</sup>, 59.1% of the predicted value). New chest scans were performed (Figure 2). The exam showed a more profuse pattern of ground-glass opacities, now associated with diffuse air trapping and some centrilobular nodules.

Because the apparently erratic relapses regularly followed improvements of CD4+ T cell count and the disappearing of the viral load, an association between the HAART and the HP/EAA was then suspected, similar to immune reconstitution inflammatory syndrome (IRIS) (11). The HAART was eventually modified with emtricitabine 200 mg/tenofovir disoproxil fumarate 245 mg s.i.d. and raltegravir 400 mg b.i.d. Within several weeks, symptoms resolved almost completely and peripheral oxygen saturation was stable >95%, despite the CD4+ count remained >600 cells/ $\mu$ L. Interestingly, with the new therapy, CD8+ count remained steadily <50%, with a CD4+/CD8+ ratio always >0.55. However, the patient was unable to restart stable activities, because direct, massive contact with hay and fodder almost immediately elicits symptoms such as a flu-like syndrome: after a consultation with his occupational physician, the work restrictions were then confirmed as a precautionary measure, with a definitive attribution to open-air field activities.

## Discussion

In the case report we presented, both diagnoses of HP/EAA and HIV were previously stated, with a prolonged follow-up (up to 30 years). The clinical features of the two documented and more recent relapses of HP/EAA were consistent with the underlying diagnosis and showed a clear association with working environments housing the causative antigens (i.e. *M faeni* e *P notatum*) and task requiring high level professional exposures. The main clinical topic of this case report actually states on the relation between HIV/AIDS stage and HP/EAA activity, or more specifically on the consequences of HAART on an occupational disease with an immunological aetiology such as HP/EAA.

Acute or subacute HP/EAA in immune-depressed patients is unlikely: not only the total number of immune cells may be extensively affected, but also HIV-infected cells may shift their activity from immunostimulation to immunosuppression, such as a shift from Th1 to Th2 cytokine production. Moreover, HIV infection may interfere with the ability of circulating immune cells to migrate into the lungs and to interact with antigens in the alveolar spaces (8). On the other hand, insurgence of HP/EAA during HAART was previously described (9), and is consistent with an improved status of the immune system.

We think that point should be particularly stressed. The patient had an early diagnosis of HP/

EAA, with prolonged survival despite no significant drug therapy was established after the first hospital admission: prompt identification of inciting agents in HP/EAA may increase the overall survival up to a median 18.2 years (12), but the very long “honey-moon” experienced by our patients is in fact remarkable. We suggest that HIV infection, hypothetically following HP/EAA insurgence of no more than 5 years, had undermined the immune system, actually “freezing” its natural history. When HAART re-established a satisfactory T cell count, not only CD4+ cells were involved: CD8+ lymphocyte count has also been shown to increase when patients respond to HAART and CD8+ are well known effector agents of tissutal events associated with HP/EAA. A still low-level occupational exposure became therefore sufficient to reactivate the natural history of HP/EAA, with subsequent relapses every time CD4+ cell count became enough to trigger CD8+ activity. Even though the T-cell count did not show a very dramatic increase after the application of HAART, particularly in the second episode of HP/EAA reactivation, this presentation is somehow similar to cases of profound, pathological inflammatory reaction frequently identified in patients receiving HAART and previously housing either subclinical or previously recognized microbes, or immune reconstitution inflammatory syndrome (IRIS) (11). IRIS is usually described in the settings of Mycobacterial of cryptococcal infections, but also some autoimmune disease such as Graves diseases were described (11).

In conclusion, availability of effective treatment for HIV infection has changed many aspects of the disease, and also the perspective of the occupational physician: not only patients are surviving longer, but they also retain a prolonged active, working life. If the priority of the occupational physician in the '80s and early '90s was to restrain every possibility of HIV infection in the working settings, now he must be aware that HIV/AIDS patients may interact in new and in some way unpredictable term with their working environment. In the present day context, where atopic professional diseases are acquiring the status of a world-wide priority in occupational health settings, HIV/AIDS patients in HAART should be strictly monitored, because every slight improvement in the immune status may elicit severe clinical consequences,

potentially undermining the fitness to work or, more critically, the labile health status of HIV+ subjects.

**Conflict of interest:** Each author declares that he or she has no commercial associations (e.g. consultancies, stock ownership, equity interest, patent/licensing arrangement etc.) that might pose a conflict of interest in connection with the submitted article

## References

1. Selman M, Pardo A, King ET. Hypersensitivity Pneumonitis: insights in diagnosis and pathobiology. *Am J Respir Crit Care Med* 2012; 186(4): 314-24.
2. Lacasse Y, Girard M, Cormier Y. Recent Advances in Hypersensitivity Pneumonitis. *Chest* 2012; 142(1): 208-217.
3. Girard M, Lacasse Y, Cormier Y. Hypersensitivity pneumonitis. *Allergy* 2009; 64(3): 322-34.
4. Takemura T, Akashi T, Ohtani Y, Inase N, Yoshizawa Y. Pathology of hypersensitivity pneumonitis. *Curr Opin Pulm Med* 2008; 14(5): 440-54.
5. Dalphin JC, Debieuvre D, Pernet D, Maheu MF, Polio JC, Toson B, et al. Prevalence and risk factors for chronic bronchitis and farmer's lung in French dairy farmers. *Br J Ind Med* 1993; 50(10): 941-4.
6. Solaymani-Dodaran M, West J, Smith C, Hubbard R. Extrinsic allergic alveolitis: incidence and mortality in the general population. *QJM* 2007; 100(4): 233-7.
7. Grunes D, Beasley MB. Hypersensitivity pneumonitis: a review and update of histologic findings. *J Clin Path* 2013; 66(10): 888-95.
8. Beck JM. Abnormalities in Host Defense Associated with HIV Infection. *Clin Chest Med* 2013; 34(2): 143-53.
9. Morris AM, Nishimura S, Huang L. Subacute hypersensitivity pneumonitis in an HIV infected patient receiving antiretroviral therapy. *Thorax* 2000; 55(7): 625-7.
10. Jolley E, Rhodes T, Platt L, Hope V, Latypov A, Donoghoe M, et al. HIV among people who inject drugs in Central and Eastern Europe and Central Asia: a systematic review with implications for policy. *BMJ Open* 2012; 2(5): e001465-5.
11. Shelburne SA. Immune reconstitution inflammatory syndrome: more answers, more questions. *J Antimicrob Chemother* 2006; 57(2): 167-70.
12. Fernández Pérez ER, Swigris JJ, Forssén AV, Tourin O, Solomon JJ, Huie TJ, et al. Identifying an Inciting Antigen Is Associated With Improved Survival in Patients With Chronic Hypersensitivity Pneumonitis. *Chest* 2013; 144(5): 1644-1651.

Received: 16 July 2018

Accepted: 7 March 2019

Correspondence:

Dr. Matteo Riccò

AUSL - IRCCS di Reggio Emilia,

Dipartimento di Sanità Pubblica

Servizio di Prevenzione e Sicurezza negli Ambienti di Lavoro

Via Amendola, 2 - 42122 Reggio Emilia, Italy

E-mail: mricco2000@gmail.com