

C A S E R E P O R T

Megarectosigmoid in anorectal malformations: the role of laparoscopic resection

Giorgio Dalmonte, Maria Teresa Mita, Laura Lombardi, Alberto Attilio Scarpa, Carmine Del Rossi, Stefano Cecchini, Federico Marchesi

Dipartimento di Medicina e Chirurgia, Clinica Chirurgica Generale, Università di Parma, Parma, Italy

Summary. Surgical treatment for anorectal malformations may lead to chronic constipation or stool incontinence. The first condition is mostly linked to an abnormal dilation of rectum and sigma and it is primarily managed with medical therapy (laxatives, diet and enemas). When medical therapy fails to improve the symptoms, a surgical resection of the dilated colon is advocated. When performing the procedure it is mandatory to consider all the previous operations the patient undergone. We present a laparoscopic left emicolectomy for an extremely dilated megarectosigmoid after posterior sagittal anorectoplasty in childhood for a recto-urethral fistula. (www.actabiomedica.it)

Key words: anorectal malformation, megarectosigmoid, laparoscopy, emicolectomy, megacolon

Introduction

Severe constipation associated with occasional soiling is among the principal complications following posterior sagittal anorectoplasty (PSARP) for anorectal malformations (ARM) in children (1). A megarectosigmoid (MRS) is often the leading cause for this condition (2). For cases refractory to medical bowel management (BM) (laxatives, diet and enemas) a resection of the dilated bowel is needed (1-3). For this kind of interventions the laparoscopic approach is gaining consensus in young patients like it did in adults in the last decades (4-6).

Case report

A 19 year old boy of North African origins came complaining of severe constipation associated with encopresis. He was born by spontaneous delivery at 37 weeks with a recto-urethral fistula associated with anterior ipospadia. No renal anomalies or vertebral

defects had been shown. A colostomy had been performed the very same day of birth and after 5 months the baby underwent a posterior sagittal anorectoplasty. Four months after that an anoplasty had to be performed for rectal prolapse. At the age of 11 months colon recanalization was done but 20 months later the baby needed a new operation for rectal prolapse which necessitated an anoplasty. At the same time a right orchidopexy for cryptorchidism was done. Sixty days later the hypospadias was repaired performing an urethroplasty following the Thiersch-Duplay's technique. At the age of 7 year old a second PSARP, combined with colostomy, was needed due to rectal mucosal prolapse. Three months later the colostomy was closed by termino-terminal manual anastomosis.

From the age of 16 the boy, who had been following the BM program discontinuously, started complaining about difficult hard stools evacuation and fecal incontinence; a barium enema showed a really dilated distal colon. After bowel disimpaction, the condition was treated with daily BM with Peristeen® transanal irrigation. After 3 years, for lack of symptoms im-

provement, a new barium enema was done (Fig. 1) which demonstrated the persistence of dilation of the rectum and the distal colon, hence we decided to submit the patient to surgical therapy.

The patient underwent a laparoscopic left hemicolectomy with primary reanastomosis and temporary loop colostomy.

In modified lithotomy position we carried out a laparoscopic approach. Revision of the abdomen showed extremely dilated sigmoid colon and rectum and a descending colon with a normal caliber. The inferior mesenteric vein was transected at its termination close to the Treitz ligament. For all the previous surgical operations, to guarantee a satisfactory blood inflow to the rectal stump, we divided the left colic artery and the sigmoid arteries sparing the superior rectal artery.

The splenic flexure was lowered and the left colon was released from its parietal attachment.

The rectal dissection was performed till the medium rectum which was transected with a linear stapler.

Through a mini Pfannenstiel incision the descendent colon was extracted and transected where his caliber was normal. With a circular stapler a Knight and Griffen colo-rectal mechanic anastomosis was performed after reinduction of pneumoperitoneum.

The surgical operation was concluded performing a loop colostomy. The recovery was uneventful and the patient was discharged after 8 days.

The pathological examination of the specimen showed a normal colon without any ganglion abnormality.

One month later a barium enema (Fig. 2) displayed no anastomosis leakage or stenosis. A dilated residual rectum with change of caliber at the anastomosis was still present. The loop colostomy was reversed 3 month after the colectomy.

At one year follow-up no more soiling was reported and evacuations were constant. Only occasionally an enema was needed to clean the bowel.

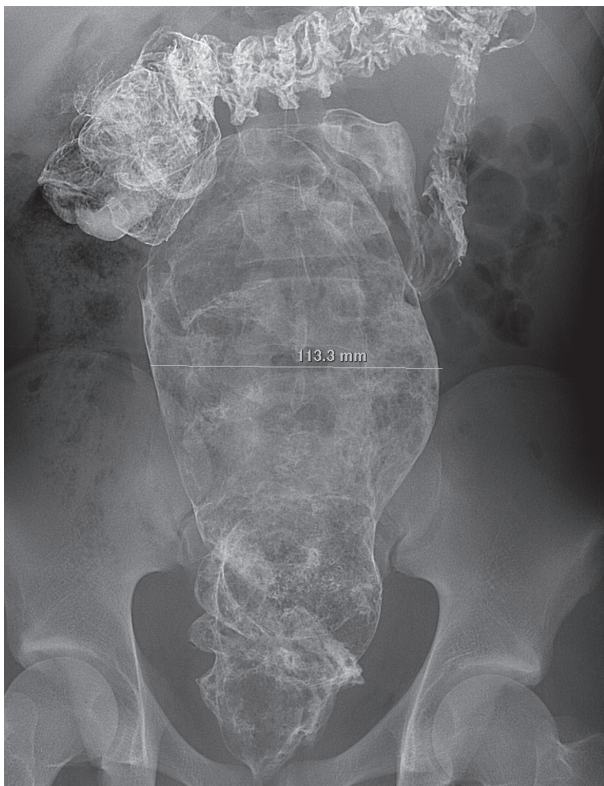


Figure 1. Preoperative barium enema showing a really dilated colon and rectum (maximum caliber 11 cm)

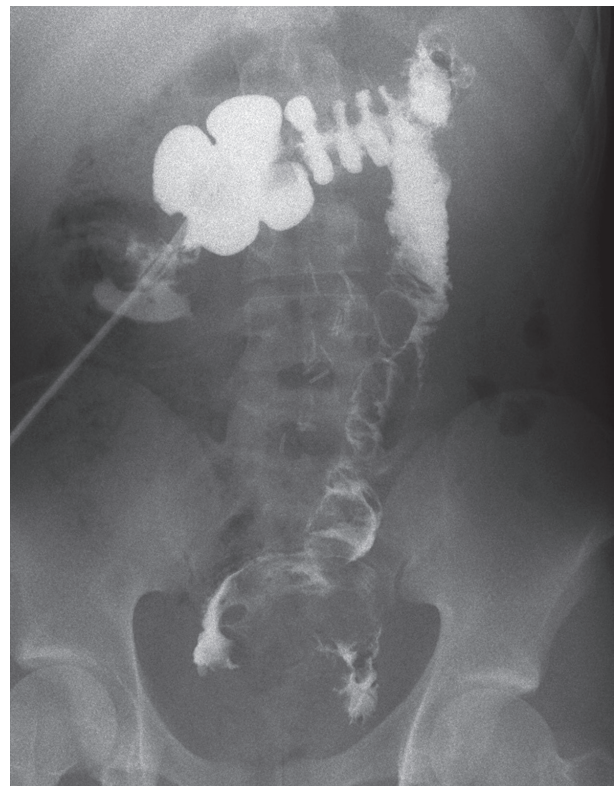


Figure 2. Postoperative barium enema: a change of caliber at the anastomosis is present, but no stenosis or anastomosis leakage are shown

Discussion

The worldwide incidence of ARM is 2-6 per 10,000 liveborn infants, nevertheless a slight variability exists between countries (7). A rectourethral fistula is the most common anorectal malformations in males, who are also lightly more affected by these kind of anomalies. Rectovestibular fistula is the most frequent defect in females (8).

Treatment options for surgical management of anorectal malformations include a colostomy followed by delayed repair of the defect or, in selected cases, a single stage procedure (9). Posterior Sagittal Anorectoplasty, introduced by DeVries and Pena, became the standard of care for dealing with ARM (10, 11). Recently, laparoscopically assisted anorectal pull-through (LAARP) has gained consensus for high-type ARMs (8, 12). No statistical difference in incidence of rectal prolapse is demonstrated between PSARP and LAARP (13).

To evaluate surgical outcome, voluntary bowel movement, soiling and constipation are considered as main parameters. After PSARP the principal complications are represented by chronic constipation, with overflow incontinence, or stool incontinence. The former due to impaired rectal motility, the latter to incompetence of anorectal sphincters (1).

The first step to manage these symptoms is represented by BM which had been shown to be able to significantly improve this weary condition (14, 15).

Moreover Borg et al found an improvement in bowel functional outcome with age, probably related to delayed maturation of enteric neurons (16); nevertheless these children do not achieve the level of healthy children: dilation of rectum and sigma is among the factors which weaken such improvements (2, 11, 17). The average prevalence of MRS is 33% (2). In addition, multiple operations are associated with a worse level of continence (17).

When the constipation is unmanageable with BM a partial rectal resection or even a sigmoidectomy may be needed (1-3), even if recent studies showed a similar functional outcome in children treated either with surgery or BM, thanks to improvement with age of MRS (2). The dilation degree determines the extent of colon resection needed. Furthermore Borg et al

demonstrated no new dilatation after surgery but some grade of BM was still needed (2).

In our case, in performing the left emicolectomy, the blood supply of the rectum was uncertain due to the multiple operations the patient had undergone. We were thus forced to save the superior mesenteric artery and to divide the left colic artery and all the sigmoid branches in order to maintain a reliable arterial flow to the rectum through the superior rectal artery.

Although Lambrecht et al showed the presence of normal superior and inferior rectal arteries in almost all ARM animal models (18) in performing surgery for constipation it is advised to check the arterial supply of the pulled-through colon (2, 3).

As shown in other studies (2) the histological finding of our specimen shows a normal colonic wall.

Although bowel functional outcome, and MRS, seem to improve with age, nevertheless in some cases such a progress may not be satisfactory. Surgical resection of the dilated bowel is therefore unavoidable in these cases to grant resolution of symptoms and a good quality of life. It is our believe that a left emicolectomy, instead of a limited sigmoidectomy, guarantees a better functional long-term result, keeping in mind that a great carefulness must be taken in account performing this operation to avoid accidental damages to inferior mesenteric nerve plexus.

By now the laparoscopic approach has gained consensus in treatment of severe constipation thanks to a reduction of postoperative pain and a shortening of recovery (5), what's more it allows a better cosmetic results which, standing the same functional outcome, may have a great value in a young patient like the one we treated. However, standing the technical difficulties linked to the enormous MRS filling the abdomen and the multiple surgical operations the patient previously underwent, advanced laparoscopic skills are obviously needed to safely perform such an intervention.

Conclusions

Standing the advantages brought by laparoscopy in abdominal surgery, this approach should always be taken into account in choosing the suited therapy for MRS. Considering both previous surgical operations

and the skill level of the surgeon, the intervention and the extent of resection should be tailored on each specific case. Furthermore a great care must be taken regarding the residual blood supply of the rectum.

Conflict of interest: None to declare

References

1. Holschneider A, Hutson J, Peña A, et al. Preliminary report on the International Conference for the Development of Standards for the Treatment of Anorectal Malformations. In: Vol 40; 2005:1521-1526.
2. Borg H, Bachelard M, Sillén U. Megarectosigmoid in children with anorectal malformations: Long term outcome after surgical or conservative treatment. *Journal of Pediatric Surgery* 2014; 49(4): 564-569.
3. Holschneider AM, Jesch NK, Stragholz E, Pfrommer W. Surgical methods for anorectal malformations from Rehbein to Peña - Critical assessment of score systems and proposal for a new classification. *Eur J Pediatr Surg* 2002; 12(2): 73-82.
4. Sheth J, Jaffray B. A comparison of laparoscopic and open restorative proctocolectomy in children. *Journal of Pediatric Surgery* 2014; 49(2): 262-264.
5. Marchesi F, Percalli L, Pinna F, Cecchini S, Ricco M, Roncoroni L. Laparoscopic subtotal colectomy with antiperistaltic cecorectal anastomosis: a new step in the treatment of slow-transit constipation. *Surgical Endoscopy* 2012; 26(6): 1528-1533.
6. Marchesi F, Pinna F, Percalli L, et al. Totally Laparoscopic Right Colectomy: Theoretical and Practical Advantages over the Laparo-assisted Approach. *Journal of Laparoendoscopic & Advanced Surgical Techniques* 2013; 23(5): 418-424.
7. Theron AP, Brisighelli G, Theron AE, Leva E, Numanoglu A. Comparison in the incidence of anorectal malformations between a first- and third-world referral center. *Pediatric Surgery International* 2015; 31(8): 759-764.
8. Iwai N, Fumino S. Surgical treatment of anorectal malformations. *Surgery Today* 2013; 43(9): 955-962.
9. Leva E, Macchini F, Arnoldi R, et al. Single-stage surgical correction of anorectal malformation associated with rectourinary fistula in male neonates. *J Neonatal Surg* 2013; 2(1): 3.
10. DeVries PA, Peña A. Posterior sagittal anorectoplasty. *Journal of Pediatric Surgery* 1982; 17(5): 638-643.
11. Kyrklund K, Pakarinen MP, Koivusalo A, Rintala RJ. Long-term bowel functional outcomes in rectourethral fistula treated with PSARP: controlled results after 4-29 years of follow-up. *Journal of Pediatric Surgery* 2014; 49(11): 1635-1642.
12. Georgeson KE, Inge TH, Albanese CT. Laparoscopically assisted anorectal pull-through for high imperforate anus - a new technique. *Journal of Pediatric Surgery* 2000; 35(6): 927-30-discussion930-1.
13. Han Y, Xia Z, Guo S, Yu X, Li Z. Laparoscopically Assisted Anorectal Pull-Through versus Posterior Sagittal Anorectoplasty for High and Intermediate Anorectal Malformations: A Systematic Review and Meta-Analysis. Sung S-Y, ed. *PLoS ONE* 2017; 12(1): e0170421-20.
14. Midrio P, Mosiello G, Ausili E, et al. Peristeen® transanal irrigation in paediatric patients with anorectal malformations and spinal cord lesions: a multicentre Italian study. *Colorectal Dis* 2016; 18(1): 86-93.
15. Lombardi L, Garrisi E, Ricco M, et al. Study of intestinal function in anorectal malformations: the role of Bowel management in quality of life. *Acta Biomed* 2016; 87(2): 197-204.
16. Miyahara K, Kato Y, Seki T, Arakawa A, Lane GJ, Yamataka A. Neuronal immaturity in normoganglionic colon from cases of Hirschsprung disease, anorectal malformation, and idiopathic constipation. *Journal of Pediatric Surgery* 2009; 44(12): 2364-2368.
17. Hassink EA, Rieu PN, Severijnen RS, vander Staak FH, Festen C. Are adults content or continent after repair for high anal atresia? A long-term follow-up study in patients 18 years of age and older. *Annals of Surgery* 1993; 218(2): 196-200.
18. Lambrecht W, Riebel T, Weinland G. [Vascular supply of the rectum in anal atresia. Angiography studies in newborn swine]. *Z Kinderchir* 1986; 41(6): 340-343.

Received: 10 January 2018

Accepted: 27 February 2018

Correspondence:

Federico Marchesi

Università di Parma, Dipartimento di Medicina e Chirurgia

Sezione di Clinica Chirurgica Generale

Via Gramsci 14 - 43126 Parma

Tel. +39 0521 702156 - +39 0521 940125

E-mail: fedemarchesi72@gmail.com