

# Safety and efficacy of Rotigotine in hospitalized patients with Vascular Parkinsonism aged 75 and older: effects on movement, praxis capacities, time-space orientation, quality of life and adherence to medical therapy

Nicola Marchitto<sup>1</sup>, Francesco Sindona<sup>2</sup>, Alberto Pannozzi<sup>3</sup>, Serenella Gioia Dalmaso<sup>1</sup>, Sabrina Anticoli<sup>4</sup>, Gianfranco Raimondi<sup>5</sup>

<sup>1</sup>Department of Internal Medicine, Alfredo Fiorini Hospital, Terracina, Latina, Italy; <sup>2</sup>Department of Internal Medicine, Sapienza University of Rome, Italy; <sup>3</sup>Nursing student of "Sapienza" University of Rome, Italy; <sup>4</sup>Stroke Unit Department, Azienda Ospedaliera San Camillo/Forlanini, Roma, Italy; <sup>5</sup>Internal Medicine, Dept. of Medico-surgical Sciences and Biotechnologies, "Sapienza" University of Rome, Italy

**Summary.** In hospitals without stroke unit Department, the patients with acute ischemic stroke are stabilized in First Aid and sent to the Department of Internal Medicine. During the hospitalization period the patients undergo medical therapy for the stabilization of hemodynamic parameters and instrumental examinations for the determination of cardiovascular risk and thromboembolic evaluation. All patients are subjected to multi-dimensional evaluation of cognitive, praxis capacities, spatial-temporal orientation, quality of life and adherence to medical therapy. The aim of this study is evaluate the effect of Rotigotine patch on the impairment of neuro-cognitive capacity through a continuous dopaminergic stimulation with transdermal administration. We have observed 19 patients (10 male and 9 female with range age 75-92 yrs) with Acute Ischemic Stroke stabilized in First Aid Department. The outcomes were the neurological changes from the baseline to 7 days in the clinical summary score on MMSE (on a scale from 0 to 30, with higher scores indicating fewer symptoms and lower physical limitations), Morinsky scale (on scale from 0 to 8, indicating adherence to therapy) and swallowing test (acts/minute). During the first week the patients were undergone to treatment with rotigotine 2 mg/24 hours. At the end of the treatment we obtained a statistically significant correlation about improvement of MMSE, Morinsky scale and swallowing test from a basal value. Rotigotine transdermal patches could be a new useful approach in the treatment of elderly hospitalized patients with acute ischaemic stroke correlated with cognitive impairment. Data shown that low dose of rotigotine patch could improves cognitive and praxis functions and therefore the quality of life of the hospitalized elderly patients. Rotigotine was effective and well-tolerated when used in routine clinical practice. Our data gave comfortable results but further evaluation are needed to have conclusive results. ([www.actabiomedica.it](http://www.actabiomedica.it))

**Key words:** Acute Ischaemic Stroke, cognitive evaluation, praxis capacities, adherence to therapy Rotigotine

## Introduction

Acute Ischemic Stroke is the leading cause of neurologic disability in adults; 200,000 deaths annually in the United States. Much can be done to limit

morbidity and mortality through prevention and acute intervention. Stroke patients have sudden neurologic deficit due to vascular mechanism that is ischemic in 85% or primary hemorrhages 15% (subarachnoid or intraparenchymal). An ischemic deficit that resolves

rapidly (24 h) is termed a *transient ischemic attack* (TIA). Stroke disease causes cognitive damage worsening the quality of life of the hospitalized patients: decline of praxis capacities, time-space orientation, swallowing (1, 2) and quality of life. Our observation shows the effect of low dose of Rotigotine patches (a complete dopamine agonist D3>D2>D1) on cognitive impairment (3) in 19 elderly patients with acute ischemic stroke. We used a transdermal dopaminergic therapy for the low compliance to oral therapy and the frequent presence of liver and kidney failure. Some recent data in literature underline that rotigotine could improve the cognitive impairment (4) and swallowing.

## Materials and methods

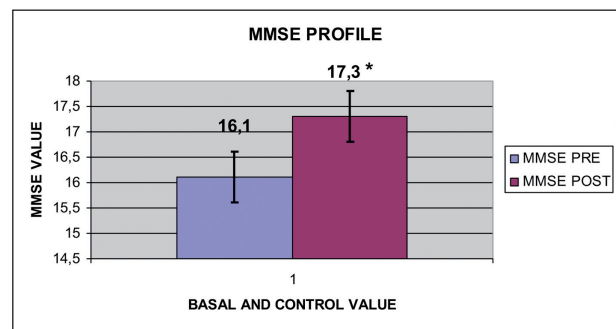
A total of 19 patients are observed from July 1, 2016, through December 17, 2016. All patients fulfil the criteria for the study. No patients underwent randomization erroneously or were enrolled at sites that were closed owing to serious Good Clinical Practice violations. Most patients received recommended pharmacologic therapy for hypertension disease. Eligibility requirements at screening included age of at least 18 yrs. Our observation is characterized by a run-in period (24 hours after the admission to the Internal Medicine Department) during which all patients received rotigotine 2 mg/24h transdermal patch after a basal tests evaluation. After 24 hours no patient showed side effects due to dopaminergic therapy and therefore are underwent to follow up. We have treated 19 patients (10 male and 9 female with range age 70-92 yrs) with recent acute ischemic stroke which determined hemiparesis or hemiplegia associated to a decline of praxis capacities, time-space orientation and swallowing (3), with high cardiovascular risk profile in 90% of cases. It was evaluated the adherence to therapy and the cognitive function using MMSE test, Morinsky Scale and swallowing test (acts/minute) before and post-administration of Rotigotine 2 mg/24h. Patients were subjected to multi-parametric evaluation. Data were collected, managed, and analyzed for statistical analysis using Sigmastat Analysis Program (version 3.5). Statistical analysis was performed with Wilcoxon signed rank test to compare data in small group. Sigmastat

Analysis Program (version 3.5) is also used for graphic representation.

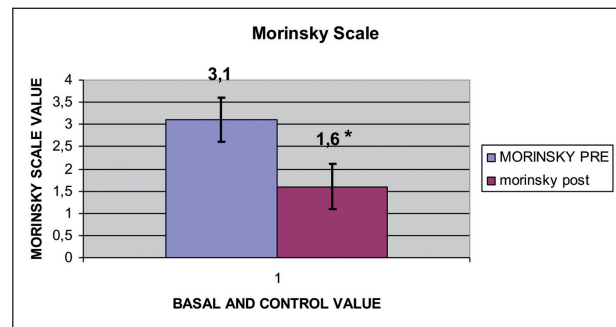
All the patients provided written informed consent.

## Results

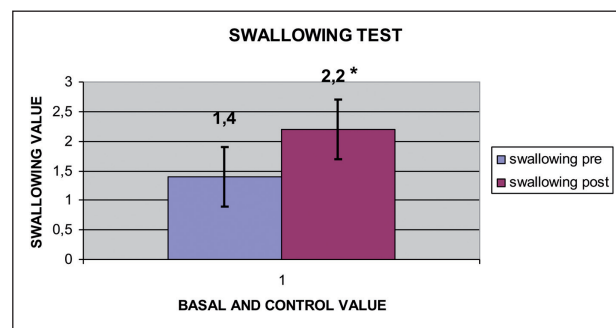
We obtained a statistical evaluation on all enrolled patients with cognitive impairment due to acute ischemic stroke after 7 days of treatment with Rotigo-



**Figure 1.** Mini Mental State Examination Profile (pre and post treatment)



**Figure 2.** Morinsky Scale Profile (pre and post treatment)



**Figure 3.** Swallowing Test Profile (pre and post treatment)

tine 2 mg/24h transdermal patch. At the end of the treatment, the data have showed a statistically significant correlation about improvement of MMSE test (6-8) swallowing test and Morinsky scale from a basal value. Further evaluation are needed to have conclusive results.

## Conclusion

Rotigotine could be a new useful approach in the treatment of elderly hospitalized patients with recent stroke correlated with cognitive impairment, especially about praxis capacities, time-space orientation and swallowing. This observation led us to use rotigotine transdermal patches 2 mg/24 h in patients with cognitive degeneration related to acute ischemic stroke (5) treated in Internal Medicine Department. Rotigotine was effective and well-tolerated when used in routine clinical practice. Our data give comfortable results but further evaluation are needed to have conclusive results.

**Conflict of interest:** Each author declares that he or she has no commercial associations (e.g. consultancies, stock ownership, equity interest, patent/licensing arrangement etc.) that might pose a conflict of interest in connection with the submitted article

## References

- Hirano M, Isono C, Sakamoto H, Ueno S, Kusunoki S, Nakamura Y. Rotigotine Transdermal Patch Improves Swallowing in Dysphagic Patients with Parkinson's Disease. *Dysphagia* 2015 Aug; 30(4): 452-6.
- Schirinzi T, Imbriani P, D'Elia A, Di Lazzaro G, Mercuri NB, Pisani A. Rotigotine may control drooling in patients with Parkinson's Disease: Preliminary findings. *Clin Neurol Neurosurg* 2017 May; 156: 63-65.
- Gorgoraptis N, Mah YH, Machner B, Singh-Curry V, Malhotra P, Hadji-Michael M, Cohen D, Simister R, Nair A, Kulinskaya E, Ward N, Greenwood R, Husain M. The effects of the dopamine agonist rotigotine on hemispatial neglect following stroke. *Brain* 2012 Aug; 135 (Pt 8): 2478-91.
- Martorana A, Di Lorenzo F, Esposito Z, Lo Giudice T, Bernardi G, Caltagirone C, Koch G. Dopamine D2-agonist rotigotine effects on cortical excitability and central cholinergic transmission in Alzheimer's disease patients. *Neuropharmacology* 2013 Jan; 64: 108-13.
- Koch G, Di Lorenzo F, Bonni S, Giacobbe V, Bozzali M, Caltagirone C, Martorana A. Dopaminergic modulation of cortical plasticity in Alzheimer's disease patients. *Neuropsychopharmacology*. 2014 Oct; 39(11): 2654-61. doi: 10.1038/npp.2014.119. Epub 2014 May 26.
- Semprini R, Lubrano A, Misaggi G, Martorana A. Apathy as marker of frail status. *J Aging Res* 2012; 2012: 436251.
- Blundo C, Gerace C. Dopamine agonists can improve pure apathy associated with lesions of the prefrontal-basal ganglia functional system. *Neurol Sci* 2015 Jul; 36(7): 1197-201.
- Brusa L, Pavino V, Massimetti MC, Bove R, Iani C, Stanzi-one P. The effect of dopamine agonists on cognitive functions in non-demented early-mild Parkinson's disease patients. *Funct Neurol* 2013 Jan-Mar; 28(1): 13-7.

Received: 27 November 2017

Accepted: 2 May 2018

Correspondence:

Dr Nicola Marchitto

Specialist in Geriatrics and Gerontology, Medical Assistant, Department of Internal Medicine, Alfredo Fiorini Hospital, Terracina (Latina), Italy

Tel. +393277064979

Fax +390773708752

E-mail: n.marchitto@ausl.latina.it