

# Partial repair in irreparable rotator cuff tear: our experience in long-term follow-up

Enrico Daniele Di Benedetto, Paolo Di Benedetto, Andrea Fiocchi, Alessandro Beltrame, Araldo Causero

Clinic of Orthopaedics, Academic Hospital of Udine, Italy

**Summary.** *Aim of the work:* Massive rotator cuff tears are a common source of shoulder pain and dysfunction, especially in middle age patient; these lesions represent about 20% of all rotator cuff tears and 80% of recurrent tears. Some lesions are not repairable or should not be repaired: in this case, a rotator cuff partial repair should be recommended. The aim of the study is to evaluate the outcome of rotator cuff partial repair in irreparable rotator cuff massive tear at medium and long-term follow-up. *Materials and method:* We have evaluated 74 consecutive patients treated with functional repair of rotator cuff by the same surgeon between 2006 and 2014. We divided patients into 2 groups, obtaining 2 average follow-up: at about 6,5 (group A) and 3 years (group B). In December 2015, we evaluated in every patient ROM and Constant Score. We analyzed difference between pre-operative data and the 2 groups. *Results:* We found statistical significant difference in ROM and in Constant Score between pre-operative data and group A and group B. Between group A and group B there is relevant difference in Constant Score but not in ROM. *Conclusions:* Partial repair can give good results in a medium follow-up, in terms of pain relief and improvement of ROM, as well as in quality of life. Difference in ROM and Constant Score between group A and group B may indicate the begin of partial repair failure; according to our data, 6-7 years may be the time limit for this surgery technique. ([www.actabiomedica.it](http://www.actabiomedica.it))

**Key words:** massive rotator cuff tear, irreparable rotator cuff tear, shoulder arthroscopy, partial repair

## Introduction

Massive rotator cuff tears are a common source of shoulder pain and dysfunction, especially in middle aged patient; they represent about 20% of all rotator cuff tears and 80% of recurrent tears. They occur most commonly in male patients, in the dominant arm and in patients engaged in heavy work (1, 2).

Classically, massive rotator cuff tear has been described as a lesion of 5 centimetres or more by Cofield or as complete tear of 2 tendon or more by Gerber (1, 3, 4).

According to Collins et al, massive rotator cuff tears can be classified into five components (supraspinatus, superior subscapularis, inferior subscapularis, infraspinatus, and teres minor) and five patterns (type

A, supraspinatus and superior subscapularis tears; type B, supraspinatus and entire subscapularis tears; type C, supraspinatus, superior subscapularis, and infraspinatus tears; type D, supraspinatus and infraspinatus tears; and type E, supraspinatus, infraspinatus, and teres minor tears) (1).

Castricini et al. proposed a novel complete classification system for irreparable rotator cuff tear: the tendons are numbered sequentially (1, supraspinatus; 2, infraspinatus; 3, teres minor; and 4, subscapularis); an intact tendon is graded as 0, a repairable tear with good healing potential is grade with plus sign and a repairable tear with low healing potential is graded with a minus sign; irreparable tear are graded with the number of tendon (5).

The definition of an irreparable rotator cuff tear is not clear (5).

A lot of radiological criteria have been proposed to define this type of lesion:

- Chronic acromiohumeral distance less than 6-7 mm (6-8).
- Muscle atrophy greater than grade 2 or Thomazeau stage III (9, 10).
- tendon retraction of Patte stage III or more (11).
- muscle fatty degeneration assessed on CT and MRI, Goutallier stage III-IV (12).

Some surgeons do not consider rotator cuff tear as irreparable, arguing that all rotator cuff tear are reparable (1). According to Collins et al. and Denaro et al., we agree that some lesions are not reparable or should not be repaired (1, 13). In reparable massive tears risk of re-rupture depends on age, tear size, repair technique used, inappropriate rehabilitation; most important factors are muscle atrophy and fatty degeneration (5, 14).

Several options are available in irreparable rotator cuff tear, as well as conservative treatment: arthroscopic debridement, complete or partial rotator cuff repair primarily, LHB tenotomy; in second place, tendon transfer, arthroplasty, augmentation procedures (5, 15).

In this study we consider partial repair of irreparable rotator cuff tear, in accordance with technique described by Burkhart (16).

The aim of the study is to evaluate outcome of rotator cuff partial repair in rotator cuff massive lesion at medium and long-term follow-up.

## Materials and method

This is a case-series retrospective study. We have evaluated 74 consecutive patients treated with functional repair of rotator cuff by the same surgeon between 2006 and 2014.

Inclusion criteria was: massive rotator cuff tear treated with arthroscopic partial repair.

Exclusion criteria were: rotator cuff traumatic lesion, reparable massive lesion, shoulder instability, previous shoulder surgery, shoulder surgery following partial repair.

We divided all patients in two groups in relation to the date of surgery: first group (A) until the end of 2010 and the second (B) until the end of 2014. We obtained group A with 31 patients and group B with 41 patients, with average follow-up of about 6,5 years for group A and about 3 years for group B.

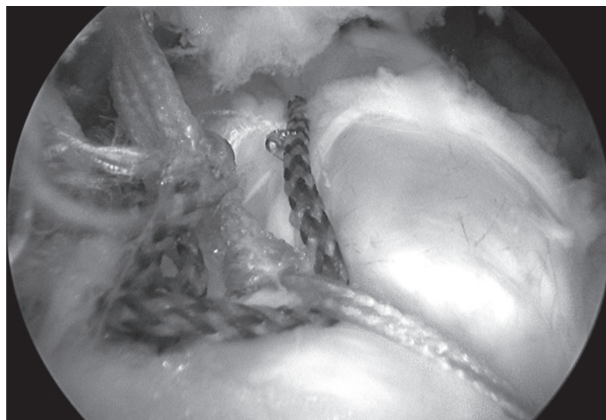All patients have been evaluated before surgery and in December 2015. Subjects were assessed with evaluation of passive and active ROM and with Constant Score.

### *Surgical technique*

All surgery procedures were conducted by a single surgeon. We used lateral decubitus technique with 5 kg of traction. We used three arthroscopic portals: posterior first, then anterior and lateral. The long head of biceps, when present, was evaluated and we did his tenotomy if necessary. After an articular evaluation of the rotator cuff tear and possible cartilage or labrum lesion, we evaluated subacromial space removing subacromial bursa; in this space, we check rotator cuff tears size, tendon quality and fatty degeneration; with an arthroscopic clamp, we checked if tendons could reach the footprint region. Then we proceeded with the repair: we repair subscapularis if damaged and the posterior part of rotator cuff (infraspinatus or posterior part of supraspinatus) in most of case with one or two anchors (Figure 1 and 2).



**Figure 1.** Example of massive rotator cuff tear



**Figure 2.** Example of partial repair

### *Rehabilitation*

According with surgeon indications, all patients used a brace at 30° or 45° of abduction for 4 weeks. If subscapularis were repaired, we used neutral rotation brace. In this period, only passive ROM was permitted. After the removing of the brace, active-assisted pain-free movements without resistance were permitted for about 1 months. Then, after two months from surgery the patient could start with active movements and after three months exercises with resistance and with weight lifting were permitted.

### *Statistical analysis*

We evaluated With Wilcoxon and Mann-Whitney tests if there is statistical difference of ROM and Constant Score between:

- Before surgery data and group A (follow-up at 6,5 years)
- Before surgery data and group B (follow-up at 3 years)
- Group A and group B (follow-up at 6,5 and 3 years)

### **Results**

Between 2006 and 2014 74 consecutive patients have undergone shoulder arthroscopic surgery for massive rotator cuff tear with functional repair. During

follow-up, two patients have been excluded from the study: one (group A) for ischemic stroke and one (group B) for re-surgery (latissimus dorsi tendon transfer).

The two samples population were homogeneous: age in group A was 67,01 years and in group B 67,45 years. 48,38% of group A and 51,21% of group B were men. In 80,64% of group A and in 85,36% of group B the dominant limb was interested. Tendon repair of two samples was similar: in group A was used 1,59 anchor and in group B 1,34 anchor.

At the time of surgery mean age was 67.21±5.84 years for group A and 67.93±8.29 for group B.

Average follow-up was 6.62±1.33 years for group A and 2.8±1.01 years for group B.

In 7 patients (9.7%), 3 in group A and 4 in group B, we found a large tear only in supraspinatus tendon and we did a partial repair.

In 49 patients (68.05%), 20 in group A and 29 in group B, supraspinatus and infraspinatus had a large tear and we did a complete repair of infraspinatus and a partial repair in supraspinatus.

In 3 patients (4.2%), 1 in group A and 2 in group B, supraspinatus and subscapularis had a large tear and we did a complete repair of subscapularis and partial repair of supraspinatus.

In 13 patients (18.05%), 7 in group A and 6 in group B, all 3 tendon had a large tear. In 1 patient we repaired only subscapularis, in the others we did a complete repair of infraspinatus and subscapularis.

Group A results of ROM and Constant Score are shown in table 1 and group B results are shown in table 2.

*Statistical analysis.* We used Wilcoxon test (paired samples) to evaluate statistical significance difference of ROM and Constant Score between data before surgery and follow-up of group A and group B. We used Mann-Whitney test (impaired samples) to evaluate statistical significance between group A and group B.

Statistical significance was for all test  $p < 0.05$ .

In group A between data before surgery and follow-up at 6,5 years we found statistical significant difference in all category of ROM (Graphic 1).

In group B between data before surgery and follow-up at 3 years we found statistical significant difference in all category of ROM, except for passive elevation (Graphic 2).

**Table 1.** Results of ROM and Constant Score in Group A

	Pre-operative	Follow-up at 6.5 years
Average passive elevation	145°±27.88° (90°-180°)	155.70°±30.71° (70°-180°)
Average active elevation	96.33°±32.21° (30°-160°)	140.00°±36.48° (50°-180°)
Average passive abduction	132.00°±23.10° (90°-180°)	148.33°±33.02° (60°-180°)
Average active abduction	78.67°±27.88° (30°-150°)	126.33°±35.08° (30°-160°)
Average Constant Score	46.52 ±11.54 (34-69)	70.82±14.66 (40-90)

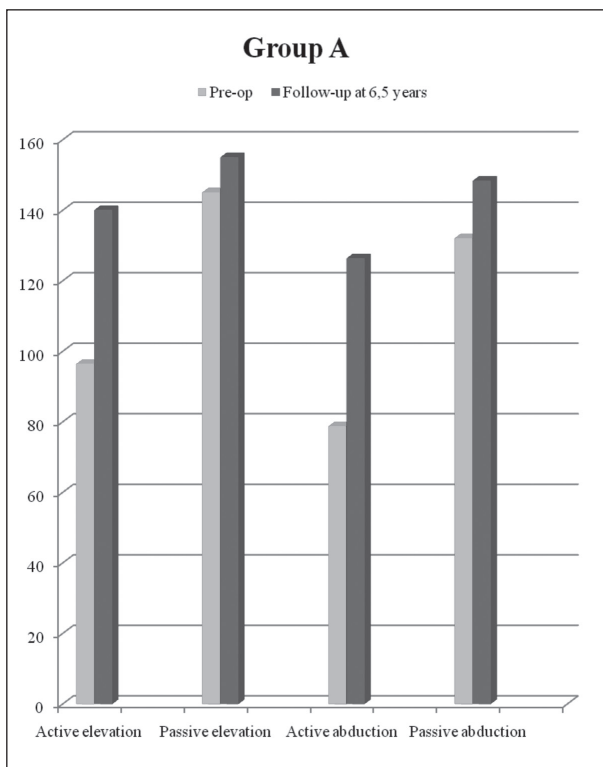
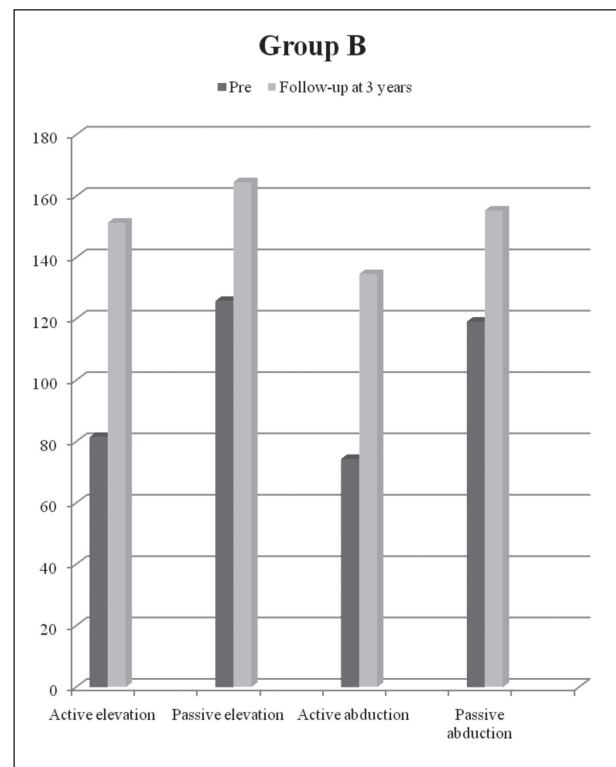
**Table 2.** Results of ROM and Constant Score in Group B

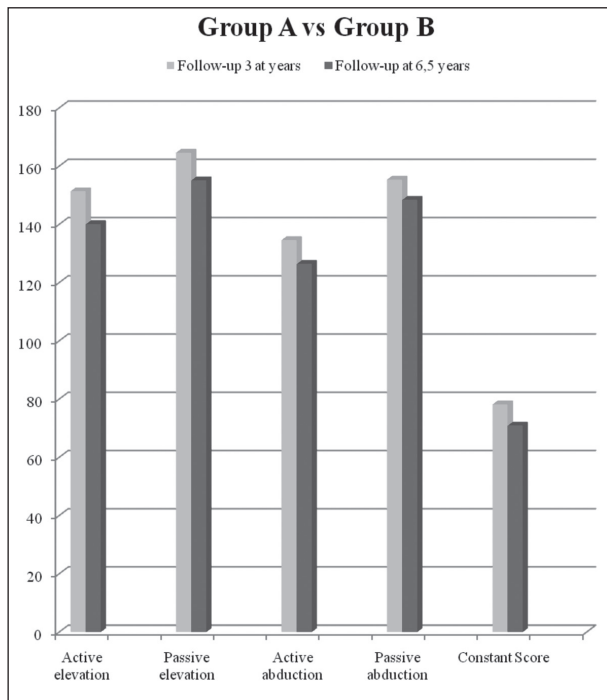
	Pre-operative	Follow-up at 3 years
Average passive elevation	125.75°±31.83° (70°-180°)	164.50°±22.06° (90°-180°)
Average active elevation	81.38°±33.98°(30°-160°)	151.25°±26.11° (60°-180°)
Average passive abduction	119°±34.7°(30°-160°)	155.25°±30.71° (60°-180°)
Average active abduction	74.25°±33.58°(60°-180°)	134.50°±32.57° (40°-180°)
Average Constant Score	48.38±11.85(19-69)	78.05±15.06 (35-95)

Between group A and group B we didn't find statistical significant difference (Graphic 3).

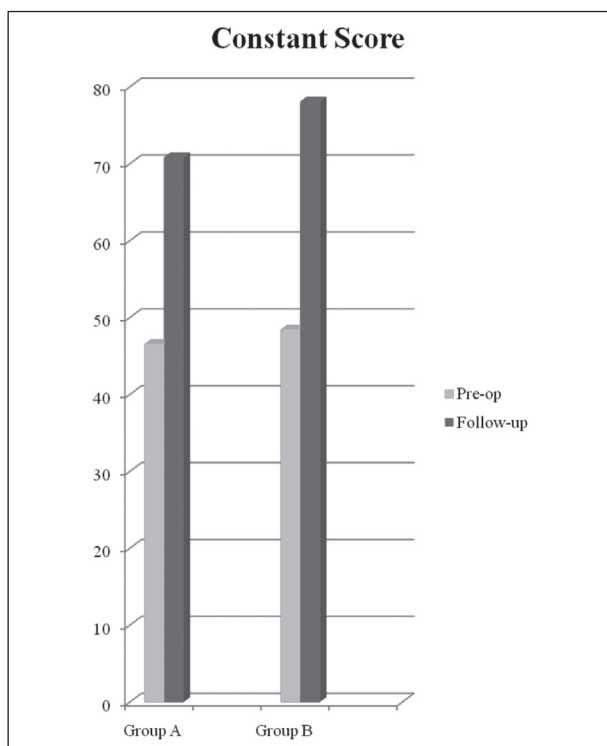
In Constant Score, we found statistical significant

difference between data before surgery and follow-up of group A and group B, and between group A and group B (Graphic 4).

**Graphic 1.** Difference in ROM between data before surgery and follow-up at 6,5 years**Graphic 2.** Difference in ROM between data before surgery and follow-up at 3 years



**Graphic 3.** Difference in ROM and in Constant Score between follow-up at 3 and 6,5 years



**Graphic 4.** Difference in Constant Score between pre-operative data and follow-up at 3 and 6,5 years

### Discussion

This study shows that partial repair for irreparable rotator cuff tear is a good surgery choice, as confirmed by the following studies.

Berth et al. in their study described that partial repair had a better outcome (DASH, Constant Score, ROM) than simple debridement with a follow-up of two years (17); with the same follow-up period, Iagulli et al. reported no difference in outcome (UCLA) between partial and complete repair (18). Randelli et al. had satisfactory result in outcome (ROM, DASH, SST) at a 3 years follow-up (19). On the other way, Anderl et al. affirmed that complete repair has a better outcome (DASH, Constant Score) in short-term follow-up (42 months) than partial repair and debridement (14). Porcellini et al, with a follow-up of 5 years described a better outcome (SST, Constant Score) than pre-operative data (2); in this study Constant score increased from 44 to 73, which is comparable to our study Constant Score values: pre-operative values were 46.52 and 48.38 respectively in group A and in group B; we found increased values in both of the group, 70.82 in group A at 6,5 years follow-up and 78.05 in group B at 3 years follow-up. Denaro et. al, with a long-term follow-up of 7.8 years, affirmed that there is still difference in outcome (ROM, modified UCLA) that pre-operative data (13); in this study forward flexion in partial repair group passed from 111.5° to 172.9° at 2 years and to 163.5° at 7,8 years. We found similar evolution of values in our study: active elevation in group B (3 years follow-up) passed from 81.38° to 151° and in group A (6.5 years follow-up) from 96° to 140°.

Analyzing difference between group A e group B, we note that there is no relevant difference in ROM but there is in Constant Score values: this may indicate the begin of the partial repair failure. Then, in according to our data, 6-7 years may be considered the time limit for this surgery technique. This concept can be confirmed from evolution of ROM in forward flexion in Denaro et al. study (13) as shown above: at 7,8 years values decreased compared to 2 years follow-up values.

In group B, we found no relevant difference only in passive elevation: this can be considered normal in massive rotator cuff tear, where pre-operative passive ROM could be not so limited.

Limits of this study are the lack of a control group treated with debridement or complete repair, small sample size, the lack of a control MRI at follow-up to evaluate muscle atrophy or fatty degeneration.

We conclude that partial repair in irreparable rotator cuff tear can give good results in a long-term follow-up, in terms of pain relief and improvement of ROM and as well as quality of life. It is a minimally invasive technique that, in case of failure, does not affect any subsequent surgeries.

## References

- Lädemann A, Denard PJ, Collin P. Massive rotator cuff tears definition and treatment. *International Orthopaedics (SICOT)* 2015; 39: 2403-14.
- Porcellini G, Castagna A, Cesari E, Merolla G, Pellegrini A, Paladini P. Partial repair of irreparable supraspinatus tendon tears: clinical and radiographic evaluations at long-term follow-up. *J Shoulder Elbow Surg* 2011; 20: 1170-7.
- Cofield RH. Subscapular muscle transposition for repair of chronic rotator cuff tears. *Surg Gynecol Obstet* 1982; 154: 667-72.
- Gerber C, Fuchs B, Hodler J. The results of repair of massive tears of the rotator cuff. *J Bone Joint Surg Am* 2000; 82: 505-15.
- Castricini R, De Benedetto M, Orlando N, Gervasi E, Castagna A, et al. Irreparable rotator cuff tears: a novel classification system. *Musculoskelet Surg* 2014; 98 (Suppl 1): S49-S53.
- Nove-Josserand L, Edwards TB, O'Connor DP, Walch G. The acromiohumeral and coracohumeral intervals are abnormal in rotator cuff tears with muscular fatty degeneration. *Clin Orthop Relat Res* 2005; 433: 90-6.
- Hamada K, Fukuda H, Mikasa M, Kobayashi Y. Roentgenographic findings in massive rotator cuff tears: a long-term observation. *Clin Orthop Relat Res* 1990; 254: 92-6.
- Werner CM, Conrad SJ, Meyer DC, Keller A, Hodler J, Gerber C. Intermethod agreement and interobserver correlation of radiologic acromiohumeral distance measurements. *J Shoulder Elb Surg* 2008; 17: 237-40.
- Warner JJ, Higgins L, Parsons IM, Dowdy P. Diagnosis and treatment of anterosuperior rotator cuff tears. *J Shoulder Elbow Surg* 2001; 10: 37-46.
- Thomazeau H, Rolland Y, Lucas C, Duval JM, Langlais F. Atrophy of the supraspinatus belly: assessment by MRI in 55 patients with rotator cuff pathology. *Acta Orthop Scand* 1996; 67(3): 264-8.
- Patte D. Classification of rotator cuff lesions. *Clin Orthop Relat Res* 1990; 254: 81-6.
- Goutallier D, Postel JM, Bernageau J, Lavau L, Voisin MC. Fatty muscle degeneration in cuff ruptures: pre- and post-operative evaluation by CT scan. *Clin Orthop Relat Res* 1994; 304: 78-83.
- Franceschi F, Papalia R, Vasta S, Leonardi F, Maffulli N, Denaro V. Surgical management of irreparable rotator cuff tears. *Knee Surg Sports Traumatol Arthrosc* 2015; 23: 494-501.
- Heuberger PR, Kölblinger R, Buchleitner S, Pauzenberger L, Laky B, Auffarth A, Moroder P, Salem S, Kriegleder B, Anderl W. Arthroscopic management of massive rotator cuff tears: an evaluation of debridement, complete, and partial repair with and without force couple restoration. *Knee Surg Sports Traumatol Arthrosc* 2015 [Epub ahead of print].
- Khair MM, Gulotta LV. Treatment of irreparable rotator cuff tears. *Curr Rev Musculoskelet Med* 2011; 4: 208-13.
- Burkhart SS, Nottage WM, Ogilvie-Harris DJ, Kohn HS, Pachelli A. Partial repair of irreparable rotator cuff tears. *Arthroscopy* Burkhardt SS, Nottage WM, Ogilvie-Harris DJ, Kohn HS, Pachelli A. Partial repair of irreparable rotator cuff tears. *Arthroscopy* 1994; 10(4): 363-70.
- Berth A, Neumann W, Awiszus F, Pap G. Massive rotator cuff tears: functional outcome after debridement or arthroscopic partial repair. *J Orthop Traumatol* 2010; 11: 13-20.
- Iagulli ND, Field LD, Hobgood ER, Ramsey JR, Savoie FH 3rd. Comparison of partial versus complete arthroscopic repair of massive rotator cuff tears. *Am J Sports Med* 2012; 40(5): 1022-6.
- Arrigoni P, C. Fossati C, Zottarelli L, Ragone V, Randelli P. Functional repair in massive immobile rotator cuff tears leads to satisfactory quality of living: Results at 3-year follow-up. *Musculoskelet Surg* 2013 Jun; 97 Suppl 1: 73-7.

Received: 16 July 2017

Accepted: 5 August 2017

Correspondance:

Paolo Di Benedetto, MD, PhD

Clinica Ortopedica

Azienda Ospedaliero-Universitaria di Udine

P.le S.Maria della Misericordia, 15 - 33100 Udine

Tel. +39 0432 559464

Fax +39 0432 559298

E-mail: paolo.dibenedetto@asuud.sanita.fvg.it