

## Role of Transesophageal 3D Echocardiography in adult cor triatriatum diagnosis

*Walter Serra, Giorgio Benatti, Andrea Biagi*

Cardiology Division, University Hospital Parma, Italy

**Summary.** Cor triatriatum is a very rare congenital abnormality, symptomatic during childhood; the non restrictive form is usually diagnosed as an incidental finding. We report the case of a 88 years old man referred to our hospital for elective endovascular repair of an aortic aneurysm; transthoracic cardiac bidimensional echocardiography showed an abnormal mass into the left atrium and a the diagnosis of cor triatriatum was fully made by a three dimensional transesophageal echocardiography. 3D echocardiography is an excellent noninvasive method that provides a rapid bedside diagnosis, without having to use ionizing radiation. ([www.actabiomedica.it](http://www.actabiomedica.it))

**Key words:** cor triatriatum; three dimensional transesophageal echocardiography

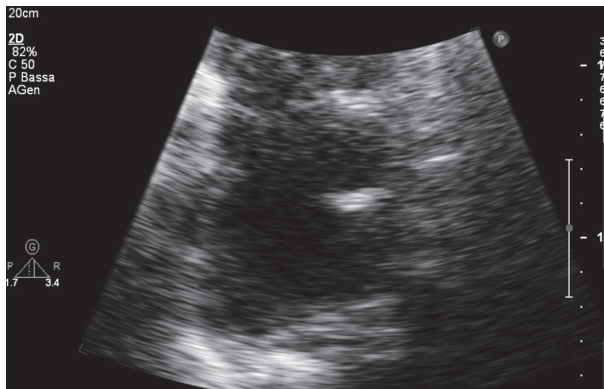
### Background

Cor triatriatum is a rare congenital anomaly in which the left or right atrium is divided into two parts by a membrane or a fibromuscular band and while the restrictive form tends to manifest at younger ages with symptoms of left atrial pressure overload, resembling the clinical presentation of mitral stenosis, the non-restrictive form is usually diagnosed as an incidental finding (1, 2).

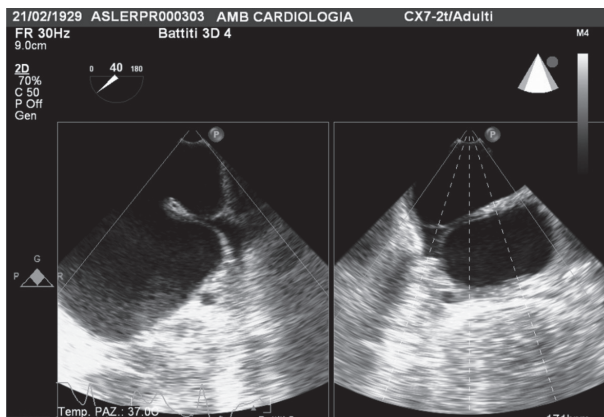
We report the case of a 88 year-old man scheduled for elective endovascular repair of an aortic aneurysm, was referred to our Echocardiography Lab for a pre-operative evaluation. His cardiovascular risk factors comprised previous smoking habit, hypertension and dyslipidemia. His past medical history was remarkable for myocardial infarction treated with fibrinolysis and subsequent dual-chamber Pacemaker implantation for complete AV block.

Transthoracic echocardiography showed a non-dilated left ventricle with a mildly reduced ejection fraction, no significant valvular disease, normal right

chambers and moderately dilated left atrium, which interestingly revealed the presence of a hyperechogenic formation, best visualized in the four-chamber apical view, apparently attached to the left atrial lateral wall and protruding in the atrial lumen (Fig. 1). Due to poor transthoracic windows, it was hard to thoroughly define the nature of the finding and we therefore decided to perform a Transesophageal two-dimensional echocardiography (TOE) for a better characterization. At visualization with TOE and 3D reconstruction, the formation appeared to be a fibromuscular band, extending from the ridge between the left atrial appendage and the left superior pulmonary vein to the posterior aspect of the interatrial septum (Fig. 2). A wide opening remained between the posterosuperior and the anteroinferior portions of the atrium and, in fact, no gradient developed across the membrane at continuous-wave doppler interrogation. Moderate regurgitation was detected (Fig. 3 A-B-C-D). The finding was therefore consistent with a diagnosis of non-restrictive cor triatriatum sinister. A conservative treatment was indicated.



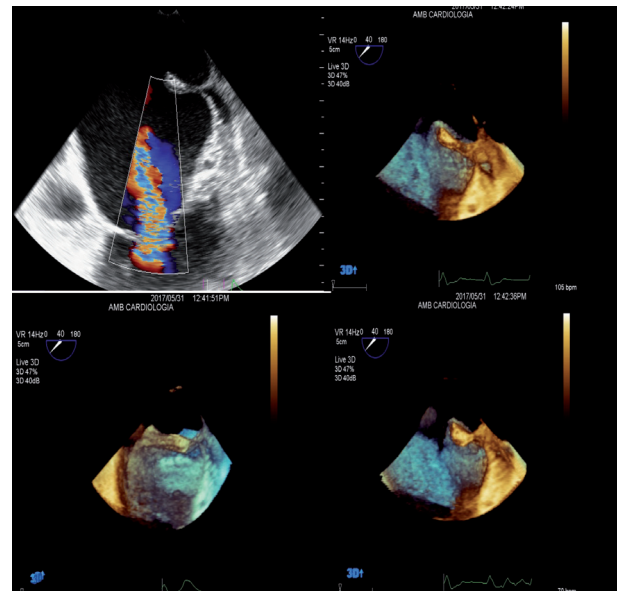
**Figure 1.** Transthoracic two-dimensional echocardiography showing a hyperechogenic mass, in the four-chamber apical view, apparently attached to the left atrial lateral wall and protruding in the atrial lumen



**Figure 2.** By TOE evaluation, the formation appeared to be a fibromuscular band, extending from the ridge between the left atrial appendage and the left superior pulmonary vein

## Discussion

Cor triatriatum is among the rarest of all congenital cardiac anomalies accounting for 0.1-0.4% of congenital heart disease (1, 2). In this malformation the left atrium is divided by an abnormal fibromuscular diaphragm into a posterosuperior chamber or embryonic common pulmonary vein, receiving the pulmonary veins and an anteroinferior chamber or embryonic left atrium giving rise to the left atrial appendage and leading to the mitral orifice (3). The two chambers generally communicate through one or more openings in the intra-atrial membrane. Cor triatriatum was first



**Figure 3.** A-B-C-D. TOE demonstrates with 3D reconstruction a clear visualization of the fibromuscular band, wide opening remained between the posterosuperior and the antero-inferior portions of the atrium. No gradient developed across the membrane at continuous-wave doppler interrogation. Moderate mitral regurgitation was detected

described by Church in 1868 (4). Several classification schemes have been proposed for describing cor triatriatum; the simplest was proposed by Loeffler in 1949 (5). It is based on the number and size of fenestrations in the fibromuscular membrane dividing the left atrium. The embryologic etiology may result from incomplete incorporation of the common pulmonary vein into the left atrium (1, 4, 6). Interestingly, in this clinical scenario it was possible to reach a definite diagnosis only by means of transthoracic and transesophageal echocardiography with 3D reconstruction (7, 8). We decided not to perform further diagnostic evaluation, such as cardiac CT (9, 10) or angiography for the full evaluation of the characteristics of the abnormality by TOE3D reconstruction.

## Conclusion

There are multiple imaging techniques used in the diagnosis of cor triatriatum, such as computed tomography, and magnetic resonance imaging. 3D echo-

cardiography is an excellent noninvasive method that provides a rapid bedside diagnosis, without having to use ionizing radiation.

#### Authors' contributions:

WS, contributed in the literature review, writing and correcting the manuscript, and echographic images acquisition GB and AB helped in the literature review and writing the manuscript. All authors read and approved the final manuscript.

#### References

1. Griffith TW. Note on a Second Example of Division of the Cavity of the Left Auricle into Two Compartments by a Fibrous Band. *J Anat Physiol* 1903 Apr; 37: 255-7 [Medline].
2. Richardson JV, Doty DB, Siewers RD, et al. Cor triatriatum (subdivided left atrium). *J Thorac Cardiovasc Surg* 1981 Feb; 81(2): 232-8 [Medline].
3. Chen Q, Guhathakurta S, Vadalapali G, et al. Cor triatriatum in adults: three new cases and a brief review. *Tex Heart Inst J* 1999; 26(3): 206-10 [Medline] [Full Text].
4. Church WS. Congenital malformation of heart: abnormal septum in left auricle. *Trans Path Soc* 1868; 19: 188-90.
5. Loeffler E. Unusual malformation of the left atrium: pulmonary sinus. *Arch Pathol* 1949; 48: 371-6.
6. Niwayama G. Cor triatriatum. *Am Heart J* 1960 Feb; 59: 291-317 [Medline].
7. Tuccillo B, Stumper O, Hess J, et al. Transoesophageal echocardiographic evaluation of atrial morphology in children with congenital heart disease. *Eur Heart J* 1992 Feb; 13(2): 223-31 [Medline].
8. Einav E, Perk G, Kronzon I. Three-dimensional transthoracic echocardiographic evaluation of cor triatriatum. *Eur J Echocardiogr* 2008 Jan; 9(1): 110-2 [Medline].
9. Malik A, Fram D, Mohani A, Fischerkeller M, Yekta A, Mohyuddin Y. Taub Cor triatriatum: a multimodality imaging approach. *C Can J Cardiol* 2008; 24(3): e19-20
10. Chen K, Thng CH. Multislice computed tomography and two-dimensional echocardiographic images of cor triatriatum in a 46-year-old man. *Circulation* 2001 Oct 23; 104(17): 2117 [Medline].

Received: 27 July 2017

Accepted: 7 August 2017

Correspondence:

Walter Serra

Cardiology Division, Surgery Department

University Hospital Parma,

Via A. Gramsci, 14 - 43100 Parma, Italy

Tel. +39 0521/991070

E-mail address: wserra@libero.it