

## C A S E R E P O R T

# Hypochlorite accident during endodontic therapy with nerve damage – A case report

*Silvia Perotti<sup>1</sup>, Paola Bin<sup>1</sup>, Rossana Cecchi<sup>2</sup>*

<sup>1</sup>Department of Medical and Surgical Specialties, Radiological Sciences, and Public Health, University of Brescia, Italy; <sup>2</sup>Department of Anatomical, histological, medico-legal and orthopaedic sciences, University of Rome, Italy

**Summary.** Endodontic therapy is a routinely practised clinical procedure with few reported complications but, as a bleaching agent, inadvertent spillage of sodium hypochlorite beyond the root canal system may result in extensive soft tissue or nerve damage, and even airway compromise. Although very rare, complications arising from hypochlorite extrusion beyond the root apex are described. NaOCl causes oxidation of protein and lipid membrane and causes necrosis, hemolysis and dermal ulcerations (2-4). Neurological complications are very rare. Paraesthesia and anaesthesia may affect the mental, inferior dental and infra-orbital branches of the trigeminal nerve and normal sensation may take many months to completely resolve (6, 7). Nerve damage (the buccal branch) was described in 2005 by Witton et al. (8) and patients exhibited a loss of the naso-labial groove and a down turning of the angle of the mouth and the motor function was regained after several months. We present a case in which the extrusion of NaOCl solution during endodontic therapy led to important destructive effects on soft tissues and nerves. The arisen medico legal issues are discussed. ([www.actabiomedica.it](http://www.actabiomedica.it))

**Key words:** sodium hypochlorite, endodontic therapy, nerve damage, medical liability

## Introduction

Removal of bacteria from the root canal system during shaping and cleaning is the key factor for the success of endodontic therapy. Mechanical preparation should be supported by a chemically active antibacterial irrigation solution.

Sodium hypochlorite (NaOCl) was recognized as antibacterial agent since 1920 when Crane described its use for root canal debridement and sterilization (1).

Endodontic therapy is a routinely practised clinical procedure with few reported complications but, as a bleaching agent, inadvertent spillage of sodium hypochlorite beyond the root canal system may result in extensive soft tissue or nerve damage, and even airway compromise. Although very rare, complications arising from hypochlorite extrusion beyond the root apex are described. NaOCl causes oxidation of protein and

lipid membrane and causes necrosis, hemolysis and dermal ulcerations (2-4).

Treatment is determinate by the extent and rapidity of the soft tissue swelling but may necessitate urgent hospitalisation and administration of intravenous steroids and antibiotics. Surgical drainage or debridement may also be required (depending on the extent and character of the tissue swelling and necrosis (5)).

Neurological complications are very rare. Paraesthesia and anaesthesia may affect the mental, inferior dental and infra-orbital branches of the trigeminal nerve and normal sensation may take many months to completely resolve (6, 7).

Nerve damage (the buccal branch) was described in 2005 by Witton et al. (8) and patients exhibited a loss of the naso-labial groove and a down turning of the angle of the mouth and the motor function was regained after several months.

We present a case in which the extrusion of NaOCl solution during endodontic therapy led to important destructive effects on soft tissues and nerves. The arisen medico legal issues are discussed.

### Case report

In May 15 2013 a 34-year-old healthy woman was treated by her general dental practitioner and a non-surgical endodontic treatment was performed on her maxillary left first premolar tooth. During canal irrigation patient complained intense pain. She didn't know what kind of liquid was used but she reported to smell bleach.

At home, pain increased and patient had tense and warm swelling extending from the mandibular border to left eyelid with initial reduction in visual acuity. Patient tried to contact her general dentist but he didn't answer. The woman, worried for increasing symptoms, the same evening went to the Dental Clinic of the local Hospital and immediately transferred to the Emergency Department in the same Hospital.

On examination there was a firm left facial swelling and ecchymosis from below the border of the mandible up to the left eye. Doctors gave her antibiotic therapy and they quit on her with indication to return the next morning.

The next day, patient went again at the Civil Hospital of Brescia, where she submitted to maxillofacial visit. Doctors and patient contacted the dentist for information on the treatment performed. The dentist stated to used hydrogen peroxide at 10%. Doctor prescribed to the woman antibiotics and anti-inflammatory.

Two days later patient went back to the emergency department of the Hospital complaining alteration of vision of the eye left, an increased edema of the left cheek and an hemorrhagic episode of the oral cavity. Therefore, given the clinical, she was hospitalized at the Department of Maxillofacial Surgery of the same hospital.

Extra oral examination revealed significant soft tissue swelling extend from left intraorbital region to the mandibular border. Infraorbitally and in the region of the upper left lip, there was altered sensation. This is the area of the left infraorbital nerve. In addition

the buccal branch of the facial nerve was affected. This resulted in a distinct loss of upper lip and cheek function (the corner of the mouth could not be pulled up by the mimic musculature). Eye examination revealed blepharospasm and a TC examination revealed areas of bone resorption. NaOCl accident was suspected. To prevent risk of infection orally antibiotic therapy was administered for 7 days and ibuprofen was prescribed for pain management.

Both swelling and ecchymosis kept progressively decreasing during the follow up period but neurological symptoms didn't resolved.

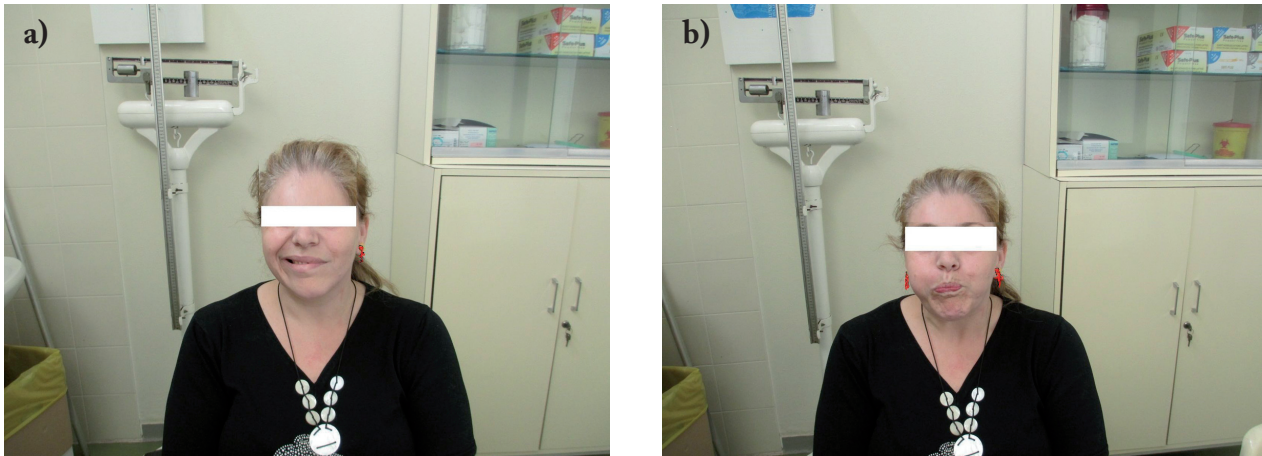
On neurological review one month later was found a deficit on left of the second branch of the fifth cranial nerve, of the seventh cranial nerve, of the ninth and the tenth cranial nerve. There were anesthesia and paraesthesia of the left side of the face, a detour to the left of the tongue (to the right during protrusion), deficit of left orbicularis muscle of the mouth, eye spasms during fixation and deficit of the sternocleidomastoid in the rotation of the head to the left.

One year later neurological symptoms resolved only partially. On examination it was confirmed nerve deficits on II branch of the fifth cranial nerve left, a slight deficit in the upper territory of the seventh cranial nerve left and a definite weakness in the lower area of the seventh cranial nerve left (Fig. 1a, b).

The patient filed legal claims against the dentist and the case was kept to the attention of the Penal Court.

### Discussion

Irrigation during chemo-mechanical shaping is critical to the success of root canal treatment. NaOCl is used as an endodontic irrigant as it is an effective antimicrobial and has tissue dissolving capabilities. Free chlorine in NaOCl dissolves vital and necrotic tissues by breaking down proteins into amino acids. It reacts with fatty acids and amino acids in dental pulp resulting in liquefaction of organic tissue. There is no universally accepted concentration of sodium hypochlorite for use as an endodontic irrigant. The antibacterial and tissue dissolution action increases with concentration, but this is accompanied by an increase in toxicity.



**Figure 1.** The neurological symptom of definite weakness in the lower area of the seventh cranial nerve left, one year later: assessed by smiling (1 a) and blowing (1 b)

It is usually used in concentrations ranging from 0.5 to 5.25% depending on the dilution and storage protocols of individual practitioners. It has been reported that 5.25% NaOCl was strong enough to kill the bacteria commonly present in the canal; however this concentration is highly toxic and irritating. The toxicity of NaOCl is due to its high alkalinity (pH 10.8-12.9) and hypertonicity (2-4).

When it comes into contact with vital tissue, it causes haemolysis, ulceration, inhibits neutrophil migration and damage endothelial and fibroblast cells.

When sodium hypochlorite extruded beyond the root canal into peri-radicular tissues, the effect is one of a chemical burn leading to a localised or extensive tissue necrosis. A severe acute inflammatory reaction of tissue develops. This leads to rapid tissue swelling both intra-orally within the surrounding mucosa and extra-orally within the skin and subcutaneous tissues. The swelling may be oedematous and haemorrhagic. Sudden onset of pain is a hallmark of tissue damage, and may occur immediately or be delayed for several minutes or hours. Associated bleeding into the interstitial tissues results in bruising and ecchymosis of the surrounding mucosa and the facial skin and may include the formation of a haematoma. A necrotic ulceration of the mucosa adjacent to the tooth may occur as a direct result of the chemical burn, but this reaction may occur within minutes or may be delayed and appear some days later (9, 10).

The acute problems, sudden pain during root canal rinsing, the extensive swelling of the left face side, and the adverse effects to nerves and musculature, described in the case reported are typical for sodium hypochlorite and have been repeatedly published in the literature during past years (3, 11, 12).

The immediate sequel of the accidents includes severe sudden excruciating pain, probably related to tissue destruction and distension, as well as immediate swelling of the tissue in the area.

The majority of NaOCl extrusions into the periapical area are attributed to incorrect determination of the working length, excessive enlargement of the apical foramen, needle stuck within the root canal. Generally the apical anatomy of the tooth appears normal so presumably the combination of peri-apical bone destruction due to chronic infection and forced pressure irrigation lead to entry of sodium hypochlorite into the soft tissues, as well as administering lower concentrations of NaOCl decrease the risk of occurrence (6, 13).

In the case reported none of these essential measures was taken before the treatment.

There are few cases reported in the literature on post-operative altered nerve sensation and ocular complications arising from the use of NaOCl in endodontics. Few patients have reported permanent paresthesia and facial disfigurement (6). The present case is one of the few showing a permanent nerve weakness after inadvertent injection of NaOCl.

Facial nerve damage was first described by Witton et al. in 2005 (8). In those cases the buccal branch of the facial nerve was affected and both patients exhibited a loss of nasolabial groove and down turning of the angle of the mouth. Both patient were reviewed and their motor function was regained after several month. In our case instead, several month after the accident nerve deficits of the fifth and the seventh cranial nerve left were lasting.

Good medical practice indicates that after NaOCl extrusion into the tissue, local anesthesia should be administered for pain relief, and the canal should be irrigated immediately with copious amount of physiologic saline. Analgesic and antibiotics should be prescribed for postoperative pain control and to prevent secondary infections. Non-surgical management may be sufficient when treating the damage caused by misuse of NaOCl, but surgical intervention should be considered if there is progression of the ill effects.

Surgical intervention may be considered in some cases depending on the level of injury and the response to treatment. The goal of surgical intervention is to achieve decompression, ease drainage and improve prognosis (6).

The clinical features of our case were consistent with severe soft tissue damage due to a sudden chemical burn, following extrusion of NaOCl into the connective tissues. Liability issues can be found in the combination of periapical bone destruction, unfilled root canal, or high pressure during irrigation, and a high concentration of NaOCl in the irrigant solution. These presumably led to the easy entry of NaOCl into the soft tissues of the left face side. Moreover there was no immediately irrigation with solutions able to eliminate or neutralize the NaOCl. Nevertheless the permanent neurological consequences were caused by the delay in identifying the liquid used for the treatment avoiding the immediately irrigation of the canal with copious amount of physiologic saline.

## Conclusions

Sodium hypochlorite can cause severe complications during routine dental treatment and must be used with extreme care. To minimize the risks and pro-

vide appropriate treatment to affected patients, dental practitioners and clinicians should have a thorough understanding of the patho-physiology and potential complications of misuse of this agent and they should execute essential preventive measures before the treatment such as accurate measurement of the working length or working radiographs.

The case presented proves that NaOCl is able to produce permanent facial and trigeminal nerve weakness. From a medico-legal point of view a correct informed consent, before endodontic treatment, should include information on the adverse reactions of NaOCl. A proper protocol and management of complications are mandatory.

## References

1. Teggimani VS, Chawla VL, Kahate MM, Jain VS. Hypochlorite accident – a case report. *Endodontology (Indian Endodontic Society)* 2011; 23: 89-94.
2. Mehdipour O, Kleier DJ, Averbach RE. Anatomy of sodium hypochlorite accident. *Compend Contin Educ Dent* 2007;10: 544-546, 548, 550.
3. Hülsmann M, Hahn W. Complications during root canal irrigation—literature review and case reports. *Int Endod J* 2000; 33(3): 186-93.
4. Singh PK Root canal complications: 'the hypochlorite accident'. *SADJ* 2010; 65(9): 416-4.
5. Gatot A, Arbelle J, Leiberman A, Yanai-Inbar I. Effects of sodium hypochlorite on soft tissues after its inadvertent injection beyond the root apex. *J Endod* 1991; 17(11): 573-4.
6. Pelka M, Petschelt A Permanent mimic musculature and nerve damage caused by sodium hypochlorite: a case report. *Oral Surg Oral Med Oral Pathol Oral Radiol Endod* 2008; 3: 106.
7. Gallas-Torreira MM, Reboiras-López MD, García-García A, Gándara-Rey J. Mandibular nerve paresthesia caused by endodontic treatment. *Med Oral* 2003; 8(4): 299-303.
8. Witton R, Brennan PA. Severe tissue damage and neurological deficit following extravasation of sodium hypochlorite solution during routine endodontic treatment *Br Dent J* 2005; 198(12): 749-50.
9. Boutsioukis C, Psimma Z, van der Sluis LW. Factors affecting irrigant extrusion during root canal irrigation: a systematic review. *Int Endod J* 2013; 46(7): 599-618.
10. Zehnder M, Kosicki D, Luder H, Sener B, Waltimo T. Tissue-dissolving capacity and antibacterial effect of buffered and unbuffered hypochlorite solutions. *Oral Surg Oral Med Oral Pathol Oral Radiol Endod* 2002; 94: 756-62.
11. Witton R, Henthorn K, Ethunandan M, Harmer S, Brennan PA Neurological complications following extrusion of

- sodium hypochlorite solution during root canal treatment. *Int Endod J* 2005; 38: 843-8.
12. Bowden JR, Ethunandan M, Brennan PA. Life-threatening airway obstruction secondary to hypochlorite extrusion during root canal treatment. *Oral Surg Oral Med Oral Pathol Oral Radiol Endod* 2006; 101: 402-4.
  13. Goswami M, Chhabra N, Kumar G, Verma M, Chhabra A. Sodium hypochlorite dental accidents, Paediatrics and International. *Child Health* 2014; 34(1): 66-9.

---

Received: 22 December 2016

Accepted: 3 April 2017

Correspondence:

Rossana Cecchi, MD

Legal Medicine, Faculty of Medicine

University of Parma, Italy

E-mail: rossana.cecchi@unipr.it