

# A three-year experience with medial-pedicle-based breast reduction for different mammary hypertrophy

Michele Pio Grieco, Nicolò Bertozzi, Eugenio Grignaffini, Edoardo Raposio

Department of Surgical Sciences, Plastic Surgery Division, University of Parma, Parma, Italy; Cutaneous, Mini-invasive, Regenerative and Plastic Surgery Unit, Parma University Hospital, Parma, Italy

**Summary.** *Background and aim:* The aim of breast reduction is to reduce excessive breast volume, ensuring an adequate vascular supply and sensitivity of the nipple-areola complex, as well as to produce an aesthetically pleasing final shape. The authors report on their experience with medial-pedicle-based breast reduction combined with both vertical and inverted-T skin resection patterns for different types of breast hypertrophy. *Methods:* From January 2012 to June 2015, 27 female patients (mean age: 49 years) underwent reduction mammoplasty with the medial pedicle technique. The choices of medial pedicle base widths were: 6 cm for low-grade mammary hypertrophy (350-500 gr per breast), 6-8 cm for medium-grade hypertrophy (500-1000 gr per breast), or 8-10 cm for severe mammary hypertrophy (>1000 gr per breast). The authors chose the model of vertical skin resection for low-grade breast hypertrophy. The vertical model was used for medium-grade breast hypertrophy, and Wise skin resection was chosen on a case-by-case basis; only the Wise model was applied to severe breast hypertrophy. *Results:* The mean weight of breast excised was 540 g on the left (range, 207 to 1160 g) and 564.8 g on the right (range, 215 to 1150 g). The complications were minor and self-limiting. All patients reported relief of neck pain, back pain, and bra strap indentations after 6 months of follow-up. *Conclusions:* Breast reduction surgery must address both functional and aesthetic issue by restoring an aesthetically pleasing shape to ptotic or hypertrophic breasts, repositioning the NAC in a physiological position. Various breast reduction techniques have been attempted to combine the safety of the pedicle with aesthetic and functional results. Surgeons should tailor the best technique to each patient. We found that medial-pedicle-based reduction mammoplasty is effective and reliable because it can be applied to a wide range of breast hypertrophy, with reproducible breast weight reduction and results that are aesthetically satisfactory for both patients and surgeons. ([www.actabiomedica.it](http://www.actabiomedica.it))

**Key words:** breast reduction surgery, plastic surgery, medial pedicle, mammary hypertrophy

## Introduction

### Background

Breast reduction surgeries must address both aesthetic and reconstructive issues. Patients with large breasts may suffer from back, neck and shoulder pain, as well as bra strap grooving, and these patients could benefit from breast reduction surgery (1). The aim of this surgery is to reduce excessive breast volume, ensur-

ing adequate vascular supply and sensitivity of the nipple-areola complex (NAC), as well as to produce a final shape that is aesthetically pleasing (2-7). Various breast reduction techniques have been attempted to combine the safety of the pedicle with aesthetic and functional results. All involve a pedicle design (or free nipple graft) to move the NAC, a parenchymal resection pattern, and a skin resection pattern. Surgeons should be aware of different techniques to adapt to different patient presentations. In breast reduction, the pedicle,

the skin-resection pattern and the parenchymal-resection pattern must be considered separately. Six main pedicles have been described: the superior pedicle (8), the inferior pedicle (9,10), the lateral pedicle (3), the horizontal bipedicle (11), the vertical bipedicle (12,13), and the superomedial pedicle (14). With regard to skin resection pattern, an important advance was made in 1956, when Robert Wise designed a skin resection pattern adapted from a brassiere design, which came to be known as the inverted T (15). All pedicles were then adapted to the Wise skin resection pattern. Arie<sup>4</sup> first described reduction mammoplasty with a vertical scar in 1957 to eliminate the horizontal scar. In 1969, Lassus (11,16) developed the superior dermal-glandular pedicle for transposition of the NAC with a central *en bloc* excision of skin, fat, and glands, as well as a vertical scar. In 1994, Lejour (17-19) modified Lassus' technique and used pre-excision liposuction to eliminate the fat contributing to breast volume. In 1999, Hall-Findlay (20-24) modified the superomedial-pedicle-based mammoplasty ideated by Orlando (14) in 1975 and combined a full-thickness medial dermoglandular pedicle with a vertical skin resection pattern to transpose the NAC. This vertical skin excision pattern reduced the incidence of boxy appearance that sometimes occurred with the inverted T (15).

The vertical or inverted-T skin resection patterns have been applied to different pedicles and parenchymal resection patterns. Articles in the literature advocate for the supremacy of one technique over another, but what has emerged is the idea that "the best breast reduction is the one that the surgeon does the best" (24).

### *Aim*

In this paper, we report our experience with medial-pedicle-based breast reduction combined with both vertical and inverted-T skin resection patterns for different types of breast hypertrophy.

### **Methods**

At the Cutaneous, Mini-invasive, Regenerative and Plastic Surgery Unit (Parma University Hospital, Italy) from January 2012 to June 2015, 27 female pa-

tients aged 29 to 67 years (mean age: 49 years) underwent reduction mammoplasty with the medial pedicle technique. The average Body Mass Index (BMI) was 29.13 kg/m<sup>2</sup> (range, 22.3-33.3 kg/m<sup>2</sup>). The mean suprasternal notch to nipple distance was 27.4 cm (range, 23-35 cm) on the left breast and 27.6 cm (range, 23-34 cm) on the right breast.

The two main exclusion criteria for breast reduction surgery were: BMI >35 kg/m<sup>2</sup>, heavy smokers (25, 26) or patients who would not quit smoking between the period one month before and one month after surgery. Patients receiving oral contraceptives were told to stop the therapy one month before surgery.

Patients were required to sign informed consent prior to surgery and were educated about surgical and cosmetic risks: possible loss of sensation to the NAC or the skin breast, inability to lactate, NAC loss and breast asymmetry. Patients with severe hypertrophy (>1000 gr) were anxious due to the increased risk of poor cosmetic results with the vertical scar reduction mammoplasty; thus, they were informed of the need for the Wise skin resection pattern. A single surgeon performed all the procedures under general anesthesia; the mean operative time was 122 minutes (range, 96-142 minutes).

All patients underwent a medial-pedicle-based breast reduction surgery. The choice of the medial pedicle base width was determined by the degree of breast hypertrophy. The pedicle base widths were as follows: 6 cm for low-grade mammary hypertrophy (350-500 gr per breast), 6-8 cm for medium-grade hypertrophy (500-1000 gr per breast), and 8-10 cm for severe mammary hypertrophy (>1000 gr per breast). The skin resection pattern was driven by the degree of breast hypertrophy. The vertical skin resection pattern was used for low-grade mammary hypertrophy. For medium-grade mammary hypertrophy, both vertical and Wise skin resection pattern were chosen on a case-by-case basis; only the Wise pattern was applied to severe mammary hypertrophy. No liposuction procedures were performed.

Antibiotic therapy was administered in the immediate pre-operative phase and was continued until the 10<sup>th</sup> postoperative day (POD). Social activity was limited for 4 weeks after the day of discharge.

Patients were required to wear a bra at all times for 3 weeks following surgery. Patients were discharged at

the 3<sup>rd</sup> POD, and follow-up occurred on a weekly basis for the first month; they were then observed again at the 3<sup>rd</sup> and 6<sup>th</sup> month.

The follow-up period was 6 months; early and late complications were recorded. The patients' satisfaction was evaluated with a simple survey.

#### *Preoperative marking*

Preoperative design was performed as suggested by Hall-Findlay (20). First, we identified the inflammatory fold (IMF), which was easily located by placing a tape measure horizontally in the fold under both breasts. Then, the breast meridian (generally 9-11 cm from the midsternal line) was drawn straight from the midpoint of the clavicle until the IMF, on which the new NAC was typically located (usually 1-2 cm above the IMF) by placing one hand behind the breast to the level of the inframammary crease and projecting anteriorly onto the breast. This usually resulted in a suprasternal notch to nipple distance of 20-23 cm, depending on the height of the patient, the level of the IMF, and the desired size after the mastopexy. Because the ideal nipple position is slightly below the middle position on the breast mound, in case of an "empty" upper pole breast, the NAC was located 1-2 cm lower than it would have been with a "full" one.

To delineate the vertical limbs and thus the length of the medial and lateral flaps as well as the width of the extended pedicle, the breast was rotated laterally and superiorly and the vertical axis of the meridian was transposed to the displaced medial breast tissue. In the same fashion, the breast was subsequently rotated medially and superiorly so that the meridian was transposed to delineate the lateral extent of skin resection. Through use of a keyhole template, the areolar pattern was then drawn (spreading apart its limbs so they overlapped with the medial and lateral vertical pillars) with a diameter of approximately 5 cm and a periareolar scar length of less than 16. The inferior extent of the skin resection was marked in a "U" shape with the patient in supine position. The skin resection pattern thus resulted in the shape of a snowman.

The inferior limit of the skin excision was located 4-6 cm above the inframammary crease: shorter in

low- and medium-grade mammary hypertrophy and longer in severe hypertrophy.

Additionally, the Wise skin resection pattern was performed in the same fashion and employed only for the lower excision design. The medial and lateral vertical pillars were marked at 6 cm in length. The amount of skin to be resected was determined by pinching the breast between the thumb and the index finger; these two points were then drawn up to 1-2 cm above the lateral and medial extension of the IMF. Finally, the medial pedicle was drawn in a 'U' shaped pattern and extended down to within the vertical markings, stopping approximately 1 cm (at least) from the NAC to preserve the neuro-vascular plexus.

With the patient in the upright position, all of these marks were compared to assess their symmetry.

#### *Operative technique*

All incisions were made through the dermis with partial thickness and the area of the medial pedicle was de-epithelialized, leaving the deep dermis intact to prevent damage to the blood vessels traveling superficially through the pedicle. The surgical excision of skin, fat, and gland was performed *en bloc*, as outlined by the skin markings. The excision was extended down to the chest wall, leaving a layer of breast tissue over the pectoralis fascia to prevent bleeding, postoperative pain and NAC sensitivity deficiency. The lateral and inferior resection of the mammary gland was carried out with an inward cutting angle; the flaps were maintained at 2.5 cm thickness throughout their length. The excision was performed with the non-dominant hand constantly holding the pedicle in order to ensure it would not be undermined. A proper parenchymal resection was performed superiorly above the proposed nipple position to create a pocket for the auto-augmentation; an excess of breast tissue left in place could promote bottoming-out with time. A 0.5-1 cm thickness subcutaneous tissue was left at the IMF level. The pedicle was then safely rotated upwards (rotational angle between 30° and 90°) without risk of compression or torsion, and it was fixed to the upper pole. The lateral and medial pillars were sutured together by simple interrupted absorbable 3/0 subcutaneous sutures in place of Lejoure's technique, which leads to ruffling of the scar to shorten its length.

Although cutaneous wrinkling of the vertical scar associated with gathering of the skin would disappear 6 months postoperatively, the Lejoure suture technique could interfere with the blood supply of the skin edges, resulting in delayed healing. The skin was gathered beginning at the IMF. If the lengths of the vertical scar exceeded 5–6 cm, we associated a small horizontal scar, resulting in a short reverted T, to better distribute the excess skin reducing the tension over the vertical suture. All suturing of the skin was performed using a 4–0 Monocryl suture (Ethicon Inc, Somerville, NJ). Deep dermal, inverted sutures were used to inset the NAC. Intradermal, continuous sutures were used for closer approximation of skin edges of the periareolar wound.

Following the Wise pattern breast reduction mammoplasty, the surgical excision was performed *en bloc* as outlined by the skin markings. A 1–2 cm thick subcutaneous tissue was maintained underneath the wound edge at the medial and lateral portion of the IMF to reduce the occurrence of dog-ear. The pedicle was rotated as previously described. The first suture to

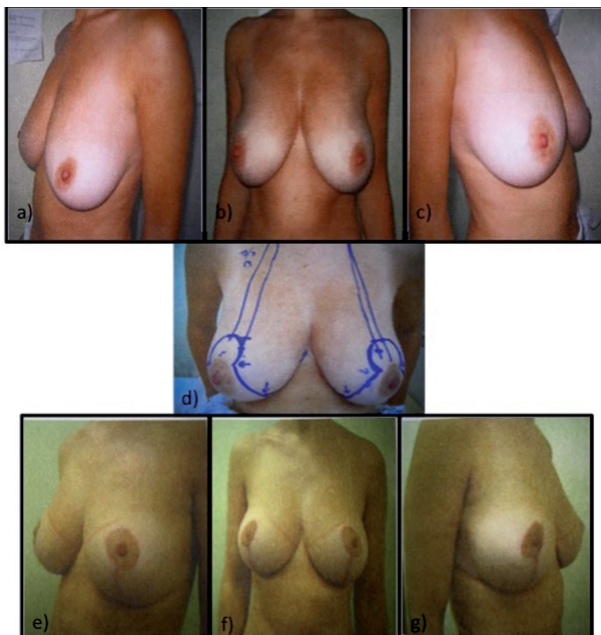be positioned was that at the apex of the inverted T, joining together the lowest portion of the lateral and medial pillars with the middle-point of the IMF by simple interrupted absorbable 2/0 subcutaneous suture. All sutures were performed as previously described.

One closed suction drainage was routinely placed in each breast before wound closure and was left in place until the output was less than 30 ml/day.

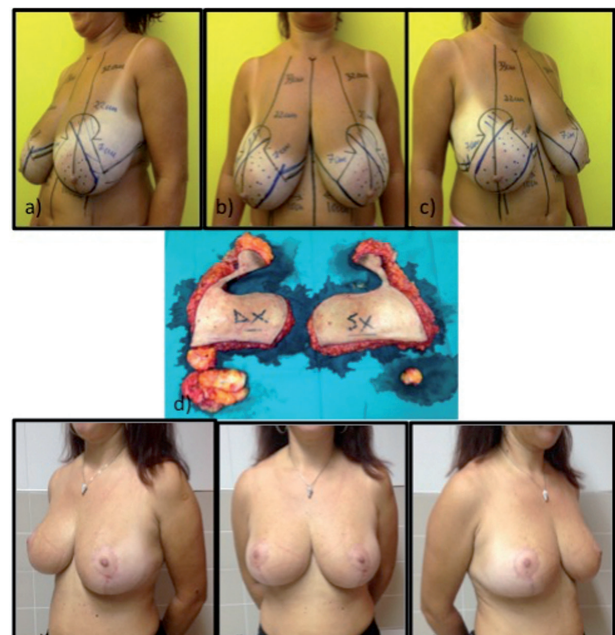
The wounds were dressed with dry gauze, while the NAC was dressed with paraffin gauze, followed by dry gauze. These were held in place by Hypafix (BSN Medical, Luxemburg). Wound dressings were held in place until the 3<sup>rd</sup> POD.

## Results

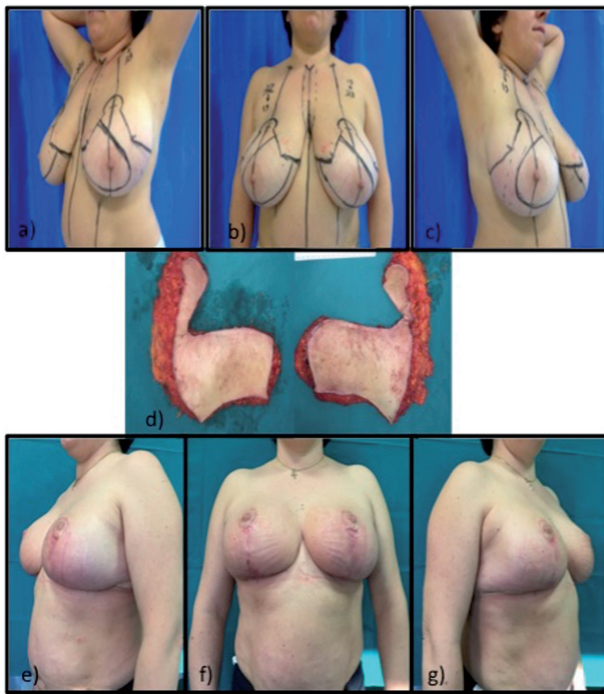We performed 54 breast reductions using the medial pedicle technique, from January 2012 to June 2015; 36 with a Wise pattern skin resection and 18 with a vertical one. There was no need for free-nipple graft.



**Figure 1.** A 37-year old female patient, who undergone medial-pedicle-based reductive mammoplasty with vertical skin resection pattern. The base of the medial pedicle was 6-cm width. The weight of the breast excised was 250 gr on the left and 270 gr on the right. The patient is shown preoperatively (a, b, c, d) and at 6° month after surgery (e, f, g)



**Figure 2.** A 48-year old female patient, who undergone medial-pedicle-based reductive mammoplasty with Wise skin resection pattern. The base of the medial pedicle was 7-cm width. The weight of the breast excised was 630 gr on the left and 590 gr on the right. (d) The patient is shown preoperatively (a, b, c) and at 6° month after surgery (e, f, g)



**Figure 3.** A 47-year old female patient, who undergone medial-pedicle-based reductive mammoplasty with Wise skin resection pattern. The base of the medial pedicle was 10-cm width. The weight of the breast excised was 1160 gr on the left and 1150 gr on the right. (g) The patient is shown preoperatively (a, b, c) and at 6<sup>o</sup> month after surgery (d, e, f)

The mean weight of breast excised was 540 g on the left (range, 207 to 1160 g) and 564.8 g on the right (range, 215 to 1150 g). At the 6<sup>th</sup>-month follow-up after surgery, the mean suprasternal notch to nipple distance obtained was 21.4 cm (range, 19-23 cm) on the left and 21.8 cm (range, 19-23 cm) on the right.

Breast and nipple projection was restored in all patients who were satisfied with nipple projection, and 25 of 27 (92.6%) patients reported satisfaction with breast shape. All patients reported relief of neck pain, back pain, and bra strap indentations.

Early complications were reported in 8 breasts (14.9%), and they were all managed conservatively. No seroma or infection was identified. After the Wise pattern skin resection, partial nipple and areola necrosis occurred in two breasts (5.5%), which healed with secondary intention without the need for revision and with repeated dressing. Hematoma formation occurred in 1 breast (2.7%). T-junction breakdown was limited to 3 breasts (8.3%) and was treated conservatively with repeated dressings; each case healed satisfactorily.

After the vertical pattern skin resection, NAC viability was maintained in all breasts. Hematoma formation occurred in 1 breast (5.6%), and there was one incidence of wound dehiscence of the vertical limb (5.6%), which was treated with simple dressing alone and did not require further revision surgery.

**Table 1.** Early and late complications

	Wise Skin Resection Pattern		Vertical Skin Resection Pattern	
	Breasts	%	Breasts	%
<b>Early Complications</b>				
Dehiscence at T-junction	3	8.3%	1	5.6%
Nipple-areola necrosis	2	5.5%	0	0%
Hematoma	1	2.7%	1	5.6%
Infection	0	0%	0	0%
Seroma	0	0%	0	0%
<b>Late Complications</b>				
Nipple-areola Sensory Loss	2	5.5%	0	0%
Under-reduction	0	0%	1	5.6%
Over-reduction	0	0%	0	0%
Scar Hypertrophy	1	2.7%	2	11.2%
Nipple Retraction	0	0%	0	0%
Contour Problems	0	0%	1	5.6%
Dog Ears	2	5.5%	0	0%
Hypo-Hyperpigmentation	0	0%	0	0%

Late complications were reported in 9 breasts (16.7%).

Sensation was assessed by light touch and patient response; it was retained in 34 of 36 breasts (94.4%) following reduction mammoplasty with Wise pattern skin resection and in all breasts after vertical pattern skin resection.

There was one case of under-reduction following vertical pattern skin resection mammoplasty, but the patient refused to undergo further surgery.

Scar hypertrophy was reported in 1 breast (2.7%) following reduction mammoplasty with Wise pattern skin resection and in 2 breasts (11.2%) after the vertical pattern. These were treated with monthly topical injection of a 40 mg/ml-suspension of triamcinolone acetonide, as well as daily topical application of a silicon-based cream for 6 months. The results obtained in all three cases were satisfactory. Dog-ears were observed in two breasts following vertical pattern skin resection mammoplasty; this complication was treated with a liposuction procedure three months from the surgery day. No NAC hypo-hyperpigmentation was observed.

## Conclusions

Breast reduction surgery aims to restore an aesthetically pleasing shape to ptotic or hypertrophic breasts, repositioning the NAC in a physiological position. Over the last century, several techniques have been designed to achieve this goal (3-23). These differ mainly in three features: the choice of the pedicle to ensure the viability of the NAC, the type of skin and the parenchymal resection pattern. Studies have been carried out to demonstrate the supremacy of one technique over another (15). As mentioned previously, what has emerged instead is the notion that surgeons should have several different options to apply the best technique to each patient.

The medial pedicle is a technique derived from the superomedial pedicle (14) that was modified and popularized by Hall-Findlay (20-23) with the vertical skin resection pattern.

Initially, Hauben (27) stated that the superomedial pedicle technique was suitable for breasts of "moderate

to rather large size." (28). Then, Finger et al. (29) demonstrated that resections as large as 4100 g and NAC transpositions of up to 30 cm were well tolerated, with nipple viability and preservation of sensation. Other studies followed, demonstrating that the medial pedicle reduction mammoplasty was safe and reliable, even in cases of severe mammary hypertrophy, as the pedicle contains the primary blood supply to the breast and is shorter than the interior pedicle in a given breast (30). Moreover, the lateral rotation of the pedicle from its base prevents excessive traction on the NAC, as well as stem twisting reductions in huge breasts. Breast shape and projection were enhanced when compared with amputation and free-nipple graft and were equivalent to results obtained with the inferior pedicle technique.

Advantages of a medially based pedicle include reliable circulation, preservation of NAC sensation, reduction of NAC hypopigmentation occurrence, and enhancement of central breast projection. An anatomical study by Michelle le Roux et al. (30). examined the neurovascular anatomy of female breasts on 11 cadavers, it showed that the nerve supply arise from the fourth intercostal nerve and play a unique role in NAC innervations (31). They also concluded that de-epithelialization or thinning of the superficial aspect of the superomedial pedicle could lead to vascular compromise or denervation of the NAC as the blood supply coursed through the pedicle in a superficial plane. They recommended that resection should be performed from the deep surface or the base of the pedicle if needed (30). This study supports the safety of the partial-thickness superior or medial pedicle design, which we used in our technique. The use of a full-thickness pedicle may prevent the successful implementation of the nipple-areola complex, folding and compromising the vascularization of the NAC.

Nahabedian et al. (32) confirmed that NAC sensitivity loss was directly related to breast size and consequent chronic nerve traction injury, and not to the technique performed. In our study, NAC sensation loss occurred in 2 breasts (2.7%) following reduction mammoplasty with the Wise pattern skin resection. One possible explanation is that we usually perform this type of surgery in patients with moderate/severe breast hypertrophy who could have suffered from chronic nerve traction injury, as stated above.

Vertical scar reduction mammoplasty using a medial pedicle improve long-term projection of the breasts, along with less scarring than inverted-T scar. We believe it is the inferior wedge resection of the redundant breast tissue that contributed to breast ptosis and that subsequent suturing of the medial and lateral pillars that result in coning of the breast are responsible for the long-term shape (21-32). Landau (33) applied the medial pedicle reduction mammoplasty with Wise pattern skin resection to 61 patients; he designed the medial pedicle with a base width of 10 cm and had a 90°-rotational angle. Serra (34) also performed the superior-medial pedicle for serious gigantomastia (>1200 g) with Wise pattern resection. Complication rates were similar to those reported in literature (15); wound dehiscence at the inverted T apex and the occurrence of dog-ears were the main complications. We experienced the same complication in our study, probably because we performed the Wise pattern skin resection in patients with moderate/severe breast hypertrophy, which resulted in more tension at the vertical scar and more parenchymal/adipose tissue to be excised.

Breast reduction surgery must address both functional and aesthetic issues. We found the medial-pedicle-based reduction mammoplasty effective and reliable because it can be applied to a wide range of breast hypertrophy, with reproducible breast weight reduction and results that are aesthetically satisfactory for both patients and surgeons. In accordance with other studies, we demonstrated that medial pedicle reduction mammoplasty is a safe surgical option, even for severe mammary hypertrophy. In addition, the operative time is short, and the complication rate is acceptably low. While agreeing with the statement that “the best breast reduction is the one that the surgeon does the best” (24), we regard the medial-pedicle-based reduction mammoplasty with both vertical and Wise skin resection patterns as an acceptable gold standard in various degrees of breast hypertrophy.

## References

1. Myint O, Zhuo W, Toshihiko S, et al. Relationship between brassiere cup size and shoulder-neck pain women. *The Open orthopaedics journal* 2012; 6: 140-142.
2. Penn J. Breast reduction. *Br J Plast Surg* 1955;7(4): 357-371.
3. Skoog T. A technique of breast reduction. Transposition of the nipple of a cutaneous vascular pedicle. *Acta Chir Scand* 1963; 126: 453.
4. Raposio E, Belgrano V, Santi P, Chiorri C. Which is the Ideal Breast Size? Some social Clues for Plastic Surgeons. *Ann Plast Surg* 2016; 76: 340-5.
5. Raposio E, Cicchetti S, Adami M, Ciliberti Rg, Santi PL. Computer planning for breast reconstruction by tissue expansion: an update. *Plast Reconstr Surg* 2004; 57: 2095-7.
6. Raposio E, Caregnato P, Barabino P, et al. Computer-based preoperative planning for breast reconstruction in the woman with unilateral breast hypoplasia. *Minerva Chir* 2002; 57: 711-4.
7. Fan J, Raposio E, Wang J, Nordström RE. Development of the inframmary fold and ptosis in breast reconstruction with textures tissue expanders. *Aesthetic Plast Surg* 2002; 26: 219-22.
8. Arie G. Una nueva tecnica de mastoplastia. *Rev Latinoam Cir Plast* 1957; 3: 23-38.
9. Courtiss EH, Goldwyn RM. Reduction mammoplasty by the inferior pedicle technique. *Plast Reconstr Surg* 1977; 59: 500.
10. Robbins TH. A reduction mammoplasty with the areola-nipple based on an inferior dermal pedicle. *Plast Reconstr Surg* 1977; 59: 64.
11. Lassus C. Update on vertical mammoplasty. *Plast Reconstr Surg*. 1999;104(7):2289-2304.
12. McKissock PK. Reduction mammoplasty with a vertical dermal flap. *Plast Reconstr Surg* 1972; 49: 245.
13. McKissock PK. Reduction mammoplasty by the vertical bipedicle flap technique. Rationale and results. *Clin Plast Surg* 1976 Apr; 3(2): 309-20
14. Orlando JC, Guthrie Jr RH. The superomedial pedicle for nipple transposition. *Br J Plast Surg* 1975; 28: 42.
15. Hall-Findlay EJ, Shestak KC. Breast Reduction. *Plast Reconstr Surg* 2015; 136: 531e-544e.
16. Lassus C. A 30-year experience with vertical mammoplasty. *Plast Reconstr Surg* 1996; 97(2): 373-380.
17. Lejour M. Vertical mammoplasty and liposuction of the breast. *Plast Reconstr Surg* 1994; 94(1): 100-114.
18. Lejour M. Vertical mammoplasty: Early complications after 250 personal consecutive cases. *Plast Reconstr Surg* 1999; 104(3): 764-770.
19. Lejour M. Vertical mammoplasty: Update and appraisal of late results. *Plast Reconstr Surg* 1999; 104(3): 771-784.
20. Hall-Findlay EJ. A simplified vertical reduction mammoplasty: Shortening the learning curve. *Plast Reconstr Surg* 1999; 104(3): 748-763.
21. Hall-Findlay EJ. Vertical breast reduction with a medially-based pedicle. *Aesthet Surg J* 2002; 22(2): 185-194.
22. Hall-Findlay EJ. Pedicles in vertical breast reduction and mastopexy. *Clin Plast Surg* 2002; 29(3): 379-391.
23. Hall-Findlay EJ. The three breast dimensions: Analysis and

- effecting change. *Plast Reconstr Surg* 2010; 125(6): 1632-1642.
24. Hall-Findlay. Discussion: A Matched Cohort Study of Superomedial Pedicle Vertical Scar Breast Reduction (100 Breasts) and Traditional Inferior Pedicle Wise-Pattern Reduction (100 Breasts): An Outcomes Study over 3 Years. *Plast Reconstr Surg* 2013; 132(5): 1077-79.
  25. Schumacher HH. Breast reduction and smoking. *Ann Plast Surg* 2005; 54(2): 117-19.
  26. Gamboa-Bobadilla GM, Killingsworth C. Large-volume reduction mammoplasty: the effect of body mass index on post-operative complications. *Ann Plast Surg* 2007; 58(3): 246-9.
  27. Hauben DJ. Experience and refinements with the superomedial dermal pedicle for nipple-areola transposition in reduction mammoplasty. *Aesthetic Plast Surg* 1984; 8: 189.
  28. Hauben DJ. Superomedial pedicle technique of reduction mammoplasty (Discussion). *Plast Reconstr Surg* 1989; 83: 479.
  29. Finger RE, Vasquez B, Drew GS, Given K S. Superomedial pedicle technique of reduction mammoplasty. *Plast Reconstr Surg* 1989; 83: 471.
  30. Le Roux MC, Kiil BJ, Pan WR, et al. Preserving the neurovascular supply in the Hall-Findlay superomedial pedicle breast reduction: An anatomical study. *J Plast Reconstr Aesthet Surg* 2010; 63(4): 655-662.
  31. Craig RD, Sykes PA. Nipple sensitivity following reduction mammoplasty. *Br J Plast Surg* 1970 Apr; 23(2): 165-72.
  32. Nahabedian MY, McGibbon BM, Manson PN. Medial pedicle reduction mammoplasty for severe mammary hypertrophy. *Plast Reconstr Surg* 2000; 105: 896.
  33. Landau AG, Hudson DA. Choosing the superomedial pedicle for reduction mammoplasty in gigantomastia. *Plast Reconstr Surg* 2008; 121(3): 735-9.
  34. Serra MP, Longhi P. The supero-medial dermal-glandular pedicle mastoplasty with Wise pattern: an easy technique with a shorten learning curve. Is it the gold standard for severe gigantomastia? *Ann Ital Chir* 2010 Sep-Oct; 81(5): 369-75.

Received: 27 September 2016

Accepted: 15 December 2016

Correspondence:

Michele P. Grieco, MD

Department of Surgical Sciences,

Plastic Surgery Division, University of Parma, Parma, Italy;

Cutaneous, Mini-invasive, Regenerative and Plastic Surgery

Unit, Parma University Hospital,

Via Gramsci 14, 43126 Parma, Italy

Tel. +39-0521-033525

Fax +39-0521-702041

E-mail: dr.mgrieco@yahoo.it