

# Total elbow arthroplasty following complex fractures of the distal humerus: results in patients over 65 years of age

Francesco Pogliacomi<sup>1</sup>, Paolo Schiavi<sup>1</sup>, Massimo Defilippo<sup>2</sup>, Filippo Calderazzi<sup>1</sup>, Maurizio Corradi<sup>1</sup>, Enrico Vaienti<sup>1</sup>, Francesco Ceccarelli<sup>1</sup>, Roberto Rotini<sup>3</sup>

<sup>1</sup>Orthopaedics and Traumatology Clinic, Department of Surgical Sciences. University of Parma, Parma, Italy; <sup>2</sup>Radiology Unit, Department of Surgical Sciences, University of Parma, Parma, Italy; <sup>3</sup>Shoulder and Elbow Unit of the Rizzoli Orthopaedic Institute of Bologna, Bologna, Italy

**Summary.** *Background:* The treatment of complex distal humerus fractures is challenging and is often associated with unsatisfactory results. Anatomic reduction and stable internal fixation is difficult to obtain, especially in elderly osteoporotic patients. For these reasons, total elbow arthroplasty (TEA) has recently evolved as a valid procedure in selected cases following these injuries. The aim of this study was to analyze outcomes of TEA for the treatment of complex distal humerus fractures in 20 low-demanding patients over 65 years of age. *Materials and methods:* All patients, at a mean follow-up of 60 months, were evaluated clinically using the Mayo Elbow Performance Score (MEPS) and radiographically in order to assess the positioning of the prosthetic components and signs of loosening. Statistical analyses investigated the presence of clinical and radiographic variables as predictive factors of poor functional outcomes. *Results:* Similar MEPSs were observed in the affected and unaffected arm. Results were good or excellent in 90% of the patients, even if a high rate of complications (35%) was encountered. The development of postoperative complications and concomitant cognitive impairment and rheumatoid arthritis were predictive factors of unsatisfactory outcomes. *Conclusions:* According to the results observed, TEA can be considered as a valid treatment for complex fractures of the distal humerus in low-demanding patients older than 65 years of age, in which a stable fixation is difficult to obtain. Several variables may influence the final outcomes. ([www.actabiomedica.it](http://www.actabiomedica.it))

**Key words:** elbow, arthroplasty, prosthesis, trauma, fracture, distal humerus

## Introduction

Fractures of the distal humerus are less frequent than those of the proximal humerus and in adults account for 2 % of all fractures and 5% of osteoporotic stress fractures in subjects over the age of 60 (1, 2). Two peaks of incidence are described: in males aged 12-19 years and in females aged 80 years and older (2). The most common causes are high-energy traumas in the younger and falls with direct impact on the elbow or on the outstretched arm in the elderly population.

In the last few years the incidence of these injuries has seemed to increase and could be multiplied by three by 2030 (3), because of a growing number of elderly people with low-density bone structure.

In these cases the management is more challenging as consequence of osteoporotic bone, comorbidities and articular comminution (4, 5).

Non-operative treatment results in a high risk of functional impairment and nonunion (2).

Open reduction and internal fixation (ORIF) can be tricky because of the fragile hold of the hardware

(2,6,7) and results, in approximately up to 25% of cases treated by ORIF, include pseudoarthrosis, residual pain, elbow instability and functional loss (1, 4-6, 8, 9).

Given these technical and clinical postoperative problems, some have indicated primary arthroplasty as a treatment (10-13), similarly to how complex proximal humerus fractures (14) and femoral neck fractures (15, 16) are treated.

TEA, that had been normally indicated for chronic inflammatory arthropaties (17), was initially proposed in fractures of the distal humerus by Cobb and Morrey in 1997 (11) with immediate encouraging results which were confirmed by other reports (1, 5, 6, 8, 9, 18, 19). All these authors underlined that TEA can be considered an alternative and valid option of treatment in selected cases because it provides immediate pain relief and a stable functional elbow, even if the complication rate is higher than in other joints (1, 5, 6, 8, 9, 18, 19).

The purpose of this study was to analyze clinical and functional results after TEA in complete intra-articular fractures of the distal humerus, classified by AO as type C (20), after a mean follow-up of 60 months, in 20 patients older than 65 years with low functional demands. Furthermore, authors tried to identify predictive factors of unsatisfactory results.

## Materials and methods

This retrospective case series study is the result of a collaboration between the Orthopaedic Clinic of the Department of Surgical Sciences of the University of Parma and the Shoulder and Elbow Unit of the Rizzoli Orthopaedic Institute of Bologna.

Between May 2002 and June 2014, 20 patients affected by complex type C fractures of the distal humerus, according to Muller AO classification (20), were surgically treated with total elbow prosthesis. Informed consent relating to the surgical and anesthesiological procedures were always obtained. Patients also gave their consent for the use of their personal data and clinical/instrumental outcomes for future scientific researches. All were functionally low-demanding subjects and those with a history of previous elbow infection were excluded.

Gender, mean age at the time of surgery, mean follow-up, hand dominance, type of fracture, prosthesis model, selected surgical approach and comorbidities, which could adversely affect the clinical and functional outcomes, were recorded.

Preoperative anteroposterior and lateral X-ray images of the elbow were used to classify the type of fracture.

Linked prosthetic models fixed with antibiotic-loaded cement (tobramycin at Rizzoli Hospital and clindamycin + gentamicin at the University Hospital of Parma) were always implanted. Two senior elbow surgeons (R.R. and M.C.) performed all surgical procedures. In all cases preoperative antibiotic prophylaxis with first generation cephalosporin was administered. Surgery was always done in supine position, with the arm placed over the chest and a haemostatic tourniquet at the base of the involved upper extremity. A triceps sparing approach or splitting posterior approach was used after the ulnar nerve was isolated and protected.

Postoperative management consisted in immobilizing the elbow in extension with an anterior univalve plaster of Paris cast or splint. Drains and the cast were removed 48h later to begin rehabilitation. The first 2 weeks of the early active mobilization programme consisted in gentle passive elbow extension within a pain free range and active flexion reaching no more than 90°. Active pro-supination was possible with the elbow flexed at 90° after 7-10 days. Therapy sessions were short but frequent during this period to avoid elbow stiffness and triceps muscle activation. In the following 2 weeks, overall elbow range of motion (ROM) was gradually increased by actively flexing the elbow beyond 90° and by actively extending the elbow with the assistance of gravity (the patient was supine with humerus resting alongside the body and supported with cushions or towels). No forceful contractions were allowed, and patient education was mandatory in this phase as the triceps tendon still required protection. The splint was still worn between sessions and at night. Following x-ray controls, the splint could be gradually dismissed during the day and worn at night for another 10-14 days. Therapy sessions became longer and more intensive as triceps strengthening was begun and passive stretching was applied to the joint. Mobilization splinting could be used after 3 months from surgery if

ROM limited the patient's function. The ultimate goal of rehabilitation was to reach ROM of 30° to 130° of extension and flexion as well as stability of the elbow in all planes. The patient was instructed to avoid impact activities and a lifetime lifting limitation of 3.6 kg with the operated-on arm during a single event and less than 0.9 kg if used repeatedly.

All patients were clinically assessed, at a minimum follow-up of 24 months, both on the operated and non-operated side using the MEPS (21).

At follow-up, in all cases radiographic assessment was done (anteroposterior and lateral views) in order to evaluate the positioning of the prosthetic components and signs of loosening in accordance with the Morrey radiolucency criteria (22).

Results were statistically analyzed using SPSS 20.0 software (IBM Corp, Armonk, NY, USA). Univariate analysis with the Mann-Whitney test (23) compared MEPS of the affected versus unaffected elbow at follow-up. Multiple linear regressions evaluated the presence of clinical or radiologic variables as predictive factors of poor functional outcomes. The difference was considered significant when the P value was <0.05.

## Results

Demographic data and comorbidities are reported in Table 1. All fractures of the distal humerus were complex (12 type C3.3 and 8 C3.2). The nondominant arm was involved in 11 patients, and 9 were affected on the dominant side.

A Coonrad-Morrey (Zimmer Inc, Warsaw, IN, USA) implant was used in 12 cases, and the Latitude prosthesis (Tornier NV, Amsterdam, The Netherlands) in the other 8. Prosthetic components were positioned through a "sparing triceps approach" in 13 patients and a "posterior splitting approach" in 7.

**Table 1.** Demographic data and comorbidities of the patients

Age (years)	74.1 (68-86)
Gender (M/F)	1/19
Hospitalization (days)	12.6 (6-45)
Associated diabetes	5
Associated cognitive impairment	4
Associated rheumatoid arthritis	4

The mean follow-up was 60 months (range: 24-168).

MEPS results are summarized in Table 2. These scores in the affected side were excellent in 12 patients (60%) (Figure 1), good in 6 (30%), fair in 1 (5%) and poor in 1 (5%). MEPSs of the contralateral elbows were considered excellent in all cases. Eighteen out of 20 patients reported absence of pain. Two subjects complained of low-grade pain at follow-up that did not compromise their normal daily activities (good results at MEPS). No prosthetic instability was documented.

In average, the patients were able to perform 4 out of 5 of the normal daily activities reported in MEPS, with a subjective improvement of the strength. The radiological analysis at follow-up is described in Table 3.

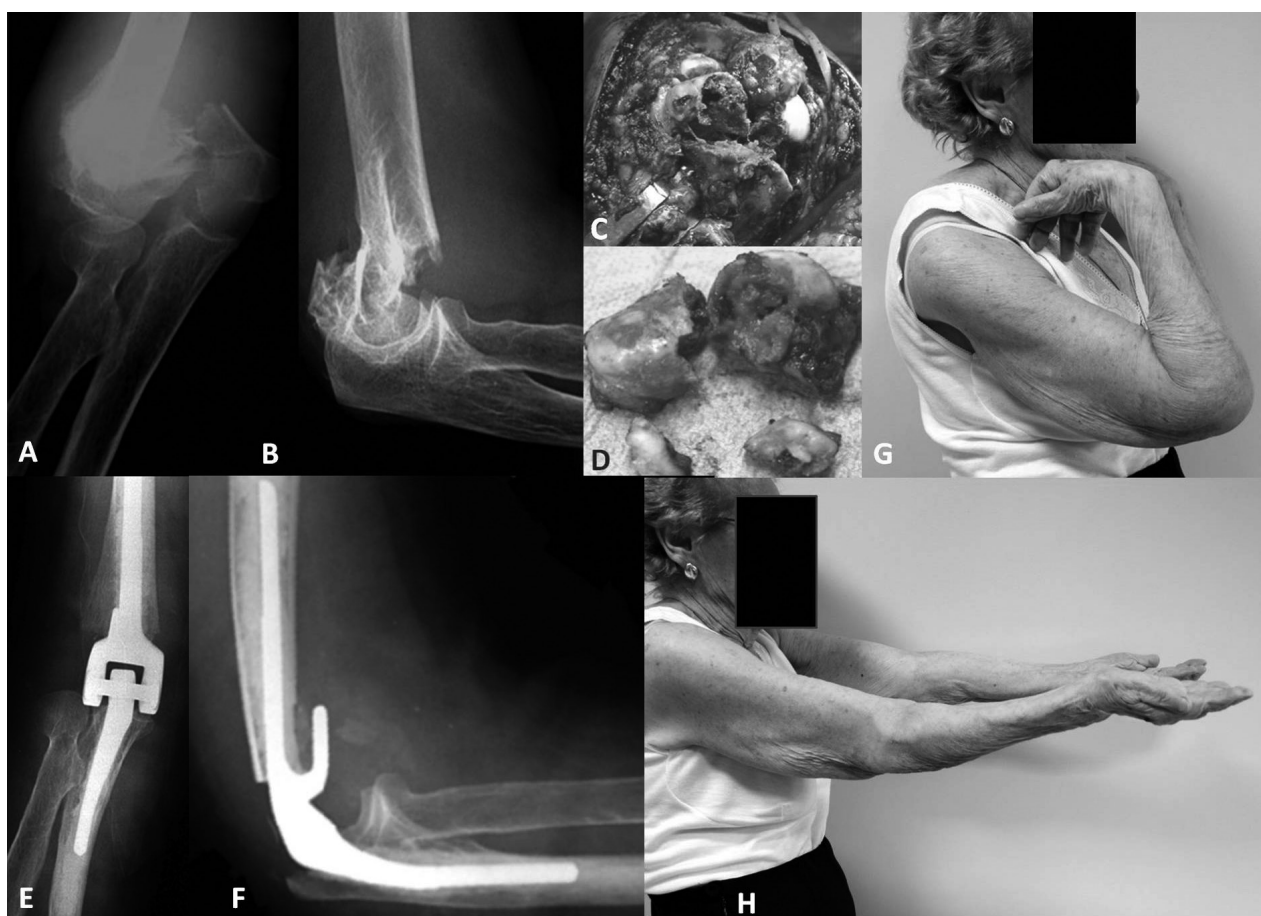In the post-operative period 7 patients (35%) had complications. A superficial wound infection developed in 2 subjects, which were treated with intravenous antibiotics and secondary wound debridement. Three patients developed a transitory impairment of the ulnar nerve which resolved spontaneously in less than six months from surgery. Two out of 20 cases, affected by severe cognitive impairment, showed a mean ROM <100°. The first case had a ROM of only 40° (fair result) and the second developed an ankylosis at 90° of flexion (poor result) (Figure 2). In this last subject a concomitant deep early infection was observed (*Staphylococcus Aureus*). Antibiotics therapy and

**Table 2.** Differences between MEPS of the affected vs. unaffected arm at follow-up

F.U. MEPS affected side	F.U. MEPS unaffected side	p value
88.7 (30-100)	91.7 (70-100)	0.529

**Table 3.** X-ray evaluation according to Morrey radiolucency criteria

No lines of radiolucency	16 (80%)
Type 0	3 (15%)
Type I	0
Type II	0
Type III	1 (5%)
Type IV	0



**Figure 1.** Type C3-3 right distal humerus fracture; preoperative x-rays (A and B), intraoperative views (C and D), radiographs (E and F) and clinical evaluation (G and H) 91 months after surgery (MEPS: 90; excellent result).

**Table 4.** Multiple linear regressions analyses of the variables which may influence outcomes

	p value
Type of fracture	0.790
Involvement of the dominant side	0.851
<b>Postoperative complications</b>	<b>0.045</b>
Type of prosthesis	0.250
Surgical approach	0.517
Concomitant diabetes	0.068
<b>Concomitant cognitive impairment</b>	<b>0.041</b>
<b>Concomitant rheumatoid arthritis</b>	<b>0.025</b>

wound cleaning were unsuccessfully and further revision surgery could not be performed because of other associated comorbidities.

Multiple linear regression analyses showed that postoperative complications and concomitant cogni-

tive impairment and rheumatoid arthritis were predictive factors of poor outcomes. Type of fracture, prosthesis model, surgical approach, involvement of the dominant side and diabetes were not predictive factors of poor outcomes (Table 4).

## Discussion

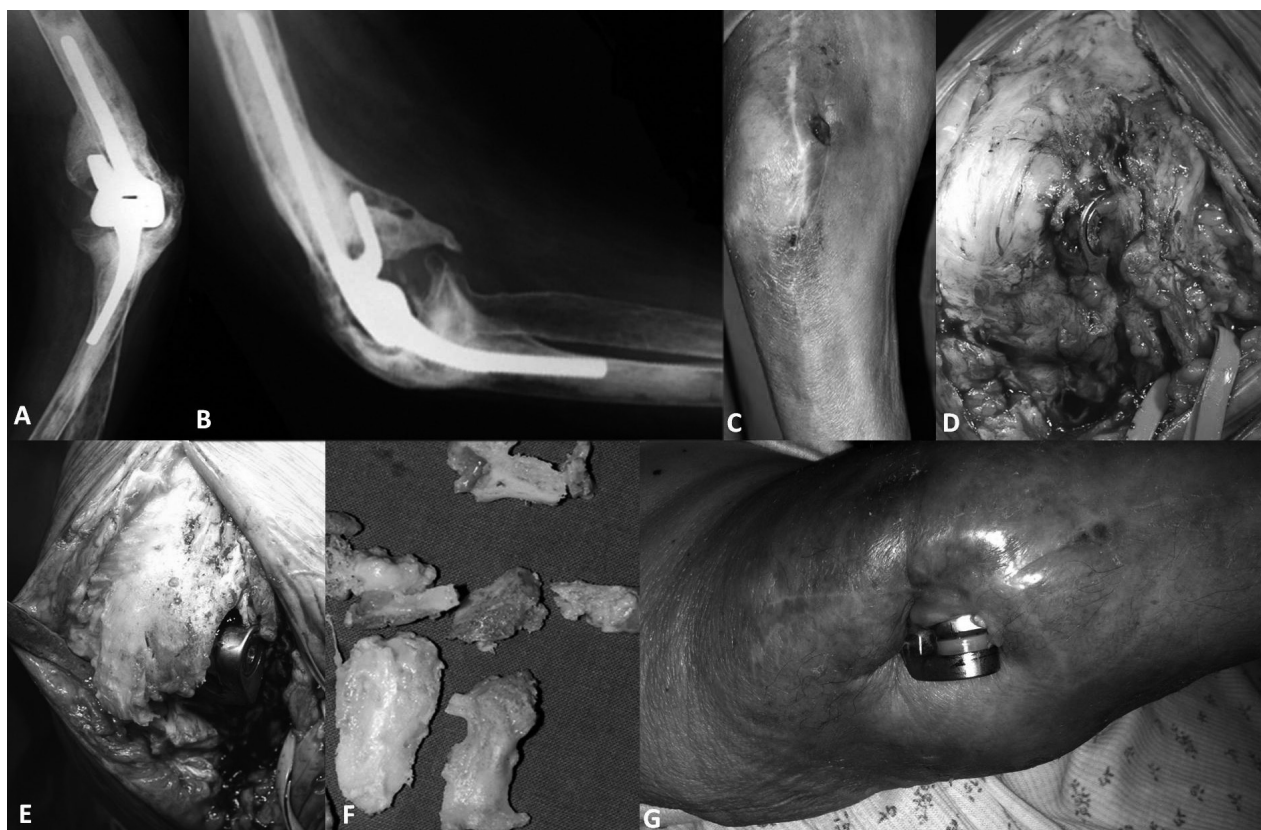
The correct management of complex fractures of the distal humerus remains a challenge also for experienced surgeon. Open reduction and rigid internal fixation, preserving the elbow and allowing early mobilization, is considered the gold standard of treatment in younger patients (5).

However, in elderly osteoporotic patients, the fractures are often complex and comminuted, thus



the hold of the fixation hardware can be precarious (6, 7) and additional bracing may be necessary, putting a strain on the functional prognosis (5, 17). Furthermore, this treatment is associated with a high rate of immediate and long term complications (i.e. heterotopic ossifications, hematomas, infections, ulnar nerve impairment, failure of fixation, limited function and non-unions), thus generally yielding poorer results which are characterized by an unstable, dysfunctional, and often painful elbow joint (1, 4, 5, 6, 11). Literature of the late 90's confirmed these observations. John et al (24) had 20% fair and poor results in their series of 49 elderly patients with distal humerus fractures treated with ORIF. Kocher et al (6) had 25% fair and poor results in their retrospective review of 33 cases. Kerner et al (25) had 42% fair and poor results in their retrospective review of 45 patients. An older review by Helfet et al (26) reported less good results in 25% in a

compilation of 9 studies made from 1985 to 1990. For all these reasons, in the last two decades TEA has been indicated as a valid option of treatment in selected patients affected by complex fractures of the elbow region, and many authors showed satisfactory results in up to 90% of cases (11, 27, 28). In this study, the results of TEA done in a selected group of distal humerus fractures are encouraging and similar to previous reports (1, 5, 6, 8, 9, 18, 19). Authors experience between 2002 and 2014 with 20 patients showed that the use of a linked implant resulted in a painless elbow rate of 90%. The mean MEPS in the affected arm was similar to unaffected, as demonstrated by statistical analysis ( $p=0.529$ ). However, patients were satisfied, and 90% had excellent or good outcomes. Several variables may be responsible for the high success rate recorded, and authors consider patient and implant selection and postoperative management to be the key factors for



**Figure 2.** TEA of the right elbow positioned following C3-3 fracture. Radiographs 9 months after surgery with signs of implant mobilization (A and B) and clinical signs of infection (fistula) (C); surgical debridement (D, E and F); clinical evaluation 96 months after initial surgery with prosthetic exposure (G) (MEPS: 30; poor result)

good outcomes. The selection of the patients must be rigid. Elderly are expected to have better results than younger because the higher demands in the latter may cause aseptic loosening, bushing wear, or component and periprosthetic fractures (4, 27-29), which can be suspected in the presence of radiographic osteolysis or radiolucency lines, or both. Therefore, in accordance with the literature (1, 5, 6, 8, 9, 18, 19), authors recommend TEA in collaborative low-demanding subjects older than 65 years and contraindicate this surgery approach in those with a previous history of infection of the elbow. This study include only this type of samples and the results showed that worse outcomes were observed in older and less collaborative people. Furthermore, as well as concomitant cognitive impairment ( $p=0.041$ ), associated rheumatoid arthritis ( $p=0.025$ ) negatively influenced the results.

Since Cobb and Morrey (11) in 1997 introduced the concept of linked TEAs in fractures of the elbow region, different prosthesis models have been proposed (unlinked and hemi-arthroplasty) with uncertain results and limited follow-up (30-34). In elderly, conditions at the fracture site often require the use of a lax hinge-type implant, to overcome the bone loss and any potential ligament injuries (11). For these reasons authors consider the use of linked implants to be optimal because they guarantee higher stability. Even if no statistical differences were found between the patients treated with the Coonrad-Morrey implant and those treated with the Latitude implant, they also agree with the trend of many elbow surgeons which prefer newer designs that introduce the concepts of prosthetic modularity and convertibility which offer a wider possibility of combinations of prosthetic components (17, 35, 36).

Authors consider the postoperative care another important aspect for positive outcomes, which should preferably be managed by specialized hand and upper extremity therapists. The final aim of physiotherapy is to obtain, as demonstrated by Morrey et al (37), a functional elbow ROM for most activities of daily living that is characterized by a minimum of  $100^\circ$  of total arc of motion of extension and flexion (ROM,  $30^\circ$ - $130^\circ$ ) and a minimum of  $100^\circ$  of pronation and supination (ROM,  $50^\circ$ - $50^\circ$ ). In this series only 2 subjects showed a mean ROM  $< 100^\circ$ . The first case had a ROM of only

$40^\circ$  (fair result) and the second developed an ankylosis at  $90^\circ$  of flexion (poor result); in both postoperative care was not possible because of degenerative cognitive impairment. In this context, it is also important that therapist, at later stages of the recovery, educate the patient to safely use the treated elbow without overloading the prosthesis. This is especially true when the affected side is the dominant one, which unintentionally is more frequently used and stressed (4), even if in this report negative outcomes were not influenced by hand dominance ( $p=0.851$ ).

Furthermore, statistical analysis showed that results were not related to surgical approach performed ( $p=0.517$ ), but authors sustain that, as demonstrated for other joints (38), sparing approaches which preserve periarticular soft tissues as much as possible, can improve the immediate postoperative management (lower pain and faster rehabilitation) thus diminishing potential immediate and mid-term complications. We could not confirm these findings because follow-up only began after a minimum period of 2 years after surgery. Also, complications related to the surgical approach, such as extensor mechanism problems after posterior splitting access, were never observed.

Instead, the development of postoperative complications was related to poorer outcomes ( $p=0.045$ ). In the present series, complications were encountered in 7 patients (35%), but only for 1 implant revision was indicated. Complications incidence with TEA ranges in the literature between 10 and 37% (5, 39) and is higher than in hip and knee replacement, although the majority of these do not influence the final outcome (40). These findings are probably due to the fact that TEA is relatively aggressive and done in a smaller joint, which is covered by thin soft tissues. Amongst the various complications, infections remain the most frequent (up to 10% of cases according to Morrey) (22). In this study problems related to infections were observed in 3 cases but only one (the single poor result) developed a deep infection. Ulnar nerve impairment is another common complication encountered after TEA, even though the nerve is usually protected during the surgical procedure. Ulnar neurapraxia occurs after surgery in as many as 20% of the patients, with the rate of permanent damage ranging from 0% to 10% (41). Three patients in the current case series

reported a transitory ulnar nerve impairment, which resolved spontaneously.

Limitations of this study include the retrospective design without a control group and the small sample size which might underpower its validity. On the other hand, authors consider that its strength was the evaluation of subjects all operated by the same two experienced elbow surgeons and the long follow-up (60 months on average), thus rendering it a valid and reliable report. Based on the review of the literature, as reported by Ducrot (6), only 3 studies have compared TEA and internal fixation. In all cases the results were favourable with arthroplasty, since faster and better recovery was achieved. However, strength recovery was better after internal fixation. This limited number of comparative studies suggests that further research with bigger sample size and longer follow-up is needed.

## Conclusions

Since complication rates and number of revisions after ORIF are especially high among elderly, TEA must be considered a suitable alternative for these selected patients.

In particular, on the basis of the results obtained, the authors believe this procedure to be indicated for complex fractures of the distal humerus in collaborative patients with more than 65 years and low functional demands. The development of postoperative complications and associated diseases, such as rheumatoid arthritis and cognitive impairment, may adversely affect the outcomes.

## References

- Mansat P, Nouaille Degorce H, Bonneville N, Demez H, Fabre T; SOFCOT. Total elbow arthroplasty for acute distal humeral fractures in patients over 65 years old - results of a multicenter study in 87 patients. *Orthop Traumatol Surg Res* 2013 Nov; 99(7): 779-84.
- Robinson CM, Hill RM, Jacobs N, Dall G, Court-Brown CM. Adult distal humeral metaphyseal fractures: epidemiology and results of treatment. *J Orthop Trauma* 2003; 17: 38-47.
- Palvanen M, Kannus P, Niemi S, Parkkari J. Secular trends in distal humeral fractures of elderly women. Nationwide statistics in Finland between 1970 and 2007. *Bone* 2010; 46: 1355-8.
- Pogliacomì F, Aliani D, Cavaciocchi M, Corradi M, Ceccarelli F, Rotini R. Total elbow arthroplasty in distal humeral nonunion: clinical and radiographic evaluation after a minimum follow-up of three years. *J Shoulder Elbow Surg* 2015 Dec; 24(12): 1998-2007.
- Pogliacomì F, Galavotti C, Cavaciocchi M, Corradi M, Rotini R, Ceccarelli F. Total elbow arthroplasty following trauma: mid-term results. *Acta Biomed* 2013; 84(3): 212-8.
- Ducrot G, Ehlinger M, Adam P, Di Marco A, Clavert P, Bonnomet F. Complex fractures of the distal humerus in the elderly: is primary total elbow arthroplasty a valid treatment alternative? A series of 20 cases. *Orthop Traumatol Surg Res* 2013 Feb; 99(1): 10-20.
- Diederichs G, Issever AS, Greiner S, Linke B, Korner J. Three-dimensional distribution of trabecular bone density and cortical thickness in the distal humerus. *J Shoulder Elbow Surg* 2009; 18: 399-407.
- Ellwein A, Lill H, Voigt C, Wirtz P, Jensen G, Katthagen JC. Arthroplasty compared to internal fixation by locking plate osteosynthesis in comminuted fractures of the distal humerus. *Int Orthop* 2015 Apr; 39(4): 747-54.
- Sørensen BW, Brorson S, Olsen BS. Primary total elbow arthroplasty in complex fractures of the distal humerus. *World J Orthop* 2014 Jul 18; 5(3): 368-72.
- Morrey BF, Bryan RS, Dobyns JH, Linscheld RL. Total elbow arthroplasty. A five-year experience at the Mayo Clinic. *J Bone Joint Surg Am* 1981; 63: 1050-63.
- Cobb TK, Morrey BF. Total elbow replacement arthroplasty primary treatment for distal humerus fractures in elderly patients. *J Bone Joint Surg Am* 1997; 79: 826-32.
- Prasad N, Dent C. Outcome of total elbow replacement for distal humeral fractures in the elderly. A comparison of primary surgery and surgery after failed internal fixation or conservative treatment. *J Bone Joint Surg Br* 2008; 90: 343-8.
- Proust J, Oksman A, Charissoux JL, Mabit C, Arnaud JP. Results of internal fixation for intra-articular distal humerus fractures in elderly patients. *Rev Chir Orthop* 2007; 93: 798-806.
- Neer 2nd CS. Displaced proximal humeral fractures. II. Treatment of three-part and four-part displacement. *J Bone Joint Surg Am* 1970; 52: 1090-103.
- D'Arcy J, Devas M. Treatment of fractures of the femoral neck by replacement with the Thompson prosthesis. *J Bone Joint Surg Br* 1976; 58: 279-86.
- Frihagen F, Nordsletten L, Madsen JE. Hemiarthroplasty or internal fixation for intracapsular displaced femoral neck fractures: randomised controlled trial. *Br Med J* 2007; 335: 1251-4.
- Corradi M, Frattini M, Panno B, Tocco S, Pogliacomì F. Linked semi-constrained total elbow prosthesis in chronic arthritis: results of 18 cases. *Musculoskelet Surg* 2010 May; 94 Suppl 1: S11-23.
- Chalidis B, Dimitriou C, Papadopoulos P, Petsatodis G, Giannoudis PV. Total elbow arthroplasty for the treatment of



- insufficient distal humeral fractures. A retrospective clinical study and review of the literature. *Injury* 2009; 40: 582-90.
19. McKee MD, Veillette CJ, Hall JA, Schemitsch EH, Wild LM, McCormack R, Percy B, Goetz T, Zomar M, Moon K, Mandel S, Petit S, Guy P, Leung I. A multicenter, prospective, randomized, controlled trial of open reduction – internal fixation versus total elbow arthroplasty for displaced intraarticular distal humeral fractures in elderly patients. *J Shoulder Elbow Surg* 2009; 18: 3-12.
  20. Muller ME, Nazarian S, Koch P, Schatzker J. The comprehensive classification of fractures of long bones. Berlin: Springer; 1994.
  21. Morrey BF, An KN, Chao EY. Functional evaluation of the elbow. In: Morrey BF (ed) *The elbow and its disorders*, 2<sup>nd</sup> edn. WB Saunders, Philadelphia.
  22. Morrey BF, Bryan RS, Dobyns JH, Linscheid RL. Total elbow arthroplasty. A five-year experience at the Mayo Clinic. *J Bone Joint Surg Am* 1981; 63: 1050-63.
  23. Mann HB, Whitney DR. On a test of whether one of two random variables is stochastically larger than the other. *Ann Math Stat* 1947; 18: 50-60.
  24. John H, Rosso R, Neff U, Bodoky A, Regazzoni P, Harder F. Distal humerus fractures in patients over 75 years of age. Long-term results of osteosynthesis. *Helv Chir Acta* 1993; 60: 219-224.
  25. Kocher M, Melcher GA, Leutenegger A, Rüedi T. Elbow fractures in elderly patients. *Swiss Surg* 1997; 3: 167-171.
  26. Helfet DL, Schmeling GJ. Bicondylar intraarticular fractures of the distal humerus in adults. *Clin Orthop Relat Res* 1993; (292): 26-36.
  27. Linn MS, Gardner MJ, McAndrew CM, Gallagher B, Ricci WM. Is primary total elbow arthroplasty safe for the treatment of open intraarticular distal humerus fractures? *Injury* 2014; 45: 1747-51.
  28. Mansat P, Bonnevalle N, Rongieres M, Bonnevalle P. The role of total elbow arthroplasty in traumatology. *Orthop Traumatol Surg Res* 2014; 100 (6 Suppl): S293-8.
  29. Mansat P, Bonnevalle N, Rongieres M, Mansat M, Bonnevalle P. Experience with the Coonrad-Morrey total elbow arthroplasty: 78 consecutive total elbow arthroplasties reviewed with an average 5 years of follow-up. *J Shoulder Elbow Surg* 2013; 22: 1461-8.
  30. Ikävalko M, Letho MUK. Fractured rheumatoid elbow: treatment with Souter elbow arthroplasty. A clinical and radiologic midterm follow-up study. *J Shoulder Elbow Surg* 2001; 10: 256-9.
  31. Kalogrianitis S, Sinopidis C, El Meligy M, et al. Unlinked elbow arthroplasty as primary treatment for fractures of the distal humerus. *J Shoulder Elbow Surg* 2008; 17: 287-92.
  32. Parsons M, O'Brien JR, Hughes JS. Elbow hemiarthroplasty for acute and salvage reconstruction of intra-articular distal humerus fractures. *Tech Shoulder Elbow Surg* 2005; 6(2): 87-97.
  33. Adolfsson L, Hammer R. Elbow hemiarthroplasty for acute reconstruction of intra-articular distal humeral fractures. A preliminary report involving 4 patients. *Acta Orthop* 2006; 77: 785-7.
  34. Hughes J. Fracture of the distal humerus: distal humeral hemiarthroplasty. In: Stanley D, Trail IA, editors. *Operative elbow surgery*. Churchill Livingstone, Edinburgh, London, New York, Oxford, Philadelphia, St Louis, Sydney, Toronto: Elsevier; 2012 [Chapter 18].
  35. Giannicola G, Scacchi M, Polimanti D, Cinotti G. Discovery elbow system: 2- to 5-year results in distal humerus fractures and posttraumatic conditions: a prospective study on 24 patients. *J Hand Surg Am* 2014; 39: 1746-56.
  36. Gramstad GD, King GJ, O'Driscoll SW, Yamaguchi K. Elbow arthroplasty using a convertible implant. *Tech Hand Up Extrem Surg* 2005; 9: 153-63.
  37. Morrey BF, Askew LJ, Chao EY. A biomechanical study of normal functional elbow motion. *J Bone Joint Surg Am* 1981; 63: 872-7.
  38. Pogliacomi F, Paraskevopoulos A., Costantino C., Marengi P., Ceccarelli F. Influence of surgical experience in the learning curve of a new approach in hip replacement: anterior mini-invasive vs standard lateral. *Hip International* 2012; 22(5): 555-61.
  39. Aldridge JM 3rd, Lightdate NR, Mallon WJ, Coonrad RW. Total elbow arthroplasty with the Coonrad/Coonrad-Morrey prosthesis. A 10- to 31-years survival analysis. *J Bone Joint Surg Br* 2006; 88(4): 509-14.
  40. Yamaguchi K, Adams RA, Morrey BF. Semiconstrained total elbow arthroplasty in the context of treated previous infection. *J Shoulder Elbow Surg* 1999; 8: 461-65.
  41. Shi LL, Zurakowski D, Jones DG, Koris MJ, Thornhill TS. Semiconstrained primary and revision total elbow arthroplasty with use of Coonrad-Morrey prosthesis. *J Bone Joint Surg Am* 2007; 89(7): 1467-75.

---

Received: 10 Aprile 2016

Accepted: 17 July 2016

Correspondence:

Francesco Pogliacomi, MD

Orthopaedics and Traumatology Clinic

Department of Surgical Sciences, University of Parma

Via Gramsci 14, 43126 Parma (Italy)

Tel. 00390521702850

Fax 00390521290439

E-mail: fpogliacomi@yahoo.com