

Reduction mammoplasty techniques in post-bariatric patients: our experience

Susanna Polotto¹, Michele Grieco¹, Francesco Simonacci¹, Nicolò Bertozzi¹, Federico Marchesi², Eugenio Grignaffini¹, Edoardo Raposio¹

¹Department of Surgical Sciences, Plastic Surgery Division, University of Parma and Cutaneous, Regenerative, Minimally Invasive and Plastic Surgery Unit, Parma University Hospital, Parma, Italy; ²Department of Surgical Sciences, Section of General Surgical Clinics and Surgical Therapy, Parma University Medical School, Parma, Italy

Summary. *Background and aim of the work:* Excessive body weight represents a huge problem affecting a wide part of world population, causing significant physical and psychological consequences. To solve their obesity-related problems, patients should begin a bariatric treatment to lose an adequate percentage of their body mass and therefore, they should be subjected to body contouring surgery. In this article we describe our experience in applying breast remodeling techniques to post-bariatric patients. *Methods:* We did a retrospective study on our post-bariatric patients subjected to breast reduction and/or mastopexy during a five-years period, considering breast features, kind of surgery performed, aesthetic and psychological outcomes and postoperative complications. *Results:* Thirty-six post-bariatric patients underwent breast surgery in our unit between 2010 and 2015; their average age was 43 years. The follow up period ranged from 6 months to 4 years and an half. The most frequent surgical techniques performed were Thorek and inferior pedicle breast reduction. The prevalent complications observed were surgical wound delayed healing and nipple-areolar complex (NAC) partial or complete necrosis as immediate ones and unfavorable scarring as delayed ones. *Conclusions:* Breast reshaping after a massive loss of weight should be fore-run by an accurate analysis of breast volume, shape and ptosis degree, in order to obtain optimal results both for the surgeon and the patient. (www.actabiomedica.it)

Key words: breast reshaping, post-bariatric surgery, breast reduction

1. Introduction

Millions of people are affected by obesity and this condition involves both pathological and psychological problems. Excessive body weight is also related to many pathologies, such as hypertension, heart failure, diabetes and other diseases (1), not mentioning the psychological problems related to this condition. To improve the quality of their life the patients go to a dietician or to a bariatric surgeon to start a massive weight loss process. Then, they have to deal with a consistent skin excess, especially in arms, breast, abdomen and thigh regions and so they turn to a plastic surgeon to undergo body contouring techniques. After

a massive weight loss, many patients complain about an excess of anelastic in various body regions. In breast area, female patients report also reduced volume, ptosis, lateral excess of tissue, variation in NAC position, emptying in upper breast quarters (2).

We did a retrospective analysis of breast reshaping techniques applied during a five-year period in our unit. First of all, we did an accurate evaluation of breast deformities after a massive loss of weight and then, using the Pittsburgh rating scale (Tab. 1), we chose the appropriate surgical technique. Finally, we valued the aesthetic and functional outcomes and the complications occurred.

Table 1. The Pittsburgh rating scale in post-bariatric patients: the breast area

Grade	Scale	Preferred procedure
0	Normal	None
1	Ptosis grade I/II or severe macromastia	Traditional mastopexy, reduction, or augmentation techniques
2	Ptosis grade III or moderate volume loss or constricted breast	Traditional mastopexy and/or augmentation techniques
3	Severe lateral roll and/or severe volume loss with loose skin	Parenchymal reshaping techniques with dermal suspension, consider auto-augmentation

2. Materials and Methods

Between January 2010 and June 2015 36 post-bariatric female patients underwent breast reshaping at the Cutaneous, Regenerative, Minimally Invasive and Plastic Surgery Unit, Plastic Surgery Section, Department of Surgical Sciences, University of Parma, Italy. We performed the surgery after a sensible weight loss, due to an adequate diet therapy or bariatric surgery, stable for at least 6 months. We recommended the patients to stop smoking or to reduce significantly cigarette number and to avoid oral contraception for at least one month before surgery. The surgery was performed under general anesthesia and the patient is usually dismissed after three days after surgery; one drain in aspiration is positioned in each breast and removed when the serum collected is under 50 cc/24 h (usually after 48 h), in order to avoid seroma and hematoma development. For every patient we considered the residual breast hypertrophy and/or ptosis degree, to choose the appropriate surgery (Tab. 1). We give the patient the informed consent adequate for the chosen surgical technique and accurately explain its possible complications. In particular, NAC partial or total necrosis (more frequent in Thorek technique), NAC loss of sensibility, scar hypertrophy, breast and/or NAC asymmetry and loss of breastfeeding capacity. It is also important to describe accurately scar running (periareolar, vertical and/or horizontal scar) and the possibility of detaching the NAC as a full-thickness skin graft, with all the side effects involved. We do standard blood exams, electrocardiogram and, when the patients are over 40 years, thorax X-Ray exam. In appraised ≥ 500 g breast volume to remove, we alert

the transfusional center to make available two blood sacs, in order to avoid postoperative anemia. Then, we did preoperative skin drawing in standing position to assess NAC new position and the extent of cutaneous excision, thus establishing the final scar. Intraoperatively, the patient is positioned supine, with their arms alongside the body, to avoid distortion caused by arms positioned at a 90 degree angle with the trunk. A short-term antibiotic therapy with semisynthetic penicillin was administered routinely (before surgical skin incision, 8 and 12 hours later and then three times a-day for ten days after surgery).

There are many different surgical techniques (3-12) to deal with breast deformities in post-bariatric patients. We performed four kind of surgery: superior pedicle with auto-augmentation (3 patients) (Fig. 1-2), inferior pedicle (15 patients) (Fig. 5-6), medial pedicle (3 patients) and Thorek technique (15 patients) (Fig. 3-4), depending on shape, volume and ptosis of the breasts. 30 patients had hypertrophic and III degree ptotic breasts, so that we decided to perform inferior pedicle technique for women aged ≤ 40 years or who asked for NAC sensibility and function preservation (15 patients) and to perform Thorek technique when the distance between NAC and hemiclavear point were $>38-40$ cm and when the estimated excess of tissue to remove were >1000 g, that is when the NAC pedicle would be too long to assure blood supply to the NAC (15 patients). Three patients needed breast reshaping with skin excess excision and breast volume restoration with their own tissue, so we performed superior pedicle technique with auto-augmentation whereas for three patients medial pedicle technique assured an optimal volume redistribution.

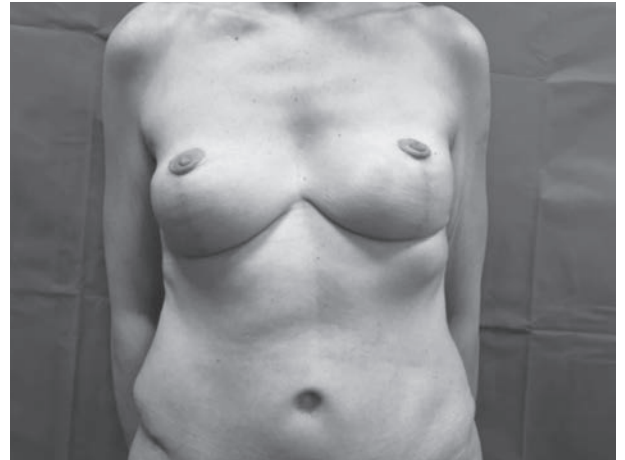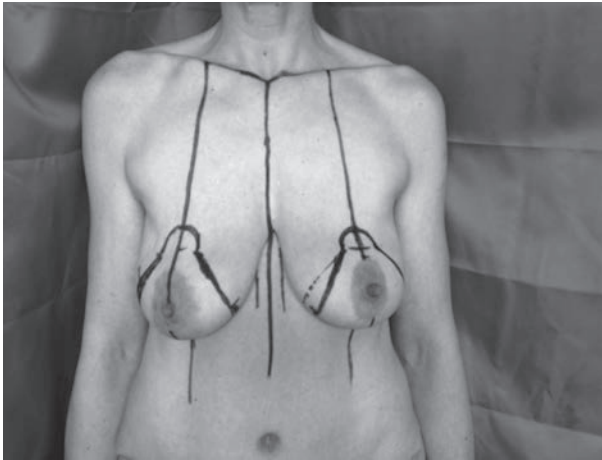


Figure 1-2. Patient with II degree ptosis: pre-operative and 12 months post-operative photos, after a superior pedicle with auto-augmentation technique

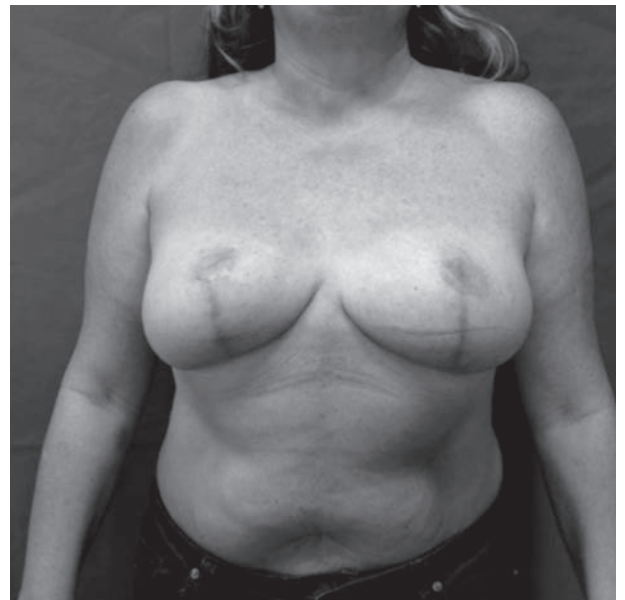
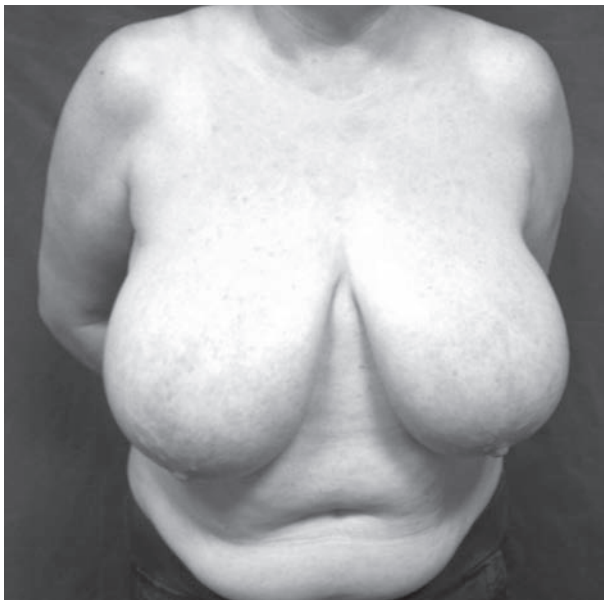
Figure 3-4. Patient with III degree ptosis: pre-operative and 12 months post-operative photos, after an inferior pedicle technique

3. Results

During the last five years we performed 36 breast reshaping in female patients after a huge weight loss. The follow-up period ranged from a minimum of 6 months to a maximum of 5 years (average: 32.3 months). Average weight of our patients before surgery was 78,9 kg (range: 63 to 120 kg) and their weight loss was comprised between 25 and 46 kg (average

weight lost: 31 kg), 27 patients (75%) after bariatric surgery and 9 patients (25%) after diet therapy). The patients were aged between 35 and 44 years (mean age: 37 years).

In our experience, according to the Pittsburgh Rating Scale, the more represented ptosis were second (30 patients) and third grade (10 patients); the preferred surgical techniques used were inferior pedicle mastopexis and Thorek technique (30 patients each),

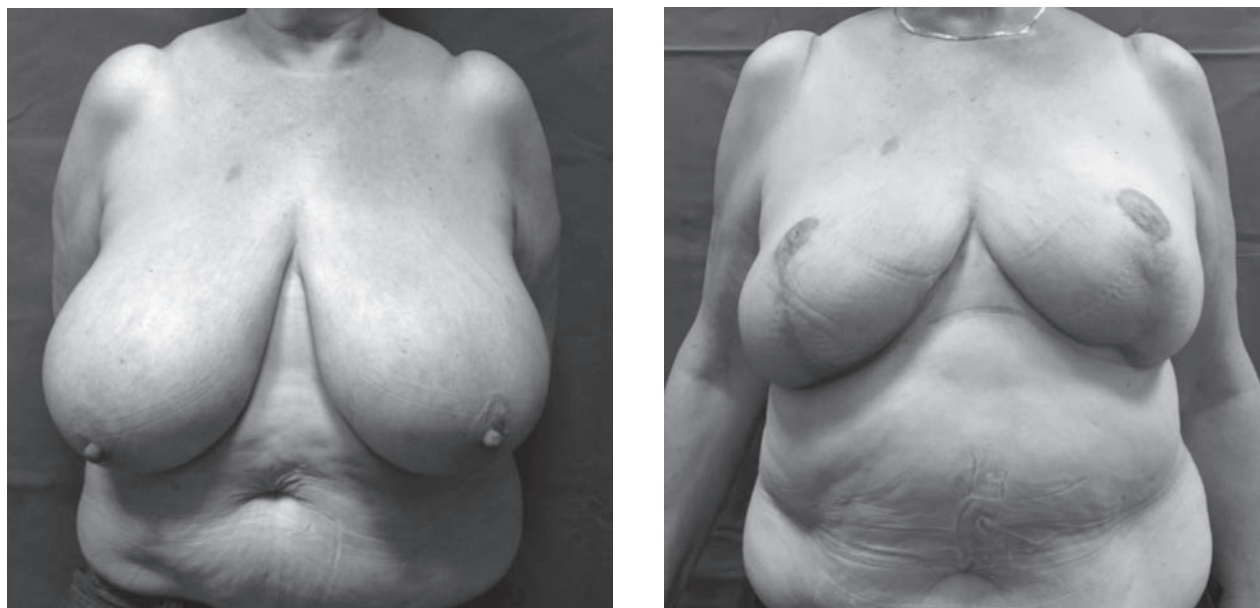

Figure 5-6. Patient with III degree ptosis: pre-operative and 12 months post-operative photos, after a Thorek technique

and the mean surgical time has been 3:15 h (range from 1:45 to 4:30 h) (Tab. 2). All the patients underwent breast reshaping after almost six months since the stabilization of their weight. We observed minor complications and none major ones, not affecting negatively on patients' satisfaction; in particular: delayed wound healing (19,44%), unfavorable scarring (13,89%), seroma (2,78%), hematoma (2,78%), skin necrosis (5,55%), partial nipple loss (5,55%) and total nipple loss (2,78%) (Tab. 3).

4. Discussion and conclusion

Post-bariatric patients more and more often ask for breast reshaping; this kind of surgery is demanding

due to the high anatomical variability of this typology of patients and to their expectations. For this reason, every operation should be forerun by an accurate surgical planning, considering breast volume, shape and ptosis degree, in order to choose the most appropriate surgical technique. It is important to consider that most patients well tolerate conspicuous and sometimes imperfect scars in return for breast volume reduction and ptosis correction, obtaining in this way relief from spine pain, intertrigo and other related problems (10). Clear explaining all the probable side effects of the surgery to the patients, especially regarding the frequent dehiscence of surgical wound at the junction between the vertical and the horizontal arm of the "inverted T" scar, which lead to a second intention closure of the wound, the possibility of NAC partial or complete

Table 2. Characteristics of the patients and surgical techniques

Surgical technique	Superior pedicle with auto-augmentation	Inferior pedicle	Medial pedicle	Thorek
Total tissue resected	1303 g (1020-1630)	2320 g (1970-3100)	1307 g (1150-1500)	2513 g (2100-4250)
Age	34,7 years (33-36)	37,3 years (32-44)	40 years (39-41)	45,9 years (37-49)
Ptosis degree	II	III	II	III
Number of patients	3	15	3	15

Table 3. Major and minor complications after breast reshaping in 36 patients

Major complications	Minor complications
Thromboembolic event 0 (0%)	Wound/dehiscence/ Delayed wound healing 7 (19,44%)
Wound infection 0 (0%)	Unfavorable scarring 5 (13,89%)
Abscess 0 (0%)	Seroma 1 (2,78%)
Bleeding 0 (0%)	Hematoma 1 (2,78%)
Infected seroma 0 (0%)	Partial nipple loss 2 (5,55%)
	Skin necrosis 2 (5,55%)

necrosis and the significant breast volume reduction which is necessary in most of the patients. However, a careful preoperative anamnesis of the patient's lifestyle (smoking, alcohol, and drugs addiction), when associated to surgical practice can help preventing the above mentioned side effects. We preferred Thorek and inferior pedicle techniques, because of the occasion of performing significant cutaneous and glandular reduction, required by 90% of our patients, also in the lateral chest wall rolls region. After surgery, avoiding thromboembolic events and infections is mandatory. Therefore, low molecular weight heparin and antibiotics administration for 10 days in the postoperative period and early mobilization of the patients is usually performed in our practice. Finally, we recommend the patients to wear compression bra for two months postoperatively 24 hours/day, as it helps breasts to get settled; the final result can be seen six months postoperatively, after edema resorption and scar maturation.

References

1. Pavan C, Azzi MF, Lancerotto L, et al. Overweight/obese patients referring to plastic surgery: temperament and personality traits. *Obes Surg* 2013; 23: 437-45.
2. Coriddi M, Koltz F, Gusenogg JA. Reduction mammoplasty, obesity, and massive weight loss: temporal relationships of satisfaction with breast contour. *Plast Reconstr Surg* 2011; 128: 643-50.
3. Losken A. Breast reshaping following massive weight loss: principles and techniques. *Plast Reconstr Surg* 2010; 126(3): 1075-85.
4. Akyurek M. Vertical mastopexy and lateral intercostal artery perforator (LICAP) flap with pectoralis muscle sling for autologous tissue breast augmentation in the bariatric patient. *Ann Plast Surg* 2011; 66(1): 29-35.
5. Hurwitz DJ, Agha-Mohammadi S. Post bariatric breast reshaping: the spiral flap. *Ann Plast Surg* 2006; 56(5): 481-6. discussion 486.
6. Spear SL, Davison SP. Breast augmentation with periareolar mastopexy. *Oper Tech Plast Reconstr Surg* 2000; 7(3): 131-6.
7. Okada A, Lopes Saito F, Hiraki PY, et al. Mastopexy after massive weight loss: dermal suspension, parenchymal reshaping and augmentation with autologous tissue. *Rev Bras Cir Plast* 2012; 27(2): 283-9.
8. Colwell AS, Driscoll D, Breuing KH. Mastopexy techniques after massive weight loss: an algorithmic approach and review of the literature. *Ann Plast Surg* 2009; 63(1): 28-33.
9. Akyurek M. Short scar reduction mammoplasty in the bariatric patient. *Ann Plast Surg* 2011; 66(6): 602-6.
10. Thornton DJ, Fourie LR. Autologous augmentation-mastopexy after bariatric surgery: waste not want not! *Aesthet Plast Surg* 2010; 34(4): 519-24.
11. Hofmann AK, Wuestner-Hofmann MC, Bassetto F, et al. Breast reduction: modified BLEjour technique in 500 large breasts. *Plast Reconstr Surg* 2007; 120(5): 1095-104. discussion 1105-7.
12. Migliori FC, Gabrielli A, Rizzo R, et al. Breast contouring in postbariatric patients: a technique selection algorithm. *Obes Surg* 2010; 20(5): 651-6.

Received: 28 December 2015

Accepted: 7 March 2016

Correspondence:

Susanna Polotto, MD

Department of Surgical Sciences, Plastic Surgery Division,

University of Parma. Cutaneous, Regenerative,

Minimally Invasive and Plastic Surgery Unit,

Parma University Hospital,

Via Gramsci 14, 43126 Parma, Italy

E-mail: polotto.susanna@gmail.com