

Post-bariatric body contouring: our experience

Michele P. Grieco¹, Eugenio Grignaffini¹, Francesco Simonacci¹, Donatello Di Mascio², Edoardo Raposio¹

¹Department of Surgical Sciences, Plastic Surgery Chair, University of Parma, and the Cutaneous, Regenerative, Mininvasive and Plastic Surgery Unit, Parma University Hospital, Parma, Italy; ²Unit of Plastic Surgery and Burns Center, Parma University Hospital, Parma, Italy

Summary. Obesity is a growing socio-economic problem especially in the western population. Patients who are undergoing bariatric surgery after a significant weight loss have an altered body profile which may have an important psychological impact. These patients may be candidates for surgical body-lifting. The aim of body-lifting is to obtain a firmer, tighter, rejuvenated appearance for patients who have lax, ptotic tissues. In this paper we describe our experience with two techniques currently practiced by our team, brachioplasty and thigh lift, reporting the indications, the surgical technique and possible complications. (www.actabiomedica.it)

Key words: body-lifting, obesity, post-bariatric surgery

Introduction

Obesity presents a major health concern and has significant economic implications for our medical system. In the United States, nearly one-third of the adult population is obese, having a body mass index (BMI) of 30 kg/m² or greater (1). A constellation of medical problems known as metabolic syndrome is associated with morbid obesity, including hypertension, dyslipidaemia, type 2 diabetes, coronary artery disease, stroke, gallbladder disease, osteoarthritis, obstructive sleep apnoea, and cancers such as breast and colon (2). The rapidly increasing prevalence of obesity has seen an increase in the use of bariatric surgery (3). Multiple surgical techniques have been described to treat obesity. The two major categories of bariatric surgery include restrictive operations and malabsorptive operations. Restrictive operations rely on vertical banded gastroplasty, adjustable gastric band, and gastric bypass. Malabsorptive operations include biliopancreatic diversion, duodenal switch, and distal gastric bypass (4). Currently, gastric bypass is the most common form of bariatric surgery performed. Bariatric surgery (BS) is

the only effective therapy to achieve successful maintenance of weight loss in morbidly obese patients (5); the massive weight loss (MWL) obtained after BS is often associated with health benefits. After MWL these patients present a different profile and are ideal candidates to surgical body-contouring techniques. Indeed, body contouring surgery has become a steadily increasing part of weight loss treatment in the population of patients electing to undergo bariatric surgery (6). Body lifting is often considered a high-risk surgical procedure (7). This procedure includes brachioplasty, upper back lift, abdominoplasty, lower back lift, and thigh lift (2). The aim of body lifting is to create a firmer, tighter, rejuvenated appearance for patients who have lax, ptotic tissues. In the present paper, the authors describe their experience in body-contouring surgical procedures, especially in brachioplasty and thigh lift.

Our surgical techniques

In this study, we concentrated only on the two procedures most commonly performed (apart from abdominoplasty) by our team: brachioplasty and

thigh-lift. Brachioplasty is performed for skin laxity in the arm (that may extend to the chest wall), not for lipodystrophy. Brachioplasty involves incisions along the length of the upper arm, prolonged within the axilla (8-9). Markings are performed with the arm elevated at 90 degrees and are guided by pinch test. A deep incision, directly towards the muscular fascia, is performed. An antero-posterior undermining is gently performed with scalpel, following the superficial muscular-fascial plane, for almost half circumference of the arm. Great attention must be paid as undermining passes above bicipital groove because it is easy to deepen the incision and get behind triceps muscle: in that case, ulnar nerve and brachial artery could be exposed and damaged. As the undermining is completed, an over corrective tension is applied to anterior edge of incision and to the undermined flap. The flap is overlapped to the incisional edges, the projection of which is marked with 3-4 transfixed needles, and completed with a straight line joining the incision tip. In this way, we obtain an excised tissue extension always rather abundant: only perforating vessels and nerves feeding this area are severed. Then, the correct amount of skin may be resected. Suture is performed under tension, on three planes (subcutaneous, subdermal and intradermal plane); suction drains are placed and maintained 1-2 days postoperatively (Fig. 1).

Thighplasty for the resection of excess skin and subcutaneous tissue in the internal facet of the thigh was firstly described by Lewis (10), with cutaneous resections in the vertical and horizontal planes. The extended thigh lift procedure we perform addresses skin excess of the thigh extending from pubis to knee that cannot be treated with a proximal procedure alone (11). In this procedure, the patient is marked first in standing position then in a supine position, with flexed thighs and abducted knees and confirmed with the patient in horizontal dorsal decubitus. The horizontal line is marked from the inguinal crease in the direction of the gluteus groove, while the final vertical line is marked in the median portion of the internal face of the thigh from the inguinal region to the internal facet of the knee. The resection limits of the spindles are determined by pinch test. The lower limbs are placed in a flexed and abducted position. Resection of skin and subcutaneous tissue, previously determined by

markings, is performed. The depth of excision should be just below Scarpa's fascia but above the level of the saphenous vein. Then, the planned amount of skin and subcutaneous tissue may be resected. Suture is performed under tension, on three planes (subcutaneous, subdermal and intradermal); suction drains are placed and maintained 1-2 days postoperatively. For all patients, antibiotic therapy is administered in the immediate pre-operative period, and continued for 5 days. Postoperative care includes 10 days of treatment with low molecular weight heparin to prevent major complications such as deep vein thrombosis and pulmonary embolism. Social activity is limited for 4 weeks after the discharge (Fig. 2).

Results

From January 2012 to December 2014, 8 patients (6 women and 2 men) aged between 27 years and 71 years (mean age: 52 years) undergone post-bariatric surgery: 4 patients (50%) performed a brachioplasty (2 women and 2 man), while 4 patients (50%) performed a medial thigh-lift (3 women and 1 man). All patients reported a weight loss between 12 kg and 45 kg (average weight lost: 29 kg), obtained by previous bariatric surgery (5 Pt, 3F and 2M) or following a specific diet regimen (3 Pt, 2F and 1M). Five patients were non-smokers and 3 were smokers.

All procedures were performed on general anesthesia. A single-shot second-generation cephalosporin was administered routinely. The operating time ranged from 2.25 hours to 3.45 hours, with a mean of 2,8 hours. The average weight of tissue removed in total was 690 grams; in details, for the brachioplasty it was 460 grams (range: 350 to 650 grams), while for medial thigh lift it was 925 grams (range: 600 to 1500 grams). Routinely, two or four suction drains were placed. Postoperatively, the drains were removed when fluid collection <30 ml/24 h, and an arm or leg binders was used for 4 weeks. Average hospital stay, including the day of surgery, was 3.5 days with a range of 3 to 6 days postoperatively. For all patients, antibiotic therapy was also administered in the immediate pre-operative and it was continued for 5 days. Postoperative care included 10 days of treatment with low mo-

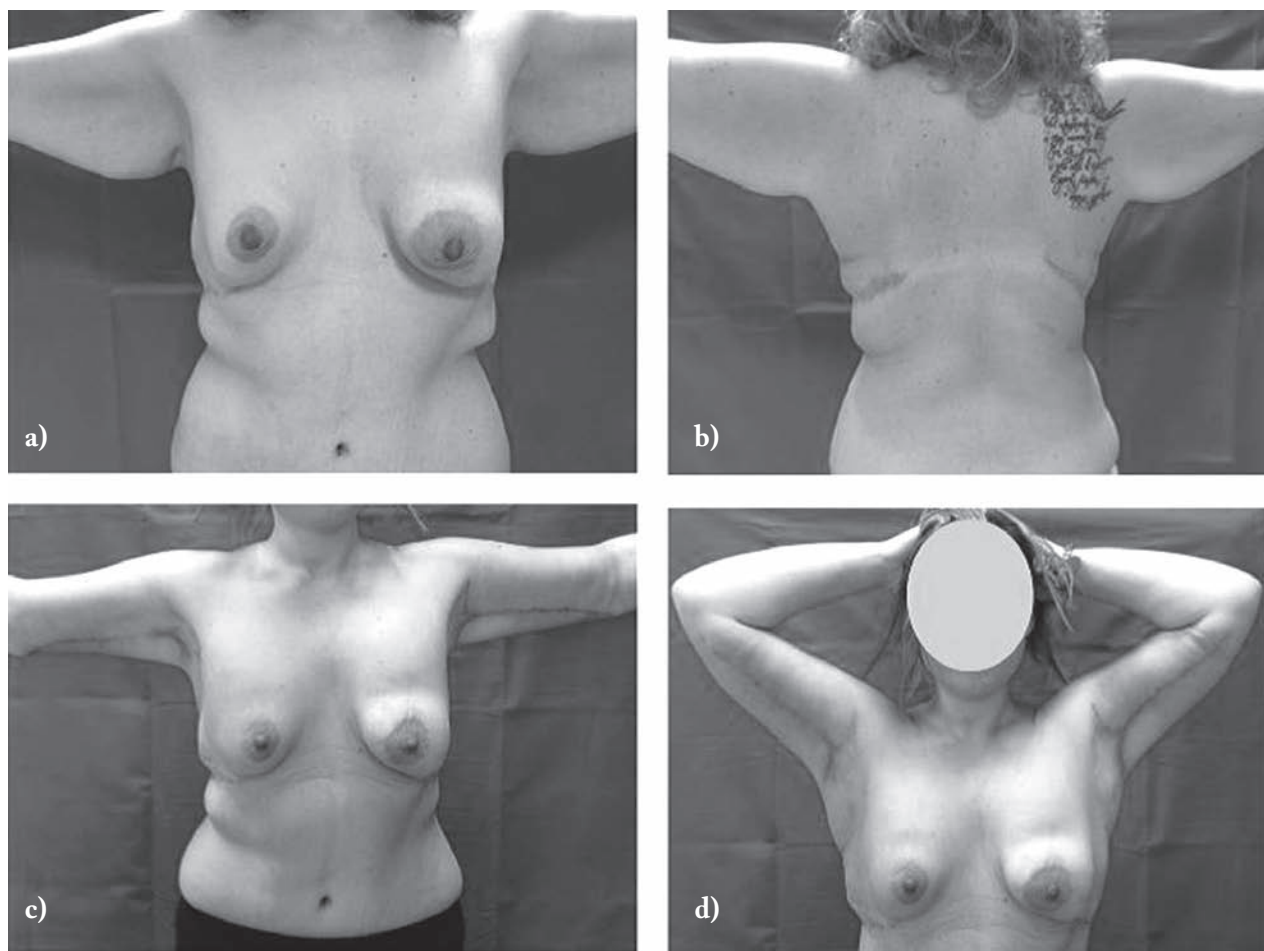


Figure 1. a-b) Preop, 28 year old female patient, former obese, previous gastric banding, abdominoplasty and lifting of the axillary pillars; c-d) Three-month postop, wounds completely healed

lecular weight heparin to prevent major complications such as deep vein thrombosis and pulmonary embolism. Social activity was limited for 4 weeks after the discharge. Five of 8 (62%) patients had no complications. One patient (12,5%) developed a palpable seroma after tight lift, which required aspiration during a follow-up visit. In one case (12,5%) of medial thigh lift we observed a minor wound dehiscence (4 cm), while in one case (12,5%) after brachioplasty we observed an hematoma. No major complication was observed. Surgical outcomes were documented by comparing pre and post-operative photos (see Figs 1-2) which were taken between three months and one year after the surgery.

Discussion

Obesity is a complex disease that is managed by internists, endocrinologists, nutritionists, psychiatrists, bariatric surgeons, plastic surgeons, and other professionals (12). Body mass index (BMI), a ratio of weight to height, is the most common method used for determining a patient's weight status. The clinical definition of obesity is a BMI of 30 or more. A BMI of 30-35 is classified as obese, of 35-40 defines severe obesity, of 40-50 defines morbid obesity, and of 50 or more defines "super obesity." Greater health risks are associated with higher BMI (13). The use of bariatric surgery in the treatment of obesity has become in-

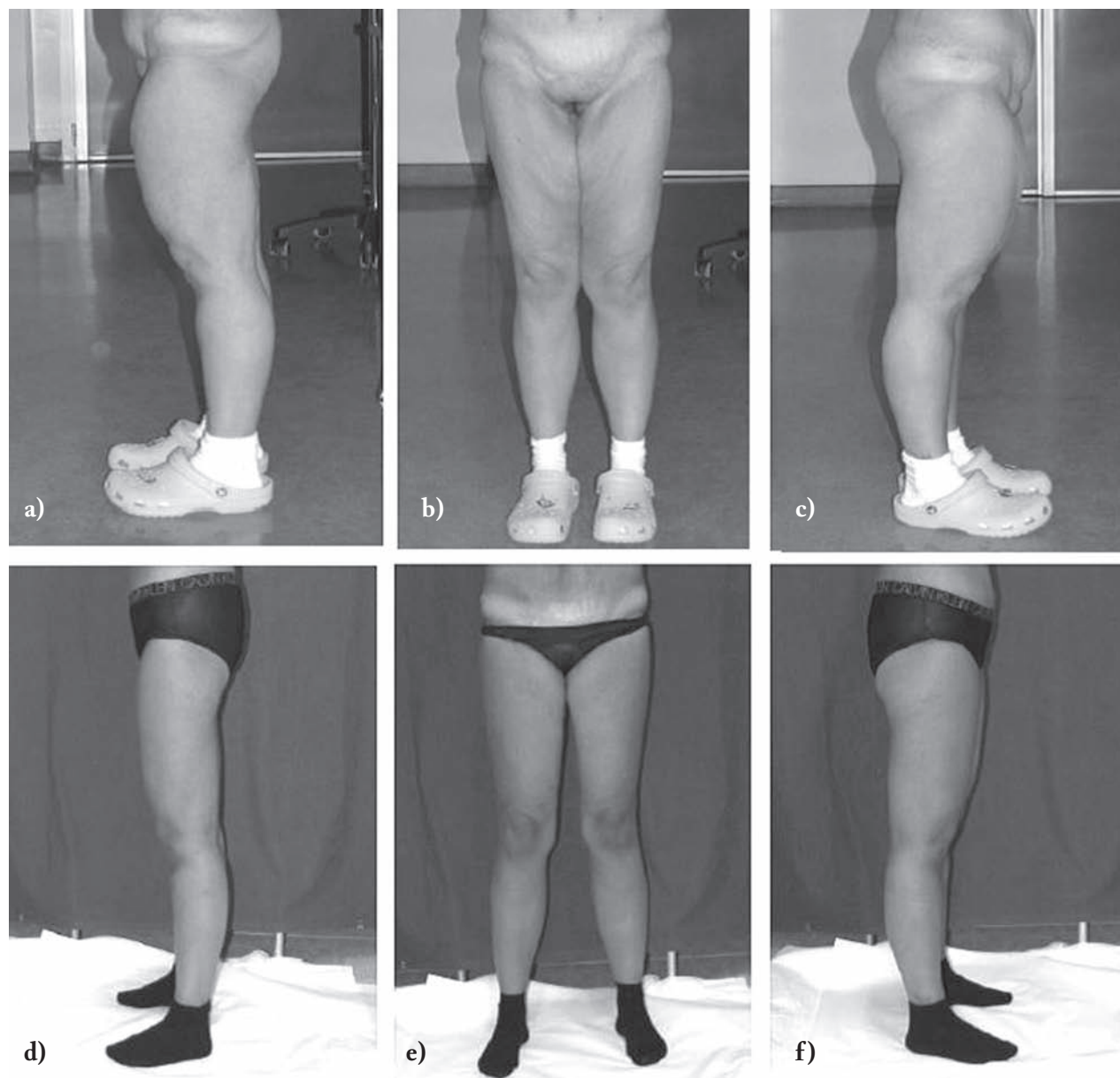


Figure 2. a-b-c) Preop, 48 year-old female patient, former obese, previous massive weight lost with diet and thigh liposuction. d-e-f) Postop, one-year follow-up after vertical-medial thigh lift

creasingly common. Bariatric surgery is indicated for patients with a BMI that exceeds 40 kg/m^2 or for patients with a BMI greater than 35 kg/m^2 who also have serious associated health problems (14). After MWL many patients require adjustment of the redundant skin laxity that is often seen after a dramatic weight loss; their deformities are typically more severe with greater excess skin and a greater degree of laxity when

bigger is the global weight loss. The surgical procedure to correct these problems is called “body contouring surgery” (15). Ideally, body contouring surgery in the post-bariatric surgery patients should only be performed after the patients’ weights are stable, and that could take around 18 months after bariatric surgery. In many MWL patients, abdominal contouring alone is insufficient. Many MWL patients with severe skin

ptosis require more extensive procedures. A number of procedures address these deformities, including belt lipectomy (16), bodylift (17), circumferential torso-plasty (18), medial thigh-lift (19), and brachioplasty (20). In our experience, the majority of patients who were candidates for brachioplasty and thighplasty were formerly obese who had lost at least 40 kg in the preceding 18 months from bariatric surgery or through strict diet-therapy. These patients were followed by dietitians to reach a stable and constant weight to allow a good surgical outcome. The brachioplasty is not a simple technique, requiring a long learning curve, but it confers natural arm shape and profile, reproducing the inferior concavity proximal to the elbow. The brachioplasty procedure must be carefully designed beforehand. It is important to set the midpoint of the medial epicondyle of the elbow and the axillary crease; respect of medial brachial cutaneous sensitive nerve allows good preservation of sensibility within the medial arm aspect (15,21-23). When the patient is standing still, we can adequately plan the incisions in order to minimize the scars seen from the anterior or posterior direction. Anyhow, if the cutaneous laxity is conspicuous, it is often necessary to extend the scars to the lateral chest and breasts ("extended brachioplasty") (24-26). Adjunct liposuction may be used. Generally, the outcome of brachioplasty is good. Linear scars are long, not of high quality, but well hidden within the medial bicipital groove and not visible in the frontal view as well as in the posterior view (27). The thighs are a difficult area to treat in the MWL patient. No single procedure can address changes in both the medial and lateral thighs. Again, adjunct liposuction may be used. The thigh must be conceptually divided into lateral and medial areas. Conversely, a medial thigh-lift will only affect medial tissues, leaving the lateral tissues primarily unaffected. The aim of a vertical medial thigh-lift is to primarily correct horizontal laxity with the resection of a vertical component, focusing tension on the medial thigh as a cylinder (28). A lower body lift (LBL) can outline the lateral thighs, but leave the medial thighs minimally affected; while a medial-vertical thigh-lift leaves the lateral side of the thigh intact. A lower body-lift (LBL) may contour the lateral thighs, but leave the medial thighs minimally affected, while a vertical medial thigh-lift may tighten the in-

ner thigh, leaving the lateral thigh untouched. Due to complications (e.g., scar widening, vulvar deformity, and recurrence of ptosis), a modification of the upper medial thigh-lift, anchoring the inner thigh to Colles' fascia, has been proposed (29). Advantages of this procedure include avoiding a medial longitudinal scar, the ability to perform it in conjunction with a lower body-lift, and decreased recovery and operative time as compared with a vertical thigh-lift. However, laxity of the distal third of the medial thigh is minimally improved with this procedure. Depending on the distal extent of skin laxity, the scar may be shortened, or lengthened towards the medial knee (30).

Any body-contouring surgery should be performed under general anaesthesia. This increases the rate of complications, especially thrombotic complications such as deep venous thrombosis (31). Some MWL patients are still obese with medical comorbidities, which put them at greater risk for complications after surgery. Often, patients require long hospitalization to ensure optimal healing and minimize complications. The most common complications seen following body-lifting surgery include wound healing problems, seromas and lymphoceles, infections, venous thromboembolism, pulmonary embolism, lymphedema, hematomas, and nerve injury, as well as the need for blood transfusion post-operatively (7,32-34). Body image dissatisfaction is a frequent phenomenon in obesity and is correlated to low quality of life. An improvement of quality of life and body image after post-bariatric surgery is widely proven (35-36). Moreover, patients earn numerous benefits in term of physical and hygienic problems after body contouring surgery (37).

Conclusions

The MWL necessarily results in body contour deformities associated with physiological and psychological problems. The brachioplasty is a safe and effective technique to correct upper arm and lateral chest deformities following massive weight loss. The final scars are inconspicuous and the arm mobility is unrestricted. Similarly, thighplasty is a surgical procedure that yields excellent results in body contour improvement in obese patients.

References

1. Yang L, Colditz GA. Prevalence of Overweight and Obesity in the United States, 2007-2012. *JAMA Intern Med* 2015 Jun 22.
2. Shermak MA. Body contouring. *Plast Reconstr Surg* 2012 Jun; 129(6): 963e-978e
3. Santry HP, Gillen DL, Lauderdale DS. Trends in bariatric surgical procedures. *JAMA* 2005; 294: 1909-17.
4. Linner JH. Early history of bariatric surgery. *Surg Obes Relat Dis* 2007; 3: 569-70.
5. O'Brien PE. Bariatric surgery: Mechanisms, indications and outcomes. *J Gastroenterol Hepatol* 2010; 25: 1358-65.
6. Borud LJ, Warren AG. Body contouring in the postbariatric surgery patient. *J Am Coll Surg* 2006; 203: 82-93
7. Jones BM, Toft NJ. Bodylifting: indications, technique and complications. *J Plast Reconstr Aesthet Surg* 2008 Jul; 61(7): 730-5.
8. Shermak MA, ed. *Body Contouring*. New York: McGraw-Hill; 2011.
9. Lockwood T. Brachioplasty with superficial fascial system suspension. *Plast Reconstr Surg*. 1995; 96: 912-20.
10. Lewis Jr. The thigh lift. *J Int Coll Surg* 1956; 27: 330-4.
11. Kenkel JM, Eaves FF III. Medial thigh lift. *Plast Reconstr Surg* 2008; 122: 621-2.
12. Singh D, Forte AJ, Zahiri HR, et al. Prognostication for body contouring surgery after bariatric surgery. *Eplasty* 2012; 12: e46. Epub 2012 Sep 12.
13. American Society for Metabolic and Bariatric Surgery www.asbs.org.
14. Maggard MA, Shugarman LR, Suttorp M, et al. Meta-analysis: surgical treatment of obesity. *Ann Intern Med* 2005; 142: 547-59.
15. Han HH, Lee MC, Kim SH, et al. Upper arm contouring with brachioplasty after massive weight loss. *Arch Plast Surg* 2014 May; 41: 271-6.
16. Aly AS, Cram AE, Heddens C. Truncal body contouring surgery in the massive weight loss patient. *Clin Plast Surg* 2004; 31: 611-24.
17. Nemerofsky RB, Oliak DA, Capella JF. Body lift: an account of 200 consecutive cases in the massive weight loss patient. *Plast Reconstr Surg* 2006; 117: 414-30.
18. Van Geertruyden JP, Vandeweyer E, de Fontaine S, et al. Circumferential torsoplasty. *Br J Plast Surg* 1997; 52: 623e8.
19. Oranges CM et al. Medial Thigh lift in the massive weight loss population: outcomes and complication. *Plast Reconstr Surg* 2015
20. Guerrero-Santos J. Brachioplasty. *Aesthetic Plast Surg* 1979; 3: 1-4.
21. Strauch B, Greenspun D, Levine J, et al. A technique of brachioplasty. *Plast Reconstr Surg* 2004; 113: 1044-8.
22. Lockwood T. Brachioplasty with superficial fascial system suspension. *Plast Reconstr Surg* 1995; 96: 912-20.
23. Chowdhry S, Elston JB, Lefkowitz T, et al. Avoiding the medial brachial cutaneous nerve in brachioplasty: An anatomical study. *Eplasty* 2010; 10: e16.
24. Gusenoff JA, Coon D, Rubin JP. Brachioplasty and concomitant procedures after massive weight loss: a statistical analysis from a prospective registry. *Plast Reconstr Surg* 2008; 122: 595-603.
25. Aly A, Soliman S, Cram A. Brachioplasty in the massive weight loss patient. *Clin Plast Surg* 2008; 35: 141-7.
26. Appelt EA, Janis JE, Rohrich RJ. An algorithmic approach to upper arm contouring. *Plast Reconstr Surg* 2006 Jul; 118: 237-46.
27. Symbas JD, Losken A. An outcome analysis of brachioplasty techniques following massive weight loss. *Ann Plast Surg* 2010 May; 64: 588-91.
28. Shrivastava P, Aggarwal A, Khazanichi RK. Body contouring surgery in a massive weight loss patient: An overview *Indian J Plast Surg* 2008 Oct; 41(Suppl): S114-S129.
29. Aboueldahab AK. Liposuction-Assisted Medial Thigh Lift in Obese and Non Obese Patients *J Cutan Aesthet Surg* 2013 Oct-Dec; 6(4): 217-25.
30. Capella JF. The vertical medial thigh lift. *Clin Plast Surg* 2014 Oct; 41(4): 727-43.
31. Shermak MA, Chang DC, Heller J. Factors impacting thromboembolism after bariatric body contouring surgery. *Plast Reconstr Surg* 2007; 119: 1590-1596; discussion 1597-98.
32. Michaels J V, Coon D, Rubin JP. Complications in postbariatric body contouring: Strategies for assessment and prevention. *Plast Reconstr Surg* 2011; 127: 1352-57.
33. Capella JF. Body lift. *Clin Plast Surg* 2008; 35: 27-51; discussion 93.
34. Au K, Hazard SW III, Dyer AM, et al. Correlation of complications of body contouring surgery with increasing body mass index. *Aesthet Surg J* 2008; 28: 425-9.
35. Rosen JC. Improving body image in obesity. In: Thompson JK, ed. *Body Image, Eating Disorders, and Obesity*. Washington, DC: American Psychological Association; 1996: 425-40.
36. Stunkard AJ, Stinnett JL, Smoller JW. Psychological and social aspects of the surgical treatment of obesity. *Am J Psychiatry* 1986; 143: 417-29.
37. Coriddi MR, Koltz PF, Chen R, et al. Changes in quality of life and functional status following abdominal contouring in the massive weight loss population. *Plast Reconstr Surg* 2011; 128: 520-6.

Received: 24 June 2015

Accepted: 26 November 2015

Correspondance:

Michele Grieco, MD

Dep. of Surgical Sciences, Plastic Surgery Division,
University of Parma, Italy

Cutaneous, Regenerative, Mininvasive and

Plastic Surgery Unit,

Parma University Hospital - Italy

E-mail: dr.mgrieco@yahoo.it