

## Personal technique for wrist dorsal approach

*A. Marcuzzi<sup>1\*</sup>, M. Leigheb<sup>1-2\*</sup>, A. Russomando<sup>1</sup>, A. Landi<sup>1</sup>*

<sup>1</sup>Complex Structure of Hand and Microsurgery, "Policlinico di Modena" University Hospital, Modena (Italy); <sup>2</sup>Complex Structure of Orthopaedics and Traumatology, "Maggiore d.c." Hospital, Eastern Piedmont University, Novara (Italy)

\* Authors contributed equally to this manuscript

**Abstract.** In hand disorders surgical procedures are more and more widely used and often it's necessary to approach the wrist by the dorsal way. Beneath anatomy of this region is well known, there is still room enough to develop new surgical exposure techniques mostly related to physiology and biomechanics. Our goals are to present an innovative surgical dorsal exposure of the wrist, to show its use for different problems solving, and to evaluate its mini-invasive and functional outcome. Our inedited surgical technique is presented. Since November 1999 to February 2008, this technique has been used by the same surgeon in 60 cases for different pathologies and procedures: 14 SNAC-SLAC wrists III-IV treated by proximal row resection and Resurface-Capitate Pyrocarbon Implant (RCPI), 2 Fenton syndromes by bone graft and RCPI, 6 SNACSLAC II by proximal row resection +/- radial styloidectomy, 2 SLAC III by scaphoidectomy and capito-lunate arthrodesis, 12 scapho-lunate recent dissociations by ligamentoplasty (double approach), 4 scapho-lunate inveterate dissociations by Cuenod Saffar-Romano modified technique and 4 by synthetic ligaments, 1 fracture of the scaphoid proximal pole by synthesis-revascularization-S.L.ligament reconstruction, 15 Kienbock's diseases revascularized by II m.c. artery +/- radial osteotomy. Patients have been evaluated at follow up through the DASH disability questionnaire, the Mayo score for the force, ROM, pain, satisfaction grade. Results are good and encouraging for these applications. In conclusion this new technique with its limited exposure permits an early mobilization with a lower risk of stiffness and can be considered mini-invasive. ([www.actabiomedica.it](http://www.actabiomedica.it))

**Key words:** approach, wrist, carpal, carpus, surgical technique, dorsal

### Introduction

In hand surgery option to surgical procedures is becoming wider and wider and often a dorsal approach to the wrist is needed. Beneath anatomy of this region is already well known (1-5), there is still room enough to develop new surgical exposure techniques mostly related to physiology and biomechanics.

In the dorsum of the wrist superficial markers are represented by the styloid processes of radius and cubitus and by Lister's tubercle; extensor tendons are detectable in the subcutaneous room distally to the retinaculum (especially by active extension) (3).

Although Langer's tension lines have a transversal disposition, skin of this region is very elastic and not adherent to the deep layer and so incision can be more than transverse (6-9) (limited by a poor proximo-distal exposition), also straight longitudinal (6, 8, 10-12) (the longer it is the wider the transversal exposition is), or curve-sinusoidal longitudinal with an italic-S shape (4, 6-8) or zig-zag broken (6), or oblique (4, 6, 8), or tryradiate (6).

The optimal passage in the subcutaneous adipose tissue below the fascia superficialis follows the longitudinal median line between the superficial sensory branches of radial nerve (and skin artery) and the dor-

sal branch of ulnar artery and nerve that must be respected; if possible veins must be preserved tying or cauterizing only the anastomotic ones with a transverse or oblique disposition; at the level of the mid-carpal joint the dorsal anastomotic arch of the carpus should be respected since it connects the radial artery with the dorsal branch of the ulnar artery and gives rise to the 2<sup>nd</sup>, 3<sup>rd</sup> and 4<sup>th</sup> dorsal metacarpal arteries (1-5) (Fig. 1).

The fascia antibrachialis continues distally in the extensor retinaculum which is a thickening with function of a pulley. It fits on the radio-palmar face of the radius and, on the ulnar side, on the pisiform and triquetrum. Six vertical septi, rising from the periosteum of the distal radius and from the radio-carpal and distal radio-ulnar capsule, divide the six compartments of the twelve extensor tendons. The posterior interosseous nerve (P.I.N.) of the forearm runs on the floor of the fourth compartment to address the radiocarpic joint (1-5).

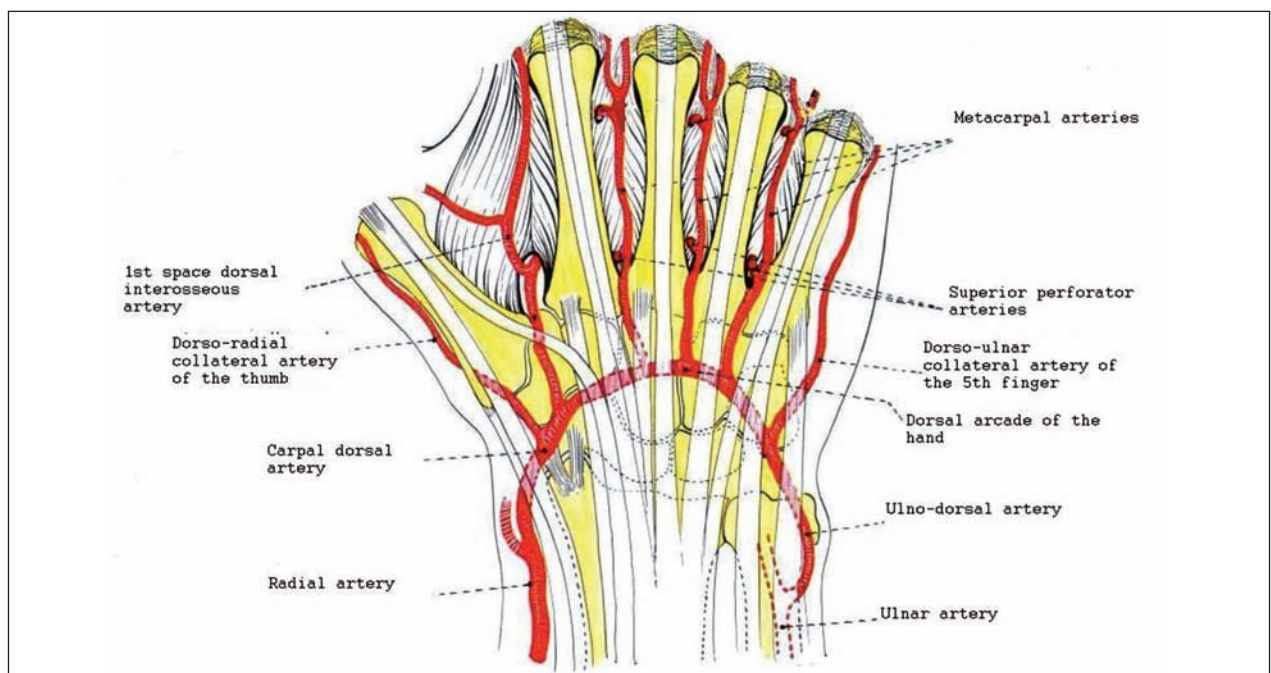
The artery of the 4<sup>th</sup> compartment arises from the posterior branch of the anterior interosseous artery (55%) or from the artery of the 5<sup>th</sup> compartment (45%); it runs in the septum (30%) or in direct contact with the posterior interosseous nerve in the radial part

of the 4<sup>th</sup> compartment (70%); it ends into the dorsal intercarpal arcade (94%) and/or into the dorsal radio-carpal arcade (59%), and/or into the intercompartmental 2-3 artery (38%) and/or into the artery of the 5<sup>th</sup> compartment (34%); it leaves small branches to the bone of the floor of the compartment (5, 13).

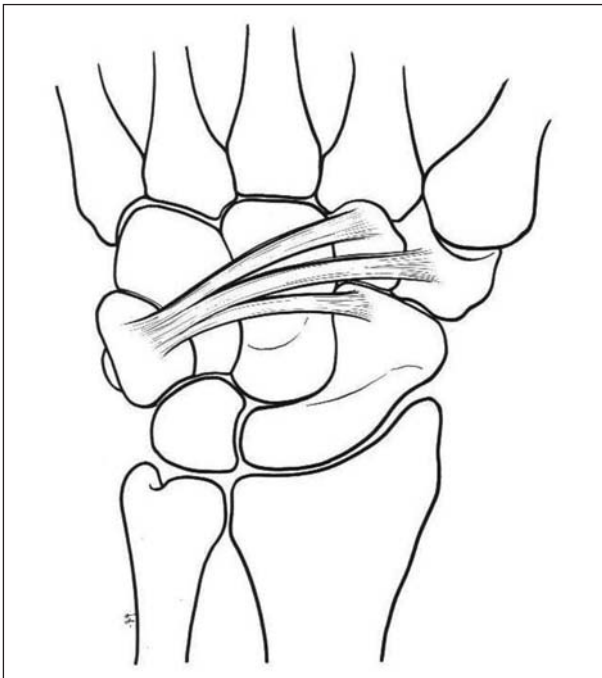
The dorsal capsule of the radio-carpic and medio-carpic joints is reinforced by three ligaments that converge towards the rear face of the triquetrum (1-5):

- 1) the dorsal radio-carpal or radio-luno-triquetral ligament;
- 2) the dorsal ulno-carpal ligament stretched from the dorsal edge of the meniscus of the D.R.U.J. to the rear side of the triquetrum;
- 3) the dorsal medio-carpal ligament or scapho-trapezium-triquetral, stretched from the rear face of the triquetrum to the scaphoid tubercle, to trapezium and to trapezoid. (Fig. 2)

The dorsal approaches to the radio-carpic and medio-carpic joints described by Herzberg and Berger (14), rather than cutting these ligaments perpendicularly to their direction or detaching them from the radius, prefer to split them in the direction of their fibers, creating a V-flap with triquetral apex, enough



**Figure 1.** Dorsal arterial vascularization of the hand. From Bonola et al. with permission (2)



**Figure 2.** The dorsal medio-carpal ligament with its three bundles. From Bonola et al. with permission (2)

to enter the radial compartment of the radio-carpal joint, or through a Z-incision to create two flaps with triquetral and radial apices, to expose the entire dorsal side of the joints of the wrist (5). The standard surgical approaches provide the longitudinal incision of the retinaculum on the IV compartment and then the subperiosteal dissection towards the radial and ulnar sides (3).

The extensor retinaculum can be cut longitudinally on the ulnar side of the wrist and released from the underlying extensor tendons. Once the fibrous septum is cut, the flap containing the retinaculum is lifted and displaced. It is so possible to highlight the compartments from 2 to 6. The extensor digitorum communis tendons are displaced on the ulnar side while the extensor pollicis longus and the extensores carpi radialis on the radial side, thus highlighting the dorsal capsule of the wrist. A capsular flap with distal base is then harvested and lifted. At the end of the surgical procedures the capsule can be reinserted to the distal rim of the radius with an intraosseous suture (4).

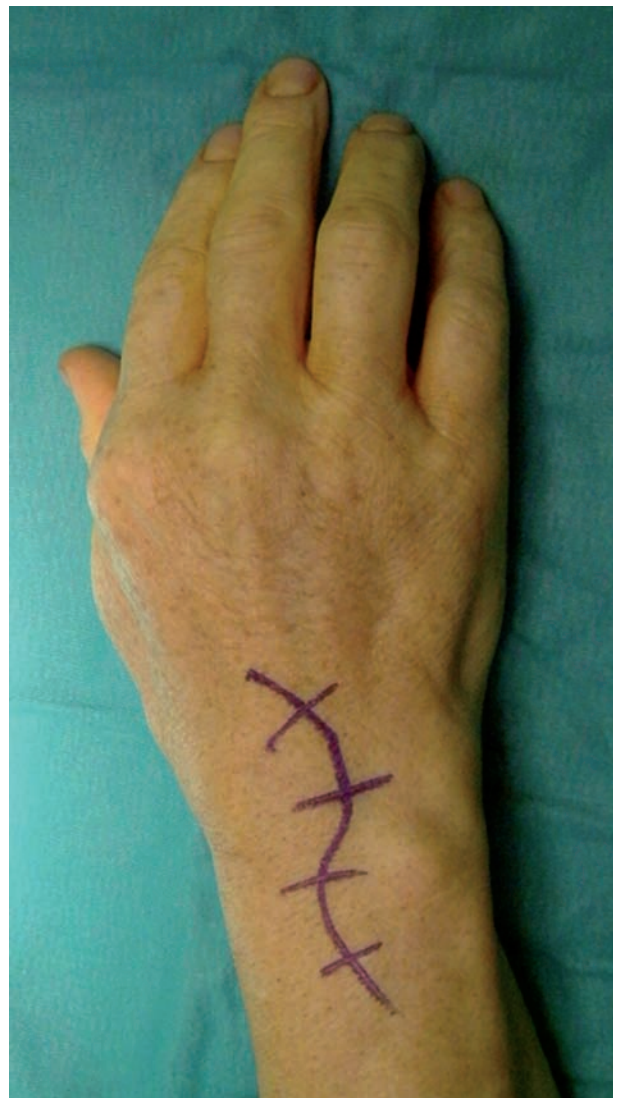Biyani et al. (15) suggest the lifting of a bony flap with radial base in the floor of the 2<sup>nd</sup> and 3<sup>rd</sup> compartments (without opening them) through the 4<sup>th</sup> com-

partment but do not lead to innovations at the radio-carpic and carpal level.

*Purposes* of the study are: to present an innovative surgical dorsal exposure of the wrist, to show its possibility of use for different problems solving, and to evaluate its mini-invasive and functional outcome.

#### *Surgical technique*

Our surgical approach starts with a curved longitudinal cutaneous incision at the dorsum of the wrist over the fourth extensor's compartment (Fig. 3) in the



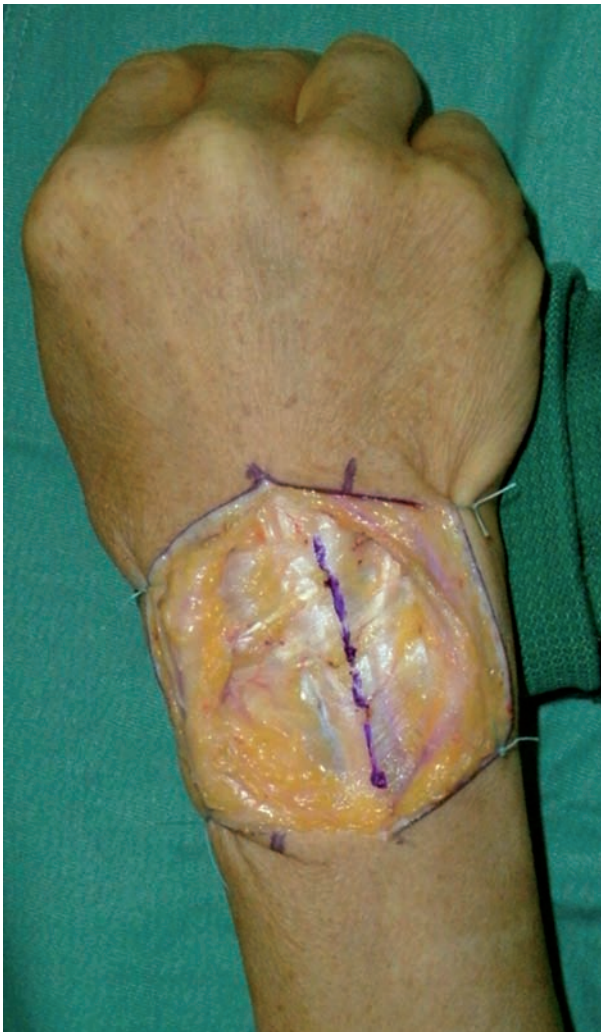**Figure 3.** Cutaneous incision



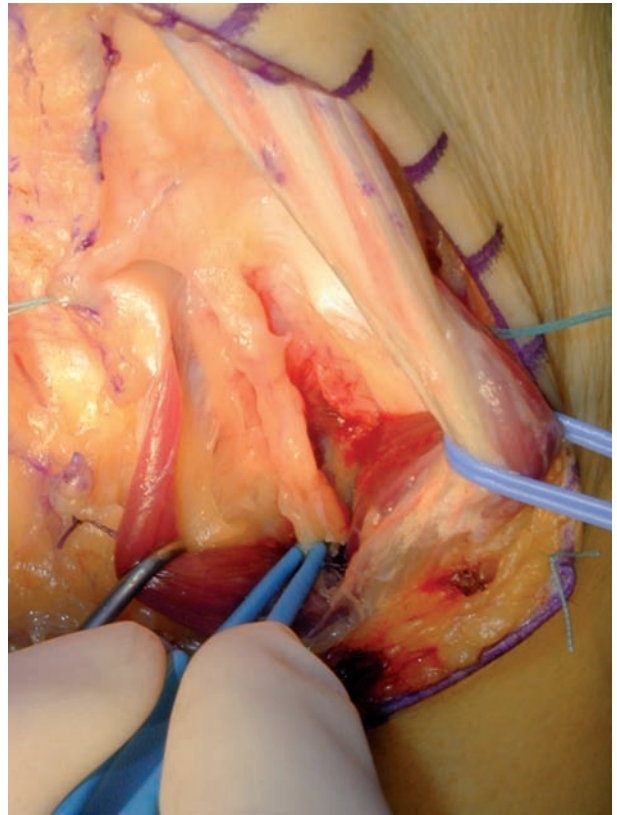
respect of the main superficial venous vessels and the superficial nerves of the dorsum of the wrist.

Extensor's retinaculum is then opened longitudinally in the fourth compartment (Fig. 4) and extensor digitorum comunis as well as propri indicis tendons are displaced on the ulnar side (Figg. 5-6), showing the posterior interosseous nerve (P.I.N.) wich is ablated. (Fig. 5).

Then a rectangular capsular flap proximally based is harvested in the floor of the fourth compartment (Fig. 6) with the distal transverse incision proximal to the arterial carpal dorsal arcade (Fig. 1) and to the dorsal intercarpal (D.I.C.) legament (Fig. 2). Elevating and rolling this capsular flap the carpus and radio-



**Figure 4.** Retinaculum incision on the IV compartment



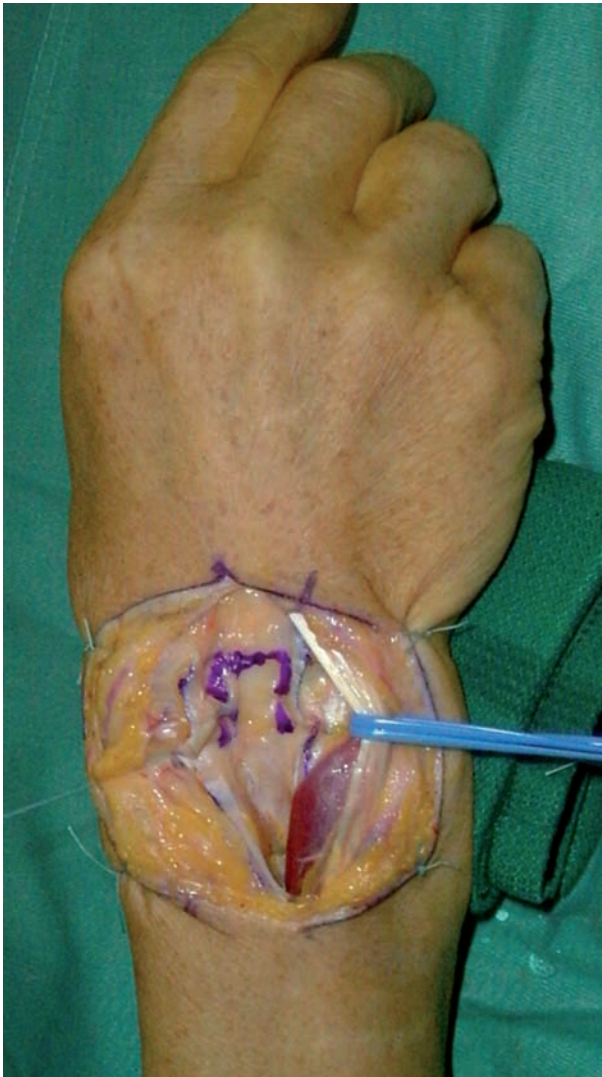**Figure 5.** Ablation of I.P.N. (interosseous posterior nerve)

carpal joint are reached over the scapho-lunate space (Figg. 7-8). After the needed surgical procedures the anatomical planes are then stitched (Fig. 9).

#### *Cases of clinical application of our technique*

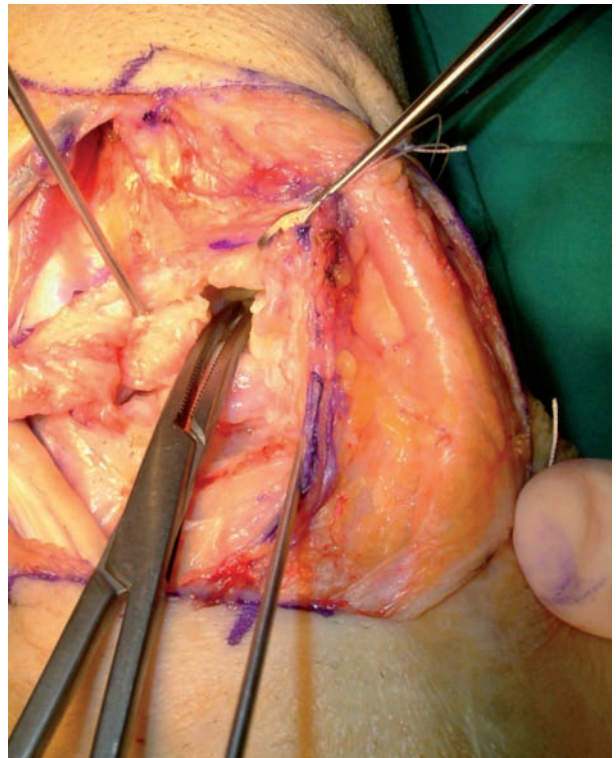
In our institution between November 1999 and February 2008 we applied the described surgical approach in a total of 60 consecutive cases affected by the following pathologies and relative treatment:

- 14 cases of S.N.A.C. or S.L.A.C. wrist in III-IV stade treated by proximal carpectomy and implant of Resurfacing Capitate Pyrocarbon Implant (R.C.P.I.) (Fig. 8).
- 2 cases of chronic Fenton syndrome (transcapitoid-transcapitate perilunar fracture-dislocation) treated by bone graft in the scaphoid and RCPI prosthesis.
- 6 cases of SNAC or SLAC wrist in II stade treated by proximal row carpectomy +/- radial styloidectomy.

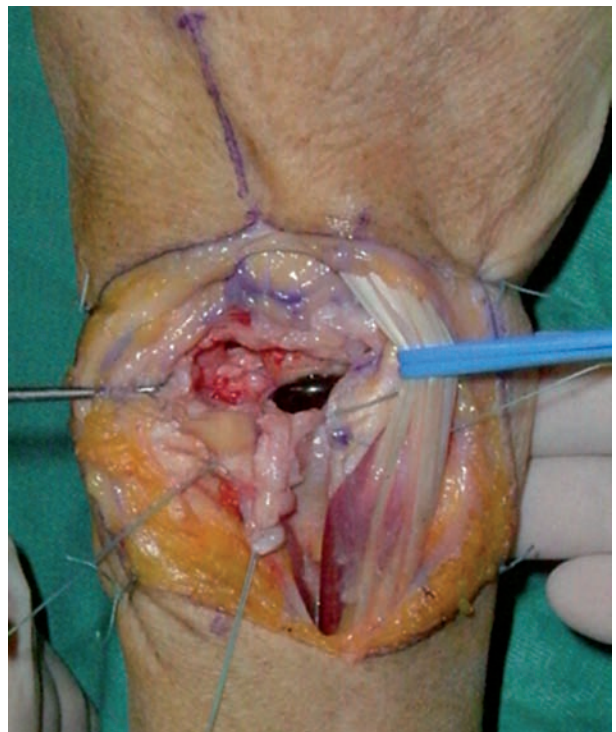

**Figure 6.** Capsular flap in the floor of the IV extensors compartment

- 2 cases of SLAC III wrist treated by scaphoidectomy and capito-lunate arthrodesis.
- 12 cases of recent scapho-lunate dissociation treated by ligament reconstruction and stabilization with Kirschner percutaneous wires by double dorsal and palmar approach (16).
- 4 cases of chronic scapho-lunate dissociation treated by Cuenod technique (17) modified by Saffar-Romano (ligamentoplasty with bone bricks from trapezoid and II metacarpal bone) (18).
- 4 cases of non recent scapho-lunate dissociation treated by syntetic ligaments (19).

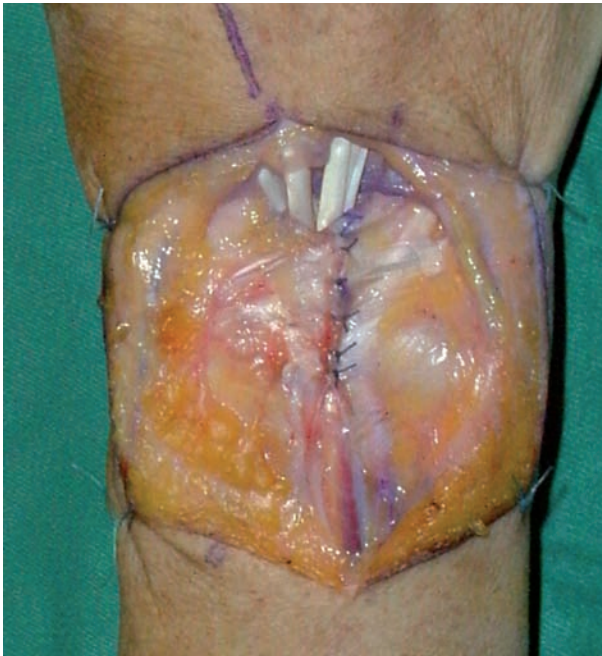

**Figure 7.** Scapho-lunate space



**Figure 8.** Prosthesis of the capitate head in pyrocarbon (RCPI)





**Figure 9.** Stitches at the retinaculum

- 1 particular case of fracture of the proximal pole of the scaphoid treated by syntesis-revascularization plus reconstruction of the scapho-lunate ligament.
- 15 cases of di Kienbock's disease treated by revascularization with the 2nd intermetacarpal artery +/- shortening osteotomy of the radius.

All the mentioned surgical interventions have been performed by the same surgeon (first author) in loco-regional anesthesia with brachial-plexus block and in limb ischemia with tourniquet at the arm.

## Method

All the patients undergone surgical operation of the wrist by the new described approach technique have been evaluated, when included in the first and second group of the above-shown cases plus those treated by double approach for scapho-lunate ligament reconstruction (16).

D.A.S.H. (Disabilities of the Arm, Shoulder and Hand) questionnaire has been used since it is based on symptoms and ability to perform certain daily life activities (20).

To evaluate strength, Jamar and Pinch dynamometers have been used for grasping and pinch test. Force recover has been estimated by the Mayo Score compared with the contralateral wrist-hand (21).

Pain has been classified into: none, slight, heavy.

Patient's opinion has been considered as satisfying or not.

Active Ranges of Movement (R.O.M.) of all patients have been compared in degrees, for flexion, extension, radial and ulnar deviation of the wrist.

## Results

Results obtained for the *first two groups* of cases are reported in table 1 and regard 16 patients undergone R.C.P.I. prosthetic implant with a mean follow up of 25 months (min. 10 – max. 62).

The male/female rate is 13/3 (81/19 %), mean age is 51 +/-15 years (min. 22, max 75), the right wrist is interested in 14 cases (88%) and the left in 2 cases (12%).

Mean range of movement is 42° (+/- 16°) in flexion, 45° (+/- 8°) in extension, 15° (+/- 6°) in radial deviation, 33° (+/- 7°) in ulnar deviation; the mean value of total flexion-extension is 87°, which is the 48 % of 180° complete R.O.M.

Force recover evaluated by the Mayo Score (21) has a mean value of 69% (S.D. 21,3; min. 39% - max 116%); in patients n° 1 and n° 3 value is higher than 100% because compared with a not completely healthy contralateral wrist.

Pain resulted absent in 12 cases (75%), moderate in 4 cases (25%) and heavy in none.

Mean of D.A.S.H. scores (20) is of 7 points (S.D. 4,8; min. 1,7 - max 18,7 points).

All patients revealed to be satisfied by the surgical outcome.

The group of patients treated of *scapho-lunate ligament reconstruction* by double approach (16) (Tab. 2) has a mean follow up of 52 months (range 6-98).

Mean total range of movement of the operated wrist results in 95° +/-23°.

The mean grasping strenght (21) is 80% respect to the healthy side and the pinch force is 90%.

Only one patient did complain pain in the daily

**Table 1.** Patients treated by proximal row carpectomy and R.C.P.I. prosthesis implant

N	Pt	Sex	AGE' (yy)	Cause	Side	Follow-up (mm)	Flex°	Est°	Uln°	Rad°	Force. rec Mayo Score (%)	Pain	DASH	Patient's opinion
1	CA	M	66	SNAC III	L	52	25	45	50	10	110,75	Absent	1,7	Satisfied
2	MA	M	75	SLAC III	R	36	30	35	20	10	41,2	Moderate DRUJ	13,4	Satisfied
3	GS	M	64	SLAC III	R	30	90	60	35	10	116,3	Absent	3,3	Satisfied
4	CL	F	60	SLAC III	R	28	30	45	25	25	39,2	Absent	1,7	Satisfied
5	RG	F	57	SLAC III	R	25	35	40	25	20	59,7	Absent	7,2	Satisfied
6	CL	M	22	SNAC IV	L	24	60	50	35	10	51,0	Absent	5	Satisfied
7	CA	M	32	SNAC IV	R	20	40	45	25	10	60,3	Moderate TFCC	9,3	Satisfied
8	BR	M	47	SNAC III	R	18	45	50	35	10	55,8	Moderate	5,8	Satisfied
9	ZG	M	72	SLAC III	R	15	50	55	35	20	78,2	Absent	4,8	Satisfied
10	CL	M	44	SNAC IV	R	14	30	35	35	10	75,3	Absent	12,1	Satisfied
11	GG	M	50	SLAC III	R	12	30	35	35	10	61,4	Absent	7,3	Satisfied
12	PG	M	47	SNAC III	R	12	50	40	35	20	69,8	Absent	7,9	Satisfied
13	FA	F	58	SLAC III	R	11	45	40	35	20	61,1	Absent	18,7	Satisfied
14	CC	M	43	SLAC III	R	10	35	40	25	20	65,0	Absent	2,1	Satisfied
15	PS	M	37	Fenton Snd	R	62	35	40	35	20	74,8	Moderate (stylo-scaph.)	9,2	Satisfied
16	MM	M	44	Fenton Snd	R	28	45	60	35	20	83,9	Absent	1,8	Satisfied
<b>Mean</b>	<b>M/F</b>		<b>51</b>		<b>R/L</b>	<b>25</b>	<b>42</b>	<b>45</b>	<b>33</b>	<b>15</b>	<b>69</b>		<b>7,0</b>	<b>100%</b>
			<b>13/3</b>			<b>14/2</b>								
<b>St.Dev.</b>			<b>14,5</b>			<b>14</b>	<b>16</b>	<b>8</b>	<b>7</b>	<b>6</b>	<b>21,3</b>		<b>4,8</b>	

activities having to wear a splint in the working activities in order to reduce the pain.

The mean back to job time is 105 days (range 70-180) after the surgical operation.

The mean DASH score (20) is of 12,6 points but it varies too much (min. 1, max 40, SD 13,2).

## Discussion

Our results look satisfactory and encouraging for the use of this new surgical technique.

Only four patients in Table 1 suffer from moderate pain and three of these recognize a cause and specific location other than the access point surgery.

Patients 1 and 3 (Tab. 1) show a Mayo score (21) higher than 100% in the wrist operated on, as compared with another pathological wrist (bilateral).

The first two patients treated on have a reduced range of motion (ROM) because immobilized cautiously for a time considerably longer than the following cases but later we used the miniminvasivity of our technique for earlier mobilization and Kinesitherapy.

We separate the results into two groups (Table 1 and 2) because in the 2nd dorsal access route has been associated with the volar one, and therefore one group was not homogeneous enough.

We have not considered for the moment a control group but we aim for a future development of the study to evaluate a group of comparison patients

**Table 2.** Patients with recent scapho-lunate dissociation treated with ligamentous reconstruction.

N	Pt	Age	Sex	Side	Pre-op. wrist ROM	Follow-up wrist ROM	Pre-op. pinch strength (kg)	Follow-up pinch strength (kg)	Contra- lateral pinch strength (kg)	Pre-op. Grip strength (kg)	Follow-up Grip strength (kg)	Contra- lateral Grip strength (kg)	Follow-up DASH score
1	DR	73	M	L	Flex. 0° Ext. 0°	Flex. 50° Ext. 63°	2	17	17	4	30	33	1
2	VG	43	M	R	Flex. 0° Ext. 0°	Flex. 49° Ext. 60°	1	7.5	9.5	3	35	36	6
3	CS	38	M	R	Flex. 25° Ext. 30°	Flex. 45° Ext. 63°	4	8.5	8.5	15	39.5	42	33
4	VA	29	M	R	Flex. 8° Ext. 10°	Flex. 8° Ext. 33°	2	6.5	8.5	4	10.5	33	40
5	MF	32	M	R	Flex. 10° Ext. 20°	Flex. 53° Ext. 66°	3	7.5	8.5	10	23.5	37.5	7.5
6	NA	24	M	L	Flex. 0° Ext. 0°	Flex. 57° Ext. 62°	3	18	23	5	31	43	20
7	BA	60	M	L	Flex. 0° Ext. 0°	Flex. 45° Ext. 52°	3	18	19	3	28	30	1
8	MM	47	M	R	Flex. 20° Ext. 30°	Flex. 30° Ext. 40°	2	18	20	3	18	29	15
9	GA	30	M	L	Flex. 0° Ext. 0°	Flex. 50° Ext. 45°	2	20	20	2	32	32	2
10	EG	32	M	R	Flex. 0° Ext. 0°	Flex. 45° Ext. 55°	3	19	20	2	30	31	4
11	MF	45	M	R	Flex. 0° Ext. 0°	Flex. 30° Ext. 45°	2	15	20	1	18	30	20
12	DE	36	M	R	Flex. 6° Ext. 8°	Flex. 40° Ext. 55°	3	19	20	1	30	30	2
<b>Mean</b>		<b>41</b>	<b>100</b>	<b>%R/L</b>	<b>Flex. 6°</b>	<b>Flex. 42°</b>	<b>2.5</b>	<b>12,1</b>	<b>13,4</b>	<b>4,4</b>	<b>27,1</b>	<b>33,9</b>	<b>12,6</b>
			<b>M</b>	<b>8/4</b>	<b>Ext. 8°</b>	<b>Ext. 53°</b>							
					<b>Tot. 14°</b>	<b>Tot. 95°</b>							
<b>St.Dev.</b>		<b>14</b>			<b>Flex. 9°</b>	<b>Flex. 14°</b>	<b>0,8</b>	<b>8,8</b>	<b>9,7</b>	<b>4,1</b>	<b>8,2</b>	<b>4,8</b>	<b>13,2</b>
					<b>Ext. 13°</b>	<b>Ext. 11°</b>							
					<b>Tot. 22°</b>	<b>Tot. 23°</b>							

treated with the standard dorsal access to the wrist to increase the power of the study placing as primary outcome the advantage of our technique compared to those normally used.

For a surgical procedure can be said miniminvasive it is essential that its therapeutic benefit is greater than the damage which may involve surgery.

In literature, not all authors respect the 3rd extensor compartment without dislocating the E.P.L. tendon (15).

According to Garcia-Elias et al. (22) the dorsal

approach is preferred to the volar one in the use of bone graft for nonunion of the scaphoid as it saves the precious volar radio-carpal ligaments.

The arthroscopy completely preserves all the ligaments and therefore the stability of the carpus but presents difficulties and technical limitations which are not indifferent.

Our technique in particular allows early mobilization of the wrist that results in a decrease in postoperative stiffness and thus in a reduced and mini invasive procedure.



The only drawback lies in reduced operating light with consequent initial difficulties to perform the resection of the proximal carpal row.

In conclusion this work, compared to the current world literature, demonstrates an innovative surgical technique never described before, with characteristics of mininvasivity and applicable with good results for various surgical solutions in many diseases of the wrist.

## References

- Netter F.H. Atlante di anatomia, fisiopatologia e clinica. Vol. 8 Apparato muscoloscheletrico, Parte I, Sez.1. Ciba Edizioni 1988 rist.'96: 56,57,60,69.
- Bonola A, Caroli A, Celli L. La mano. Piccin editore-Padova 1981: 51-309.
- Hoppenfeld S, deBoer P. Vie di accesso e anatomia chirurgica in ortopedia. Verduci ed. 2000; cap.5: 147-222. (Surgical exposures in orthopaedics. The anatomical approach. JB Lippincott Company – Philadelphia).
- Tubiana R, McCullough CJ, Masquelet AC. Atlante delle vie chirurgiche d'accesso dell'arto superiore. Delfino Ed.'96: 168, 221-245. (An Atlas of Surgical Exposures of the Upper Extremity. London, Martin Dunitz, 1990).
- Fontaine C, Wavreille G, Chantelot C, Prodhomme G. Surgical anatomy of the dorsal face of the hand and the wrist. *Chir Main* 2005; 24 (2): 64-78.
- Barbieri CH, Mazzer N. Triradiate skin incision for dorsal approach to the wrist. *J Hand Surg* 1996; 21B(1): 21-23.
- Boyd HB. Surgical Approaches. In: Crenshaw, AH, ed. Campbell's Operative Orthopaedics. Louis, C.V. Mosby, 197t, Vol. 1: 58-137.
- Taleisnik J. The Wrist. New York, Churchill Livingstone, 1985: 169-194.
- Watson HK, Dhillon HS. Intercarpal Arthrodesis. In: Green DP, ed. Operative Hand Surgery. New York, Churchill Livingstone, 1993, Vol. 1: 113-130.
- Beckenbaugh RD, Linscheid RL. Arthroplasty in the Hand and Wrist. In: Green DP, ed. Operative Hand Surgery. New York, Churchill Livingstone, 1993, Vol. 1: 143-187.
- Dick HM. Wrist Arthrodesis. In: Green DP, ed. Operative Hand Surgery. New York, Churchill Livingstone, 1993, Vol. 1: 131-142.
- Green DP. Carpal Dislocations and Instabilities. In: Green DP, ed. Operative Hand Surgery. New York, Churchill Livingstone, 1993, Vol. 1: 861-928.
- Sheetz KK, Bishop AT, Berger RA. The arterial blood supply of the distal radius and ulna and its potential use in vascularized pedicled bone grafts. *J Hand Surg* 1995; 20A: 902-914.
- Berger RA, Bishop AT, Bettinger PC. New dorsal capsulotomy for the surgical exposure of the wrist. *Ann Plast Surg* 1995; 35(1): 54-59.
- Biyani A, Ebraheim NA, Lu J, Yeasting RA. A modified dorsal approach to the wrist for arthrodesis of the non-rheumatoid wrist. An anatomical study. *J Hand Surg* 1996; 21B(4): 434-436.
- Marcuzzi A, Leti Acciaro A, Caserta G, Landi A. Ligamentous reconstruction of scapholunate dislocation through a double dorsal and palmar approach. *J Hand Surg* 2006; 31B(4): 445-449.
- Cuenod P, Charriere E, Papaloizos MY. A mechanical comparison of bone-ligament-bone autografts from the wrist for replacement of the scapholunate ligament. *J Hand Surg* 2002; 27A(6): 985-990.
- Saffar P, Sokolow C, Duclos L. Soft tissue stabilization in the management of chronic scapholunate instability without osteoarthritis. A 15 year serie. *Acta Orthop Belg* 1999; 65(4): 424-433.
- Bosetti M, Boccafoschi F, Calarco A, Leigheb M, Gatti S, Piffanelli V, Peluso G, Cannas M. Behaviour of human mesenchymal stem cells on a polyelectrolyte-modified HEMA hydrogel for silk-based ligament tissue engineering. *J Biomater Sci Polym Ed.* 2008; 19(9): 1111-1123.
- Padua R, Padua L, Ceccarelli E, Romanici E, Zanoli G, Amadio PC, Campi A. Italian version of the disability of the arm, shoulder and hand (DASH) questionnaire. Cross-cultural adaptation and validation. *J Hand Surg* 2003; 28B(2): 179-186.
- Mathiowetz V, Kashman N, Volland G, Weber K, Dowe M, Rogers S. Grip and pinch strength: normative data for adults. *Arch Phys Med Rehabil* 1985; 66(2): 69-74.
- Garcia-Elias M, Vall A, Salo JM, Lluch AL. Carpal alignment after different surgical approaches to the scaphoid: a comparative study. *J Hand Surg* 1988; 13A(4): 604-612.

Correspondence:

Dr Augusto Marcuzzi

Largo del Pozzo, 71

41100 Modena, Italy.

Tel: +39 059-4224494

Fax: +39 059-4222818

E-mail: marcuzzi.augusto@policlinico.mo.it