

# The treatment of proximal humeral fractures with a “Polarus” intramedullary nail

*C. Dall’Oca, T. Maluta, N. Leone, G.M. Micheloni, F. Lavini*

Department of Orthopaedic Surgery and Traumatology of the University Hospital of Verona, G.B. Rossi Polyclinic of Verona

**Abstract.** Proximal humeral fractures are complex lesions with difficult management problems; therefore, they pose a challenge for orthopaedic surgeons. In the literature, numerous treatment techniques have been proposed for these kinds of fractures. In our study we reviewed 30 patients with a mean age of 75 years presenting a proximal humeral fracture (Neer 2-3) and treated at our clinic with a Polarus nail, with a mean follow-up of 7 years. We obtained 73.3% of good and excellent results in line with literature. Complications were recorded in 6 of the patients (20%) recruited in our study. In particular, 3 cases of proximal screw pull-out, 1 case of deep infection and 2 cases of acromio-clavicular joint impingement syndrome. The aim of our study was to review our case histories and compare them with the literature analysing this complex type fracture and treatment options. ([www.actabiomedica.it](http://www.actabiomedica.it))

**Key words:** proximal humeral fractures, neer classification, Constant-Murley score, intramedullary nail, Polarus, pull-out, augmentation

## Introduction

Proximal humeral fractures represent 5% of all fractures, showing an incidence rate ranging from 48 to 142 cases every 100.000 individuals (1).

Epidemiological studies show an exponential increase of these fractures after the fifth decade due to senescence-associated poor bone quality with reduced trabecular bone density and cortical thinning exposing the elderly population to a high risk of fractures even following low-energy traumas (2).

The economic consequences for our society (social services and health care costs) of this type of lesion are significant; patients with proximal humeral fractures often face reduced mobility and independence due to serious functional limitations and therefore require assistance in performing even basic, everyday activities.

The treatment of this type of lesion has progressively changed over the years but clinical-functional results are far from being completely satisfactory.

In fact, these fractures are difficult to treat, as they tend to have a greater prevalence in elderly osteoporotic patients due to involvement of the joint surface, a possibility of avascular necrosis leading to the osteonecrosis of the humeral head, and a difficult reconstruction of multiple fragment fractures (3). The displacement of two or more fracture fragments necessarily requires surgical stabilisation since the interposition of soft tissues could induce a consolidation of the fracture associated with total instability, as well as significant articulation deficits (4, 5). Currently, numerous treatment techniques are available. However, in the light of available results, there is no gold standard treatment (6-8). Among the various methods available, percutaneous K-wire fixation offers biological benefits, how-

ever, clear clinical benefits have not yet been recorded due to the difficulty of maintaining an effective and long-lasting reduction and due to the risk of damaging noble structures.

Intramedullary nailing with Ender-type pins (Gandolfi-Malavota) requires a cautious approach and slow learning curve. It does not guarantee a control of rotatory forces and does not allow the compression of the fracture, thus increasing the risk of pseudoarthrosis (9). Elastic nails (Vincenzi-Marchetti), a natural evolution of the Ender nails, have reduced duration of surgery and complications without however, having resolved the problems linked to the low resistance of the rotatory forces still requiring post-surgery immobilisation.

Plate fixation offers greater stability but to the detriment of longer surgical exposure, increasing the risk of avascular necrosis of the humeral head. In the literature, some authors consider this synthesis technique as extremely effective even if loss of reduction has frequently been recorded, observed during rehabilitation at routine ambulatory check-ups. This complication is due to the reduced stability of the synthesis device at the level of the humeral head, described by many authors as an empty "eggshell": the rigidity of the device associated with excessive bone porosity significantly increases the possibility of migration of the proximal screws (10, 11). Another aspect to consider is the acromioclavicular joint synthesis device due to the operator mal-positioning the plate or to the displacement of the humeral head due to reduced screw stability in the osteoporotic bone (12).

Replacement of the shoulder joint with a prosthesis in elderly patients presenting with fractures characterised by a breakdown and fragmentation of the humeral head is considered by some authors as the golden standard even if in the literature results are discordant (13, 14).

The ability to limit bleeding preserving tissue integrity, the low incidence of avascular necrosis documented in the literature, the necessity to reduce immobilisation times and the quick recovery of functionality of the shoulder have led to growing interest in the use of intramedullary nails (15). The use of this type of technique allows to achieve a multidirectional and multilevel proximal synthesis, preventing the displace-

ment of fragments and contrasting rotatory forces in an elastic manner.

This is the reason why we decided to present our study on the treatment of proximal humeral fractures with the use of Polarus intramedullary nails (16-18).

## Materials and methods


At the Orthopaedic Department of the University Hospital in Verona, between January 2000 and July 2007, we examined 30 patients (16 males and 14 females) treated with a Polarus nail. The mean age was 75 years, (range 45-82). All fractures were reduced and a post-traumatic cause was identified. The right humerus was affected in 18 cases, whereas the left humerus was affected in 12 cases. Fractures were classified using the Neer classification (19, 20): 18 Neer type II, 12 Neer type III. In all patients, in order to study the articular fragments and due to the difficulty of classifying the fractures with standard radiology, CT scans were necessary (Figures 2, 3, 4). The mean follow-up was 7 years (range 4 -11).

Patients were assessed radiologically and clinically using the Constant-Murley shoulder score at 3, 6, and 12 months and then every year after surgery (21). By assigning a maximum score of 100 points, this scoring system considers various aspects such as pain, recovery of normal articulation returning to performing everyday activities and recovering normal strength.

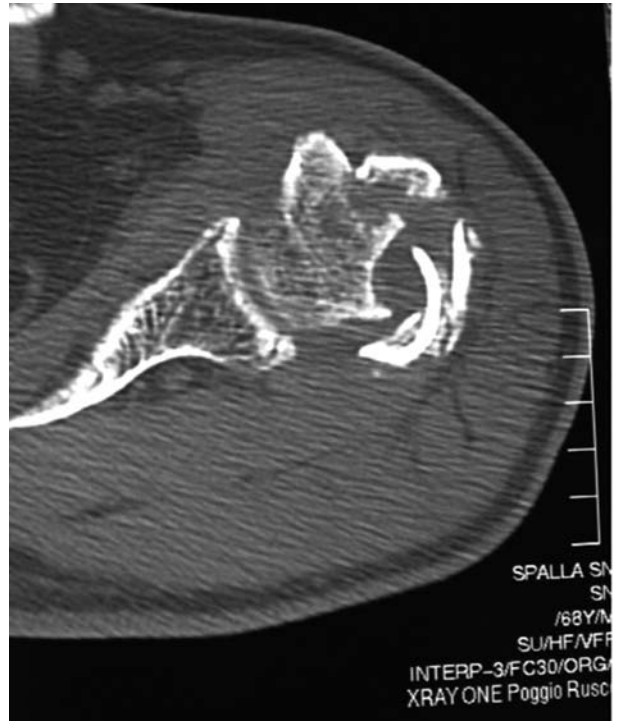The Polarus intramedullary nail is a cannulated nail in titanium with a standard diameter of 150mm that has four holes for four 5 mm screws at the level of the humeral head. The new version consists of threaded screws and 2 holes for 3.5 mm cortical distal interlocking screws. In the latest version of the nail, there is also an end cap blocking the proximal screws (Fig. 1).

The placement of each single screw was assessed using an image intensifier in order to guarantee a correct reduction of the fracture along the various spatial planes.

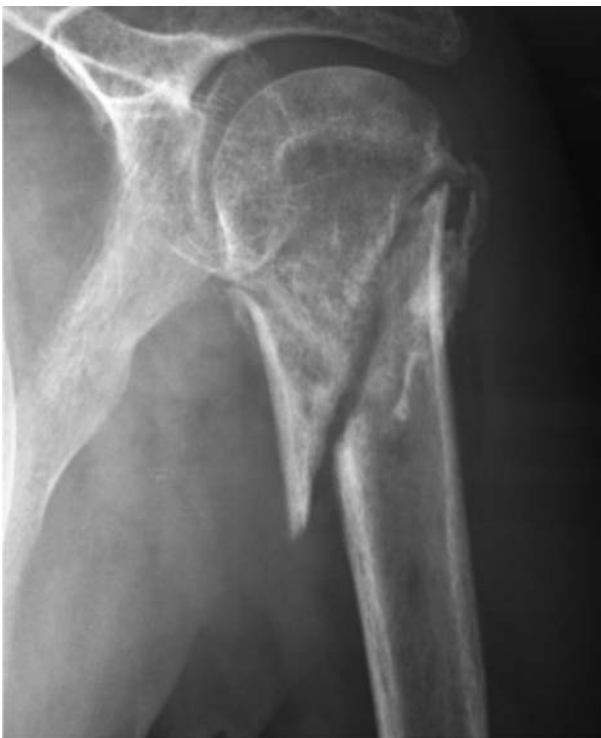Patients had a cast applied and an arm supporting sling for the first 3 weeks post-surgery; passive mobilisation of the elbow was started the day after surgery, whilst active and passive mobilisation of the shoulder was permitted only after 3 weeks.



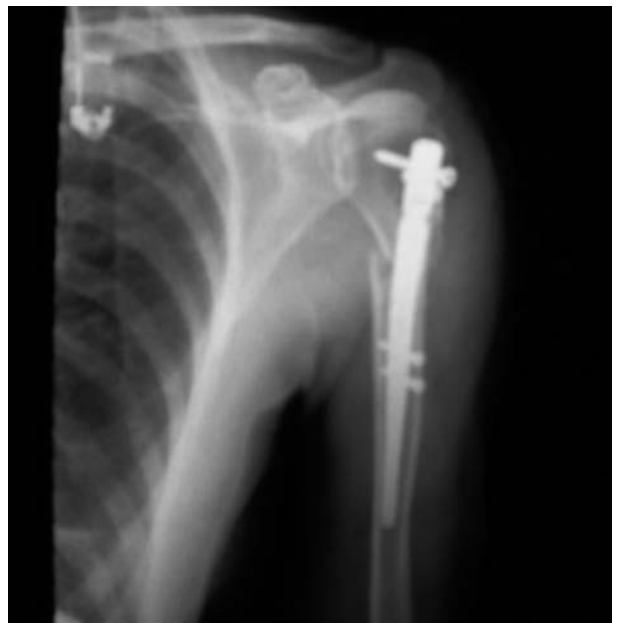**Figure 1.** Polarus Intramedullary nail



**Figure 3.** CT image of the fracture



**Figure 2.** A 2 fragment fracture of the humeral head-neck



**Figure 4.** Surgical synthesis of the fracture with a Polarus nail

## Results

Based on our clinical-instrumental assessment, we obtained 30% of excellent results (9 patients of which 7 classified Neer type II and 2 Neer type III) with almost complete recovery of everyday activities without pain and with a complete recovery of articulation and strength.

Good results were recorded in 43.3% of patients (13 patients of which 8 Neer type II and 5 Neer type III) with moderate pain at maximum level of active and passive movement and a slight reduction in strength.

In 13.3% of examined patients (4 patients, of which 1 with Neer type II and 3 with Neer type III) results were discreet with reduced articulation and pain.

Poor results were recorded in 13.3% of patients (4 patients of which 1 Neer type II and 3 Neer type III).

Complications were recorded in 6 patients, of which 2 were classified as type II and 4 as type III according to the Neer classification.

Deep infection was recorded in one case 7 months after surgery, classified as Neer II and diagnosed clinically and instrumentally (inflammation index and scintigraphy with positive leukocyte markers), and was probably of hematic origin due to concomitant dental abscess. Removal of synthesis devices and targeted antibiotic therapy led to complete resolution.

Two cases of significant pain upon active and passive mobilisation of the glenohumeral joint, due to lesions of the rotator cuffs and sub-acromial impingement, did not respond to physical therapies and rehabilitation. Also in these cases, removal of the intramedullary nail was necessary associated to a suture of the tendon lesion with acromioplasty with good final clinical-functional results.

Surgical removal of the proximal locking screws was necessary in three cases of "pull-out".

Neither neurological lesions nor vascular complications at the level of the humeral head were recorded (avascular necrosis).

Clinical and radiological data showed a stabilisation of the outcome one year after application of the device and maintained with a follow-up longer than 7 years good articulation and a completely efficient functionality.

## Discussion

In the literature, there is clinical evidence of excellent results for compound proximal humeral epiphyseal fractures treated in a conservative manner.

Gabler et al. carried out a study on 507 patients with a mean age of 63 years presenting fractures with minimum displacement of fragments. Excellent results were recorded in 87% of cases with a mean follow-up of 1 year (22).

Similar results were obtained by Koval et al. in the review of 104 patients with similar characteristics (23).

Universal surgical indication criteria is not available for fractures with 2 or more fragments as a single ideal surgical treatment technique for all fractures in all patients does not exist.

These indications must be extremely personalised, taking into account bone quality, fracture morphology, soft tissue lining and adopted techniques.

Analysing our results, it can be highlighted that for Neer-II-III type fractures, fracture synthesis using a Polarus intramedullary nail has enabled us to achieve 73.3% of good and excellent results. These results are in line with the literature where satisfactory results range between 75 and 80% (18, 24, 25).

A study by Lin and co-workers reviewing 21 patients presenting proximal humeral epiphyseal fractures treated with a Polarus intramedullary nail proposed, recorded excellent or satisfactory results in 78% of cases. (25).

Overlapping clinical results have been recorded also by Mouradian and co-workers, whose patients however had a lower mean age and in whom a modified Zickel nail was used for the synthesis of fractures (26).

Evaluation and comparison of results in the literature is extremely difficult due to the lack of homogeneity of the fractures and patients considered, and to the lack of a univocal interpretation of fracture classification and clinical scoring.

Pull-out of proximal screws is a complication reported in the literature with an incidence ranging from 4 to 20% (17,18, 24, 27). In our experience, we have had 3 cases representing 10% of our patients and 50% of recorded complications.

Koike and co-workers recorded a 7% incidence of proximal screw pull-out in their study, recommending

the use of bicortical screws for the second and third locking screw with the aim of increasing the stability of the device thus preventing this complication (28).

We agree with the author regarding the possibility of avoiding this complication with their proposed technique, however, we believe that the poor quality of the osteoporotic bone in patients above the age of 65 requires a greater stability of the device.

The mechanical evolution of these synthesis devices has partially contributed to overcoming this complication by closing the proximal locking screws as occurs with angular stable plaques, thus bypassing bone stability itself.

In fact, the aseptic mobilisation of the device and/or the loss of reduction of the reduced fractures are all common complications also of other synthesis devices proposed and used in the treatment of this fracture.

A broad and complete review of 791 cases of proximal humeral epiphyseal fractures treated with a plate and screws (PHILOS and LPHP) carried out by Thanasas and co-workers recorded a 12.2% incidence of synthesis failure with loss of reduction of the humeral head and subsequent varus collapse and a 2.6% incidence of pull-out of the head screws (29-33).

Examining this data and comparing it with our own data, we can affirm that the treatment of proximal humeral fractures in elderly osteoporotic patients is complicated by the reduced stability of synthesis devices in this site.

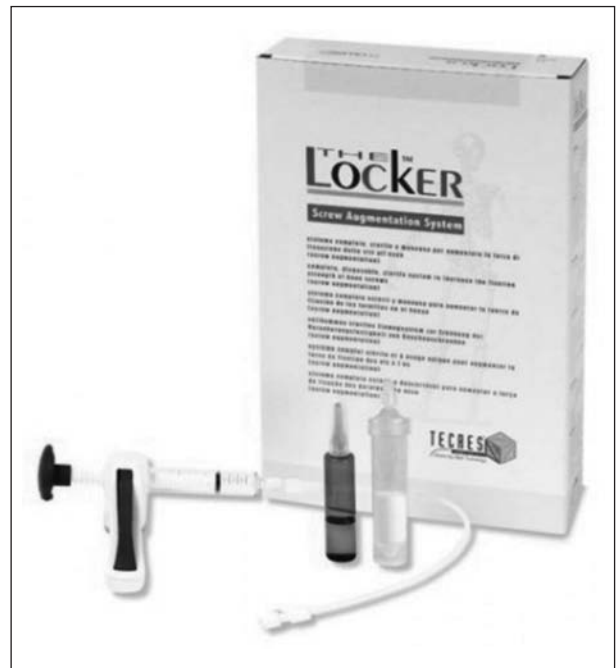Even when reductions are as anatomical as possible and devices are positioned correctly, not always is it possible to avoid complications.

Varus collapse of the humeral head is almost inevitable in fractures with 3 or more fragments even when dedicated screws are used.

In the literature, it is common belief that bone transplants or synthetic replacements are fundamental for the stability of the device notwithstanding a careful patient selection and careful surgical synthesis (12, 34).

In this sense, the augmentation technique that consists both in the cementation of the thread pitch of the proximal screws and the use of plates with intramedullary nails, could be a possible option (Fig. 5).

The objective is to increase the biomechanical stability of the implants, reducing complications due to



**Figure 5.** The Locker System for Augmentation

loss of reduction following mobilisation of the devices and length of immobilisation of the operated leg.

At the expense of higher surgery costs, we believe that it is important to significantly reduce the number of re-interventions due to cut-out and pull-out phenomena in order to have a better patient outcome and reduce health care costs.

The technique is simple and easily reproducible and we believe it is of fundamental help to the surgeon in the treatment of these and other fractures characterised by a severe degree of osteoporosis and instability (35).

## References

1. Kristiansen B, Barfod G, Bresden J, Erin-Madsen J, Grum B, Horsnaes MW, Aallberg JR. Epidemiology of proximal humeral fractures. *Acta Orthop Scand* 1987; 58 (1): 75-7.
2. Lind T, Kroner TK, Jensen J. The epidemiology of fractures of the proximal humerus. *Arch Orthop Trauma Surg* 1989; 108 (5): 285-7.
3. Jinn Lin. Effectiveness of locked nailing for displaced three-part proximal humeral fractures. *The journal of Trauma Injury, Infection, and critical care* 2006; 61: 363-74.
4. Robinson CM, Christie J. The two part proximal humeral fracture: a review of operative treatment using two techniques. *Injury* 1993; 24: 123-5.

5. Schippinger G, Szyszkowitz R, Seibert FJ. Current concepts in the treatment of proximal humeral fracture. *Curr Orthop* 1997; 292: 203-14.
6. Szyszkowitz R, Seggl W, Schleifer P, Cundy PJ. Proximal humeral fractures management: techniques and expected results. *Clin Orthop* 1993; 292: 13-25.
7. Chen AL, Joseph TN, Wolinsky PR, et al. Fixation stability of comminuted humeral shaft fracture: locked intramedullary nailing versus plate fixation. *J Trauma* 2002; 53 (84): 733-7.
8. Lin J, Shen PW, Hou SM. Complications of locked nailing in humeral shaft fractures. *J Trauma* 2003; 545 (5): 943-9.
9. Gandolfi M, Malavolta L, Tomasso A, Moretti F. La Fissazione elastica endomidollare nelle fratture diafisarie dell'omero. Attualità in traumatologia. Gaggi Bologna 1985.
10. Martin Henri Hessmann et al. Locked plate fixation and intramedullary nailing for proximal humerus fractures: a biomechanical evaluation. *J Trauma* 2005; 58: 1194-201.
11. Sara L. Edwards, MD, Nicole A. Wilson et al. Two part surgical neck fractures of the proximal part of the humerus. A biomechanical evaluation of two techniques. *J Bone Joint Surg* 2006; 88 A (10): 2258-64.
12. Thanasas C, Kontakis G, Angoules A, Limb D, Giannoudis P. Treatment of proximal humerus fractures with locking plates: a systematic review. *J Shoulder Elbow Surg* 2009;18: 837-44.
13. Zyto K, Wallace WA, Frostik SP, Preston BJ. Outcome after hemiarthroplasty for three and four part fractures of the proximal humerus. *J Shoulder Elbow Surg* 1998; 7 (2): 85- 9.
14. Goldman RT, Koval KJ, Cuomo F, Gallagher MA, Zuckerman JD. **Functional outcome after humeral head replacement for acute three and four part proximal humeral fractures.** *J Shoulder Elbow Surg* 1995; 4 (2): 81-6.
15. Molster A, Gjerdet NR, Strand RM, Hole RM, Hove LM. Intramedullary nailing shaft fractures. Mechanical behaviour in vitro after osteosynthesis with three different intramedullary nails. *Arch Orthop Trauma Surg* 2001; 121 (10):554-6.
16. Adedapo AO, Ikpeme JO. The results of internal fixation of three- and four-part proximal humeral fractures with the polarus nail. *Injury* 2001; 32 (2): 115-21.
17. Agel J, Jones CB, Sanzone AG, Camuso M, Henley MB. Treatment of proximal humeral fractures with Polarus nail fixation. *J Shoulder Elbow Surg* 2004; 13 (2): 191-5.
18. Rajasekhar C, Ray, Bhamra MS. Fixation of proximal humeral fractures with the Polarus nail. *J Shoulder Elbow Surg* 2001;10 (1): 7-10.
19. Kristiansen B, et al. The Neer classification of fractures of the proximal humerus: an assessment of inter-observer variation.
20. Siebenrock KA, Gerber C. The reproducibility of classification of fractures of the proximal end of the humerus. *J Bone Joint Surg* 1993; 75A: 1751-5.
21. Constant CR, Murley AHG. A clinical method of functional assessment of the shoulder. *Clin Orthop Rel Res* 1987; 214:160-4.
22. Gaebler C, McQueen M, Court-Brown C. Minimally displaced proximal humeral fractures: epidemiology and outcome in 507 cases. *Acta Orthop Scand* 2003; 74: 580-5.
23. Koval J, Gallagher MA, Marsicano JG, Cuomo F, MacShinawy A, Zuckerman JD. Functional out come after minimally displace fractures of the proximal part of the humerus. *J Bone Joint Surg (Am)* 1997; 79: 203-7.
24. Hirose J, Nomura K, Hirano M. Fixation and post-operative complications of proximal humeral fractures with a Polarus humeral nail. *Shoulder Joint* 2005; 29: 323-27.
25. Lin J. Effectiveness of locked nailing for displaced three-part proximal humeral fractures. *J Trauma* 2006; 61: 363- 74.
26. Mouradian WH. Displaced proximal humeral fractures: Seven years' experience with a modified Zickel supracondylar device. *Clin Orthop Rel Res* 1986; 212:209-18.
27. Inoue H, Sato K, Ito K, Inawashiro T. Internal fixation of proximal humeral fractures with a Polarus humeral nail. *Bessatsu Seikeigeka* 2003; 44: 23-27.
28. Koike Y, Komatsuda T, Sato K. Internal fixation of proximal humeral fractures with a polarus humeral nail. *J Orthopaed Traumatol* 2008; 9:135-39.
29. Charalambous CP, Siddique I, Valluripalli K et al. Proximal humeral internal locking system (PHILOS) for the treatment of proximal humeral fractures. *Arch Orthop Trauma Surg* 2007;127: 205-10.
30. Fankhauser F, Boldin C, Schippinger G, Haunschmid C, Szyszkowitz R. A new locking plate for unstable fractures of the proximal humerus. *Clin Orthop Relat Res* 2005; 430: 176-81.
31. Gardner MJ, Weil Y, Barker JU, Kelly BT, et al. **The importance of medial support in locked plated of proximal humerus fractures.** *J Orthop Trauma* 2007; 21: 185-91.
32. Lill H, Hepp P, Korner J, Kassi JP et al. Proximal humeral fractures: how stiff should an implant be? A comparative mechanical study with new implants in human specimens. *Arch Orthop Trauma Surg* 2003;123: 74-81.
33. Voigt C, Woltmann A, Partenheimer A, Lill H. Management of complications after angularly stable locking proximal humerus plate fixation. *Chirurg* 2007; 78: 40-6.
34. Krappinger D, Bizzotto N, Riedmann S, et al. Predicting failure after surgical fixation of proximal humerus fractures. *Injury* 2011; article in press.
35. Dall'Oca C, Maluta T, Moscolo A, Lavini F, Bartolozzi P. Cement Augmentation of intertrochanteric fractures stabilized with intramedullary nailing. *Injury* 2010; 41:1150-55.

Correspondence:

Indirizzo per la corrispondenza:

Dott. Carlo Dall'Oca

Dipartimento di Chirurgia

Clinica Ortopedica e Traumatologica

Università degli Studi di Verona

Policlinico G.B. Rossi P.le L. Scuro, 10 - 37134 Verona

Tel. 00390458124471

Fax 00390458027470

E-mail: carlo.dalloca@univr.it