

Results after revision of the stem in periprosthetic fractures of the hip

Francesco Pogliacomì, Tiziana Corsini, Matteo Zanelli, Alessandro Ditta, Massimo Pompili, Alessio Pedrazzini, Francesco Ceccarelli

Orthopaedic Clinic. Department of Surgical Sciences. University of Parma.

Summary. Periprosthetic femoral fractures following primary total hip arthroplasty (THA) represent an emerging challenge for the orthopaedic surgeon, because of their increasing incidence and negative impact on clinical and functional patient outcome. For these reasons, in the last decade, many efforts were made to prevent and manage this complication and a large number of studies were focused on finding out the best treatment. The type of treatment depends on several factors such as morphology and location of the fracture, implant stability, quality and quantity of bone stock, patient's age and clinical conditions. Fractures that cause loosening of the stem always require its revision, with a contextual assessment of the quality and quantity of remaining bone stock, which is generally good in type B2 and poor in type B3 according to Vancouver's classification. The latter may require the use of bone grafts. In this context, the authors performed the following study and analyzed the results of 45 patients treated surgically for periprosthetic femoral fractures with revision of the femoral stem during a fourteen years period, between June 1999 and June 2013.

Key words: hip, arthroplasty, revision, stem, aseptic mobilization, periprosthetic fracture.

Introduction

The treatment of periprosthetic fractures of the femur after THA is an emerging problem, both for the increase of the average life of the population, both for the enlargement of the surgical indications to hip replacement. Thanks to the new prosthetic materials and the improvement of surgical techniques, this surgery is now performed in elderly patients with poor bone quality and also in young patients who want to return to their preoperative performances, and therefore, are at higher risk to undergo a new trauma whose entity is sufficient to cause a periprosthetic fracture (1).

The increased incidence of these lesions also depends on the greater number of cases that require a revision surgery, where the bone quality is poorer and

the possibility to determine cortical defects during the removal of prosthetic components is increased.

The incidence of postoperative periprosthetic fracture is close to 2% in the first implants and rises up to 6-8% in revision surgery (2-5).

Postoperative risk factors may be divided in (4-6):

- general, such as osteoporosis, rheumatoid arthritis, Paget disease, age, female sex, increased time from index operation and neurological diseases that alter the walking pattern
- local, such as stem femoral mobilization, periprosthetic osteolysis or localized cortical defects.

Among the different classifications, that of "Vancouver" modified by Duncan and Masri in 1995 (7, 8), is the most complete and used and divides these lesions into type A, B and C (9) (Table 1) on the basis

of the level of the fracture, implant stability and bone quality. This classification also suggests a therapeutic algorithm in order to plan the treatment strategy.

The goals of treatment should aim to:

- restore the best possible anatomical alignment and length and reduction of the fracture
- obtain stability of the prosthetic implant and of the fracture
- begin an early mobilization of the patient
- ensure the return to a quality of life similar to that before the trauma.

The conservative treatment is nowadays less frequently used and is generally reserved for cases in which the general conditions of the patient cannot allow a safe surgery and in cases of type AG stable fractures (1,6). In types B and C the choice of the surgical technique depends essentially on the stability of the stem. Reduction and internal fixation is indicated if this prosthetic component is stable while revision is performed when it is mobilized.

The aim of this study was to analyze the results of revision surgery of the stem in type B2 and B3 periprosthetic fractures.

Material and methods

From June 1999 to June 2013, 70 patients were surgically treated for periprosthetic fractures of the femur with stem revision after primary THA at the Orthopaedic Clinic of the University of Parma. Forty-five of the 70 patients were evaluated, as 19 died and 6 were not available for the visit (Figure 1).

Intraoperative and fractures occurred in revision procedures were excluded from the study.

Table 1. Vancouver's classification.

Type A	Trochanteric fractures
AG	Greater trochanter
AL	Lesser trochanter
Type B	Fractures around the stem
B1	Stable stem and adequate "bone stock"
B2	Unstable stem and adequate "bone stock"
B3	Unstable stem and inadequate "bone stock"
Type C	Fractures distal to the apex of the stem

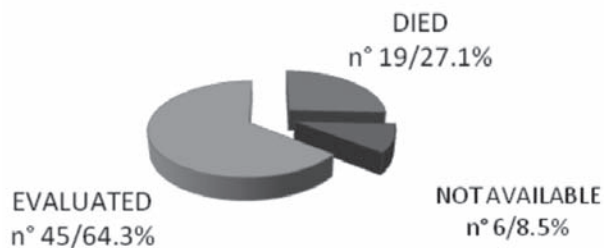


Figure 1. Patients affected by periprosthetic fractures from June 1999 to June 2013.

For each patient gender, age, type of prosthesis previously implanted (cemented or uncemented) and the time between first implant and fracture was assessed.

All patients underwent to functional evaluation using the Harris Hip Score (HHS), before surgery and at follow-up, and to radiographic assessment. Preoperative X-Rays were used in order to detect signs of pretraumatic mobilization and, consequently, to classify the fractures according to Vancouver (7, 8). Radiographs performed at follow-up were utilized in order to evaluate the positioning of the prosthetic components and to visualize signs of mobilization (radiolucent lines) in accordance respectively with Engh's or Harris criteria (10,11) for uncemented or cemented stems. The functional results before and at follow-up were compared and statistical analysis was elaborated using the SPSS software (20.0 version). The Mann-Whitney test was used to show differences between HHS in the affected leg before surgery and at follow-up. The difference was considered significant when p value was less than 0.05.

Results

The average age of the 45 patients at the time of fracture was 78.5 years (range 43-92); there were 12 males (26.7%) and 33 females (73.3%).

The periprosthetic fracture occurred after a mean interval of 6.8 years from the first operation (range 1-30) and there were 36 type B2 (80%) (Figure 2) and 9 type B3 (20%) (Figure 3) lesions. Thirty-five patients referred an efficient trauma while 10 reported a minor or no trauma. These last 10 cases referred, during col-

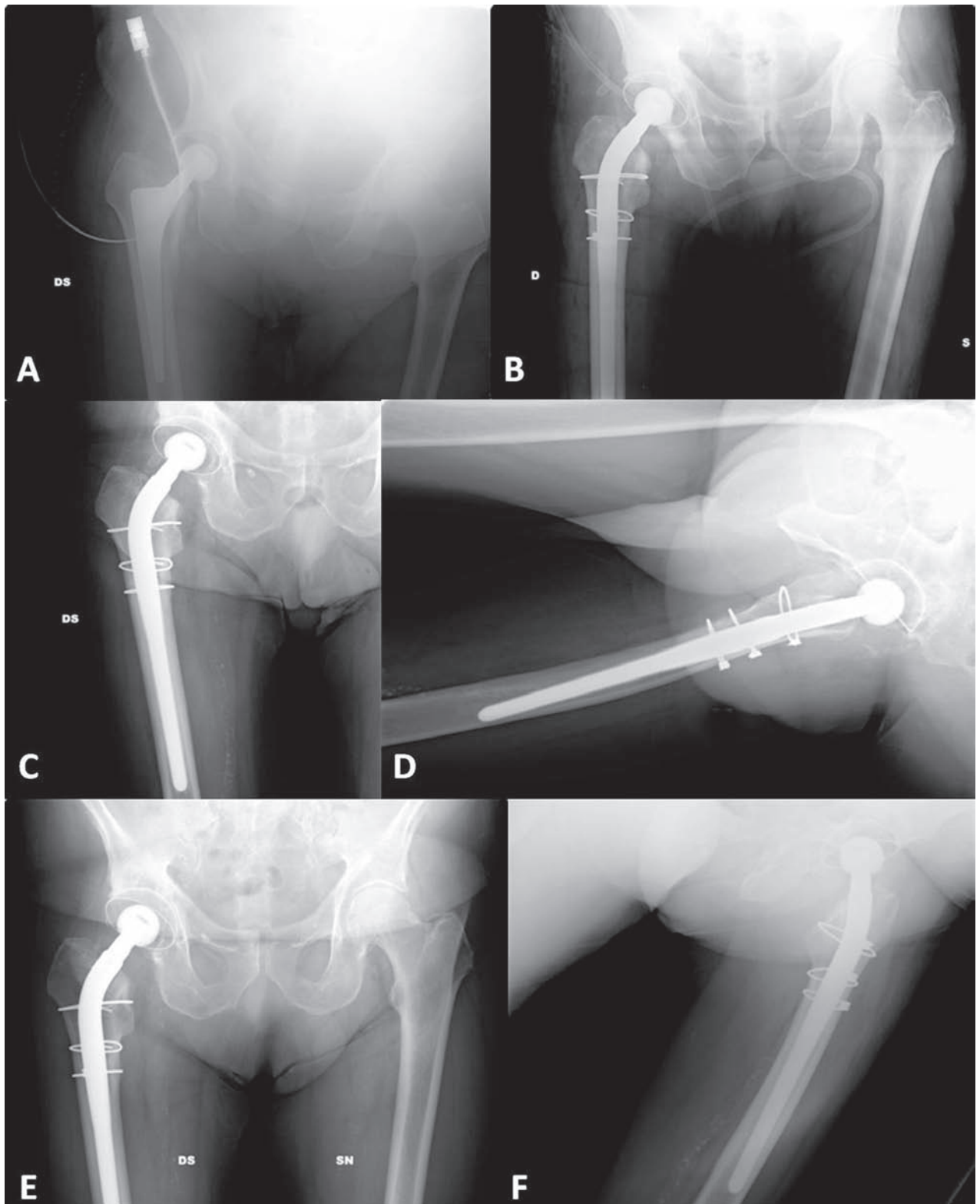


Figure 2. Type B2 right periprosthetic fracture. A; preoperative x-ray. B, C and D; postoperative x-ray after revision of the stem and positioning of 3 metallic cables. E and F; x-ray performed 12 months after revision with consolidation of the fracture.

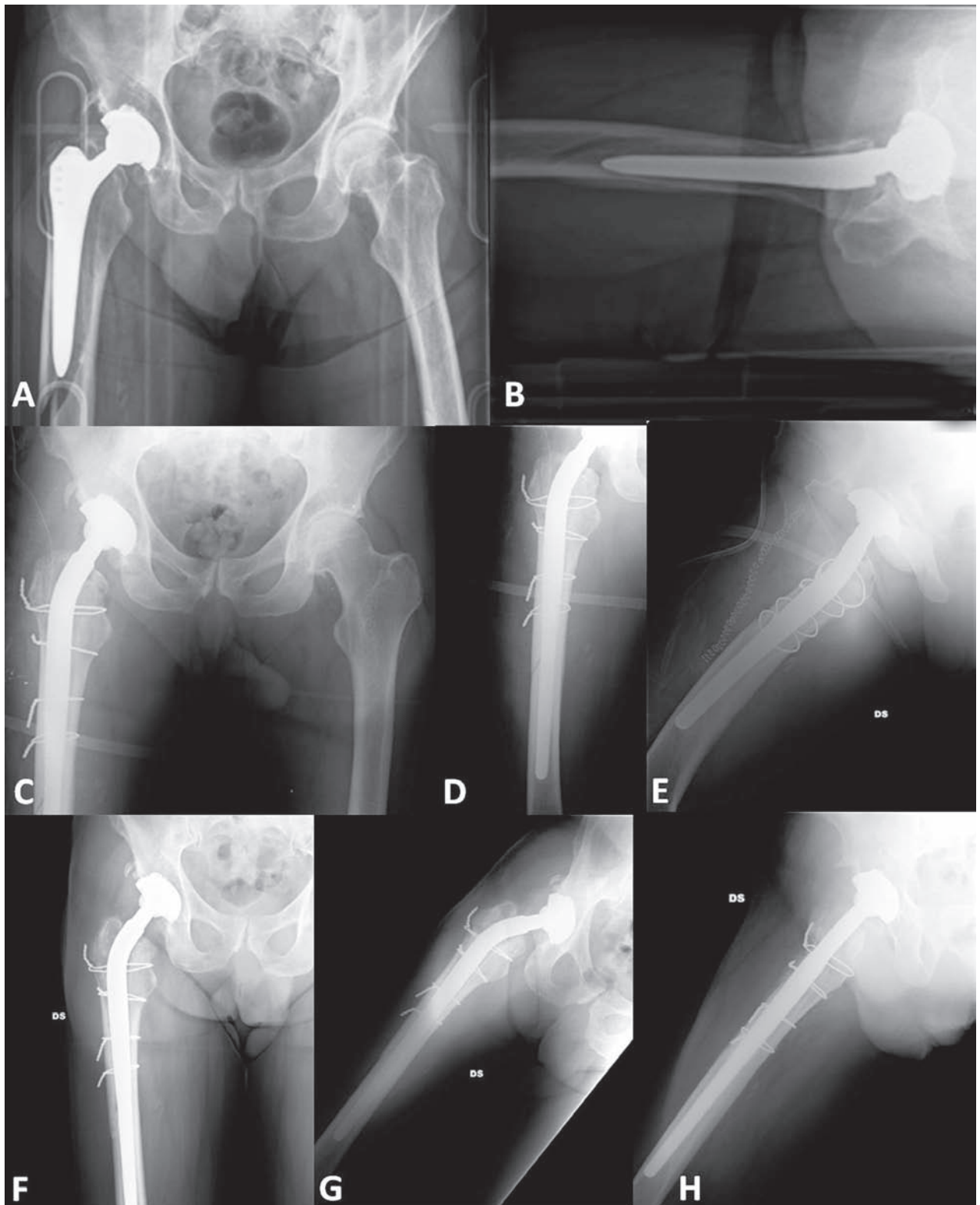


Figure 3. Type B3 right periprosthetic fracture. A and B; preoperative x-rays. C, D and E; postoperative x-ray after revision of the stem and positioning of 4 metallic cables. F, G and H; x-ray 24 months after trauma with fracture consolidated.

lection of anamnestic data, variable symptoms before fracture such as groin or thigh pain.

Primary replacements were uncemented in 44 cases (97.8%) and cemented in one.

The treatment always consisted in an intraoperative evaluation of the stem stability, the removal of the mobilized component and cement, and subsequent replacement with a long revision uncemented stem with distal anchorage of the prosthesis. In 37 cases the new stem implanted was monoblock and in 8 modular. In 3

cases, classified as B3, an autologous cortico-cancellous bone graft (Figure 4) was associated as consequence of severe bone loss of the femoral shaft. In 14 patients metallic cables have been applied and in one, the removal of the device was necessary as consequence of reactive osteolysis. In 5 type B3 fractures an additional fixation with plate and screws was used.

Nine fractures were preoperatively classified as type B1 and became B2 due to of their stem instability which was assessed during surgery (Figure 5).

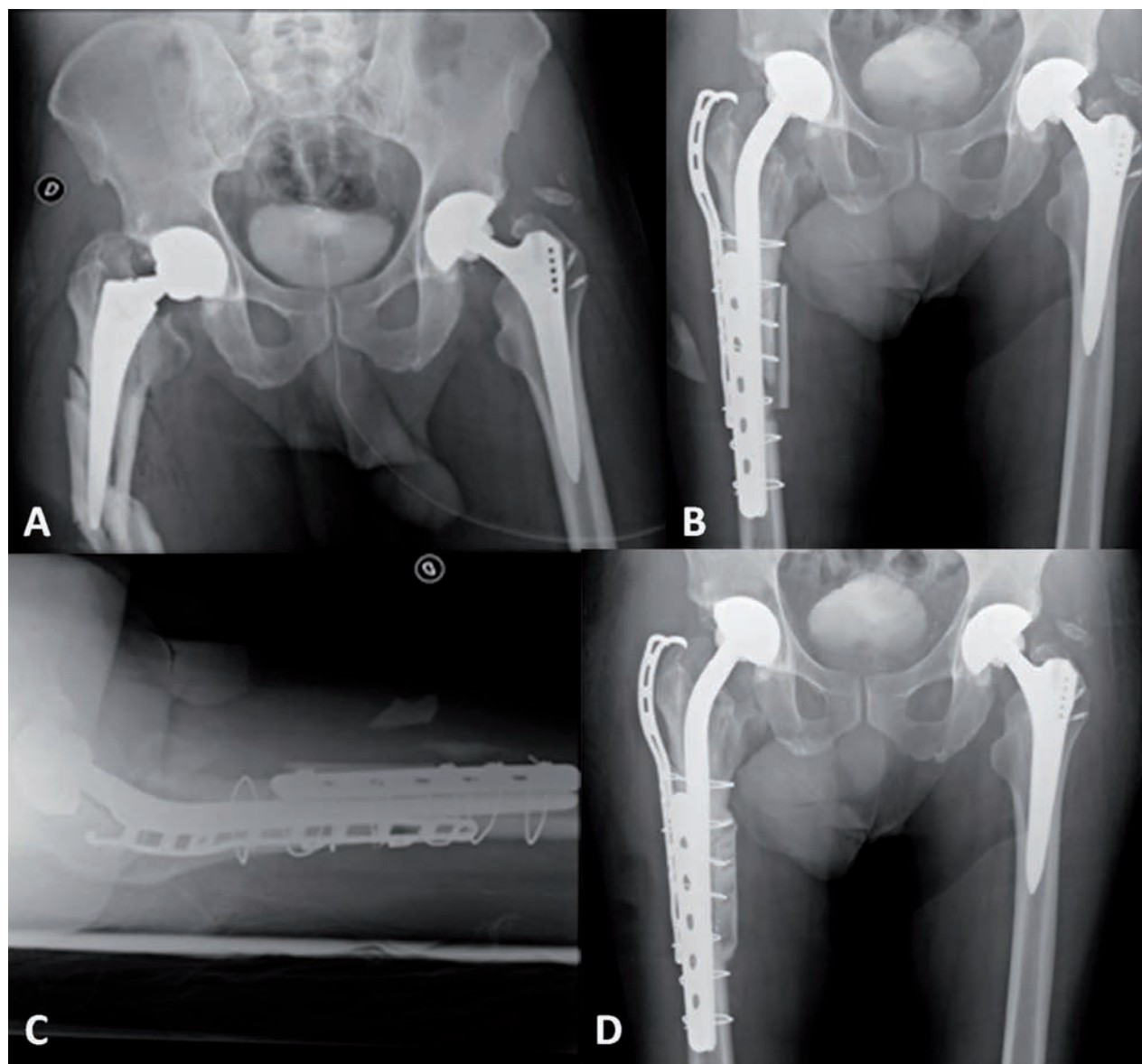


Figure 4. Type B3 right periprosthetic fracture. A; preoperative x-ray. B and C; postoperative x-ray after revision of the stem and positioning of plates, cables and autologous cortico-cancellous bone graft. D; x-ray 18 months after trauma with fracture consolidated.

The mean follow-up was 55 months (range 12-156).

The consolidation occurred in all cases in an average time of 4.5 months (range 3-8), and radiographs have always shown a complete osteointegration of the newly-stem without radiolucent lines; in 4 cases a shortening of more than 2 cm of the operated limb was observed.

The average HHS was 81/100 (range 59-100) before fracture and 80/100 (range 55-100) at follow-up without significant differences in the statistical analysis ($p < 0.05$).

Infections were never observed. One case, which was initially treated with monoblock stem, presented recurrent dislocations which needed revision surgery with a modular implant.

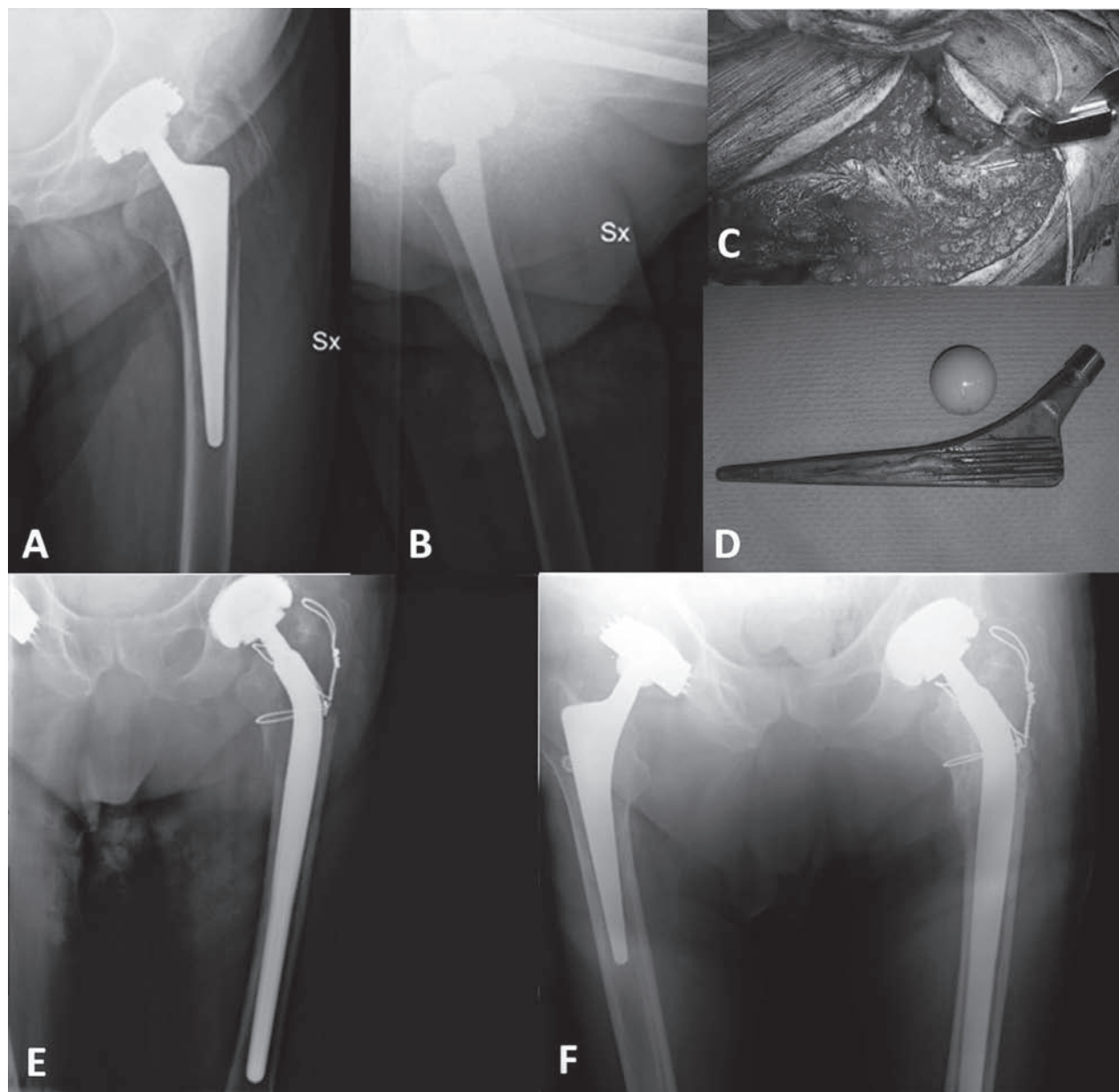


Figure 5. Left periprosthetic fracture which was initially treated as type B1. A and B; preoperative x-ray. C and D; intraoperative views which demonstrated stem instability. E; postoperative x-ray after revision of the stem and positioning of labels. F; x-ray 28 months after trauma with fracture consolidated.

Discussion

Horwitz and Lenobel (4) in 1954 first published a “case report” of periprosthetic intertrochanteric fracture.

Since then, the incidence of this complication has increased together with the increasing number of total hip arthroplasties and revisions.

The register of the Mayo Clinic (based on 23980 cases) (12) reported a periprosthetic fractures incidence of 1.1% after primary THA and of 4% after revision; this complication, whose incidence has progressively increased, is the third cause of failure of hip replacement, after aseptic loosening and recurrent dislocation (12-17).

Furthermore, Bhattacharyya showed one year after this type of injury a mortality near to 11% (18); this percentage increases in cases of delayed surgery and is higher when osteosynthesis is performed instead of revision (33% vs. 12%). This datum is confirmed in this study in which 19 patients were died at follow-up, and 7 out of 19 died within a year after trauma (15.6%).

Periprosthetic fractures are a challenge even for the most experienced orthopaedic surgeon and their therapy can be different. A precise preoperative history and classification may help to guide treatment and Vancouver's one is considered the most complete and useful.

Their treatment depends on several variables such as type of fracture, stability or instability of the prosthetic implant, bone quality and functional needs of the patient.

Good quality pelvic and femoral radiographs are necessary to evaluate the status of the femoral stem and bone stock, even if, very often, the implant is mobilized despite radiographs without signs of loosening (subsidence, cement mantle fractures and complete or progressive radiolucency at the bone-prosthesis or bone-cement interface).

This misdiagnosis of a stable stem can occur in up to 20 % of cases (6) and, in this study, also this datum is confirmed, as 9 out of 45 fractures, which were initially classified as type B1, became B2 after intraoperative stem stability test.

Pre-fracture symptoms, such as thigh or groin pain, may suggest that the femoral stem is loose but it has been demonstrated that the real stability of this component may be assessed only intraoperative (6,12-17).

Nevertheless, the authors suggest to carry out regular follow-up after all hip replacements procedures in order to identify cases at risk and eventually perform a “preventive” revision surgery.

Among the different therapeutical strategies conservative treatment is always more rarely performed and is generally indicated in type AG fracture in which the prosthesis is stable and in those patients in whom the general conditions cannot allow a safe surgery.

The surgical treatment is instead reserved for all other cases. When the prosthesis is stable (type B1 and C) reduction and osteosynthesis is recommended. The revision of the stem is instead indicated in periprosthetic fractures associated with mobilization of the stem more or less combined with loosening of the bone stock (type B2 and B3) (19).

In type B2 fractures several stems have been used over time. Revision cemented stems (20-23) have been associated with unsatisfactory long term results, and worse than those of uncemented, due to the higher incidence of nonunion, aseptic loosening, refractures and damages, by exothermic reaction during cementation, to neuro-vascular adjacent structures. Among the uncemented revision stems, the long ones with distal anchorage of the prosthesis had the best results, ensuring a good contact bone/prosthesis and excellent short and long-term axial and rotational stability of the implant and fracture (24-29), thus diminishing the need of bone grafts in type B3 lesions (30).

In this study, results of uncemented long stems with distal fixation of the prosthesis were always satisfactory and bone grafting was used only in 3 cases.

The authors, in order to obtain a valid distal diaphyseal fixation, recommend that the apex of the stem bridges the fracture's line of at least the double of the bicortical diameter of the femur at this level. This surgical step allows a 4 to 6 cm of intimate intramedullary cortical contact with the stem.

In this difficult surgery results can be influenced by various parameters such as the poor “bone stock”, the need to obtain an adequate positioning of the stem in order to achieve a good stability and the proper anteversion and leg length, thus preventing limping and recurrent dislocations (31).

The use of modular revision stems (32-34), can prevent these complications. In this case series a mod-

ular implant was used only in 8 patients and in the 4 cases, which developed leg shortening, a monoblock design was positioned.

There are also particular cases in which the prosthesis is unstable and the "bone stock" is so poor, in which the treatment with long stems with distal anchorage more or less associated with bone grafting is not feasible. In these cases the use of distally locked stems with screws (35) or even better composite prosthesis or megaprosthesis remains the only possible therapeutic solution (36-38).

Conclusion

Periprosthetic fractures are a major problem whose incidence is expected to increase. The use of a reliable and precise classification is essential for proper treatment planning, although this is not always feasible. For these fractures, treatment is influenced by several factors and its correct choice depends on type and level of the fracture, periprosthetic bone quality, stability of the previously implanted prosthesis, and age and general condition of the patient.

If a revision surgery is indicated, the use of uncemented long stems with distal anchorage of the prosthesis can manage the majority of the cases and is characterized by satisfactory results.

References

- Schwarzkopf R, Oni J, Marwin S.E. Total hip arthroplasty periprosthetic femoral fractures, a review of classification and current treatment. *Bulletin of the hospital for joint diseases*. 2013; 71(1): 68-78.
- Calvosa GB, Tenucci E, Morescalchi M, Po G. Le fratture periprotetice di femore dopo una protesi totale d'anca. *G.I.O.T.* 2004; 30: 100-4.
- Del Sasso L, Cavenago C, Bianchi G, Marchese M. Le fratture del femore nelle protesi d'anca. *G.I.O.T.* 2003; 29: 57-66.
- Lindahl H. Epidemiology of periprosthetic femur fracture around a total hip arthroplasty. *Injury*. 2007; 38(6): 651-4.
- Franklin J, Malchau H. Risk factors for periprosthetic femoral fracture. *Injury*. 2007; 38(6): 655-60.
- Marsland D, Mears S. A review of periprosthetic femoral fractures associated with total hip arthroplasty. *Geriatric Orthopaedic Surgery & Rehabilitation* 2012; (3)3: 107-20
- Duncan CP, Masri BA. Fractures of the femur after hip replacement. *Instr Course Lect.* 1995; 44: 293-304.
- Masri BA, Meek RM, Duncan CP. Periprosthetic fractures evaluation and treatment. *Clin Orthop Relat Res.* 2004(420): 80-95.
- Ninan T.M., Costa M.L., Krikler S.J. Classification of femoral periprosthetic fractures. *Injury*. 2007; 38, 661-8.
- Engh CA, Massin P, Suthers KE. Roentgenographic assessment of the biologic fixation of porous-surfaced femoral components. *Clin Orthop Relat Res.* 1990 Aug; (257): 107-28.
- Harris WH, McCarthy JC Jr, O'Neill DA. Femoral component loosening using contemporary techniques of femoral cement fixation. *J Bone Joint Surg Am.* 1982 Sep; 64(7): 1063-7.
- Berry DJ. Epidemiology: hip and knee. *Orthop Clin North Am.* 1999; 30(2): 183-90.
- Lindahl H, Garellick G, Regner H, Herberts P, Malchau H. Three hundred and twenty-one periprosthetic femoral fractures. *J Bone Joint Surg Am.* 2006; 88(6): 1215-22.
- Lindahl H, Malchau H, Herberts P, Garellick G. Periprosthetic femoral fractures classification and demographics of 1049 periprosthetic femoral fractures from the Swedish National Hip Arthroplasty Register. *J Arthroplasty.* 2005; 20(7): 857-65.
- Malchau H, Herberts P, Eisler T, Garellick G, Soderman P. The Swedish Total Hip Replacement Register. *J Bone Joint Surg Am.* 2002; 84-A(Suppl 2): 2-20.
- Malchau H, Herberts P, Ahnfelt L. Prognosis of total hip replacement in Sweden. Follow-up of 92,675 operations performed 1978-1990. *Acta Orthop Scand.* 1993; 64(5): 497-506.
- Tsiridis E, Haddad FS, Gie GA. The management of periprosthetic femoral fractures around hip replacements. *Injury*. 2003; 34(2): 95-105.
- Bhattacharyya T, Chang D, Meigs JB, Estok DM, 2nd, Malchau H. Mortality after periprosthetic fracture of the femur. *J Bone Joint Surg Am.* 2007; 89(12): 2658-62.
- Korbel M, Sponer P, Kucera T, Procazka E, Procek T. Results Of Treatment Of Periprosthetic Femoral Fractures After Total Hip Arthroplasty. *ACTA MEDICA (Hradec Králové)*. 2013; 56(2): 67-72
- Beals RK, Tower SS. Periprosthetic fractures of the femur. An analysis of 93 fractures. *Clin Orthop Relat Res.* 1996(327): 238-46.
- Zaki SH, Sadiq S, Purbach B, Wroblewski BM. Periprosthetic femoral fractures treated with a modular distally cemented stem. *Journal of Orthopaedic Surgery.* 2007; 15(2): 163-6.
- Holley K, Zelken J, Padgett D, Chimento G, Yun A, Buly R. Periprosthetic fractures of the femur after hip arthroplasty: an analysis of 99 patients. *Hss J.* 2007; 3(2): 190-7.
- Davidson D, Pike J, Garbuz D, Duncan CP, Masri BA. Intraoperative Periprosthetic Fractures During Total Hip Arthroplasty. Evaluation and Management. *J Bone Joint*

- Surg Am. 2008;90(9):2000-12.
24. Springer BD, Berry DJ, Lewallen DG. Treatment of periprosthetic femoral fractures following total hip arthroplasty with femoral component revision. *J Bone Joint Surg Am.* 2003;85-A(11):2156-62.
 25. MacDonald SJ, Paprosky WG, Jablonsky WS, Magnus RG. Periprosthetic femoral fractures treated with a long-stem cementless component. *J Arthroplasty.* 2001;16:379-83.
 26. Moran MC. Treatment of periprosthetic fractures around total hip arthroplasty with an extensively coated femoral component. *J Arthroplasty.* 1996; 11: 981-8.
 27. Ko PS, Lam JJ, Tio MK, Lee OB, Ip FK. Distal fixation with Wagner revision stem in treating Vancouver type B2 periprosthetic femur fractures in geriatric patients. *J Arthroplasty.* 2003; 18(4): 446-52.
 28. Isacson J, Stark A, Wallensten R. The Wagner revision prosthesis consistently restores femoral bone structure. *International Orthopaedics.* 2000; 24: 139-42.
 29. Gutierrez Del Alamo J, Garcia-Cimbreló E, Castellanos V, Gil-Garay E. Radiographic bone regeneration and clinical outcome with the Wagner SL revision stem: a 5-year to 12-year follow-up study. *J Arthroplasty.* 2007; 22(4): 515-24.
 30. Tsiridis E, Spence G, Gamie Z, El Masry MA, Giannoudis PV. Grafting for periprosthetic femoral fractures: strut, impaction or femoral replacement. *Injury.* 2007; 38(6): 688-97.
 31. Leonidou A, Moazen M, Skrzypiec DM, Graham S, Pargalos J, Tsiridis E. Evaluation of fracture topography and bone quality in periprosthetic femoral fractures: A preliminary radiographic study of consecutive clinical data. *Injury* 2013; 44: 1799-804
 32. Berry DJ. Treatment of Vancouver B3 periprosthetic femur fractures with a fluted tapered stem. *Clin Orthop Relat Res.* 2003; 417: 224-31.
 33. Mulay S, Hassan T, Birtwistle S, Power R. Management of types B2 and B3 femoral periprosthetic fractures by a tapered, fluted, and distally fixed stem. *J Arthroplasty.* 2005; 20: 751-6.
 34. Fawzy E, De Steiger R, Gundle R, McLardy-Smith P, Murray DW. The management of periprosthetic fractures of the oxford trimodular femoral stem: a survivorship study. *J Arthroplasty.* 2008; 24(6): 909-13.
 35. Eingartner C, Volkmann R, Pütz M, Weller S. Uncemented revision stem for biological osteosynthesis in periprosthetic femoral fractures. *International orthopaedics.* Springer-Verlag 1997; 21: 25-9.
 36. Kellett CF, Boscainos PJ, Maury AC, Pressman A, Cayen B, Zalzal P, et al. Proximal femoral allograft treatment of Vancouver type-B3 periprosthetic femoral fractures after total hip arthroplasty. Surgical technique. *J Bone Joint Surg Am.* 2007; 89(Suppl 2 Pt.1): 68-79.
 37. Maury AC, Pressman A, Barry C, Zalzal P, Backstein D, Gross A. Proximal femoral allograft treatment of Vancouver type B-3 periprosthetic femoral fractures after total hip arthroplasty. *J Bone Joint Surg Am.* 2006; 88: 953-8.
 38. Siegmeth A, Garbuz DS, Masri BA. Salvage procedures and implant selection for periprosthetic femoral fractures. *Injury.* 2007;38(6):698-703.

Received: 23 May 2014

Accepted: 2 June 2014

Correspondence: Francesco Pogliacomì, MD
Orthopaedic Clinic, Department of Surgical Sciences,

University of Parma.

Via Gramsci 14, 43126 Parma (Italia).

E-mail: fpogliacomì@yahoo.com