

C A S E R E P O R T

Open surgical revision of radial nerve after humeral fracture in polytrauma

S. Bernobi, G. De Fabrizio, M. Vuga, R. Valentini

Clinica Ortopedica e Traumatologica, Università degli Studi di Trieste, Azienda Ospedaliera Universitaria "Ospedali Riuniti" di Trieste

Abstract. *Aim of the study:* The injury of the radial nerve is not uncommon in humeral shaft fractures. These lesions may be of different types and levels and their treatment changes depending on traumatic characteristic. The authors present a case report of a patient affected by a closed shaft humeral fracture, consequence of an high energy trauma, associated with motor palsy of the radial nerve in which an open surgical revision was performed. The nerve appeared medially displaced and entrapped within the fracture fragments and the fibrous tissue around the lesion and showed signs of posttraumatic suffering without disruption. The nerve was repositioned in its anatomical site after neurolysis and intramedullary nailing of the humeral fracture. The fracture healed after 4 months with full recovery of motor function of the radial nerve. We believe that, in shaft fractures of the humerus with radial nerve deficits, it is imperative to perform surgical exploration of the conditions of the radial nerve itself, in order to obtain a recovery of its functionality. (www.actabiomedica.it)

Key words: humerus, radial nerve, fracture, politrauma

Introduction

In fractures of the humerus is common a radial nerve damage. These lesions may be of different types and levels and their treatment is different according to several factors (1, 2). The high-energy trauma and the distinction between exposed and non-exposed fractures have an important role in the management and treatment (3) of the radial nerve palsy. Some studies have demonstrated that the spontaneous functional recovery is better in non-exposed fractures compared to exposed ones (4). In our case, we performed a revision of the radial nerve after a high-energy, not exposed fracture decomposed with a "butterfly fragment" at the middle part of the right humerus. The radial nerve, medially displaced through the stumps of fracture and trapped in fibrous tissue, clinically showed a mainly motor suffering. The surgical revision, performed also relying on results of the studies (5), showed a suffering

of the radial nerve, which was, then, treated with neurolysis and repositioning of the same in its anatomical site.

Clinical Case

The patient, a 65 years old woman 65, came at First Aid on 15/06/2011 for multiple injuries trauma by precipitation with several fractures and initially she was treated by colleagues of resuscitation department. The standard radiographic examination showed: a comminuted fracture of the proximal burst of the right tibia, a fracture of the proximal epiphysis of the right fibula, a fracture of the proximal end of the shaft of the right fibula, an exposed and displaced fracture of the distal end of the shaft and of metaphysis of the left femur, a fracture with third butterfly fragment of the middle third of the diaphysis of the right humerus,

a fracture of the head of the second, third and fourth metatarsal, a fracture of the shaft of the proximal end of the phalanx and the second and third finger of right foot. The CT examination showed the following: "... important PNx with atelectasis of the right middle lobe and thickening of the lung parenchyma in the sloping at right lobe. Fracture of II, III, IV, V, VI and VII costal front right arch, displaced fracture of the eleventh left rear costal arch, burst fracture of the body of L4 with the rear fragment that protrudes into the vertebral channel". Having stabilized the condition of the patient were requested the advices of the surgeon and vascular, orthopedic and neurosurgeon specialists.

The same day the patient is brought to surgery room for orthopedic surgery of the lower limbs and right humerus. The right lower limb is stabilized with external fixation in tibiofemoral bridge, some fragments of the tibia are stabilized with Kirschner wires.

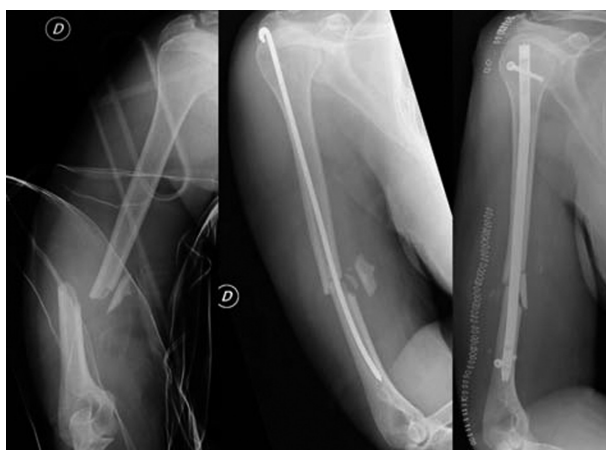

Figure 1. Fracture of the middle third of the humerus in the left picture, in the middle picture urgent stabilization with intramedullary Rush nail, in the picture on the right the stabilization with locked intramedullary nail during the simultaneous revisi

The left lower limb is stabilized with an external fixator in bridge. In this way were restored axis and length to the two lower limbs. At right upper limb is made temporary osteosynthesis with nail Rush. The same day the patient is treated also by colleagues from plastic surgery for a wound cutting the frontal region. In the days after the first surgery are constantly evaluated vital signs of the patient. Since the general conditions are not optimal, a neurosurgical intervention was referred several times. On 22/06/2011 it was purposed the decompression surgery and bilateral transpedicular fixation at L3-L5 segment. Vital signs and routine laboratory tests are checked daily to monitor the condition of the patient, which undergoes a slow and progressive improvement. On 24/06/2011 the patient is transferred to Department of Orthopedic Clinic. On 05/07/2011 the patient undergoes to the second major orthopedic surgery, which consists in removing the external fixator at the level of the lower left limb and osteosynthesis with Liss plate for multifragment displaced supracondylar fracture at left femur. The subsequent radiographic and physical-chemical tests show a gradual recovery of the general conditions of the patient, which presents itself cooperating and active. Clinically, the left leg has a good passive mobilization with the help of physiotherapist, while the right leg has yet the external fixator. Is obtained a good mobility of the right ankle and of the toes of the right foot. At the level of the right upper limb, immobilized with the type Desault tutor, any days after first intervention of osteosynthesis, the patient has a strength deficit in flexion-extension of the hand and of fingers probably due to damage of the radial nerve following the fracture of the middle third of right humerus. To the patient is applied a wrist tutor to be held during the night and during the day and to be removed in order to

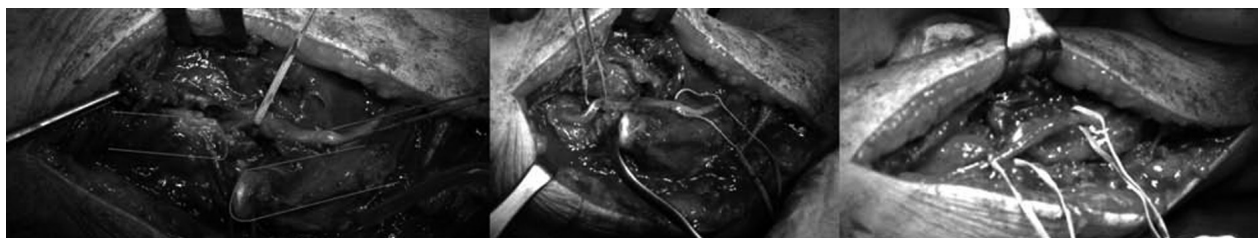


Figure 2. Intraoperative picture: on the left the isolation of dislocated radial nerve, neurolysis in the center and repositioning on the right picture

perform prudent mobilisations of the wrist and fingers. At 29 days after surgery is performed electromyography and electroneurography of right upper limb. The report reveals a serious nerve injury radial. It was decided to perform revision surgery of the radial nerve and stabilization of the right humerus fracture with an intramedullary nail.

On 15/07/2011 the surgery is performed with lateral surgical access to the middle-distal third of right humerus, having a cut length of 15 centimeters. Proceeding plan by plan, is identified and isolated the radial nerve, which looks intact and continuous. For a more careful observation is noticed the trapping of same nerve into fibro-callosum tissue and its medial location to the fracture site. It is released the nerve by strong fibrous adhesions and relocating the radial nerve in the torsion space of the radial nerve opening temporarily the fracture. The diaphyseal humeral fracture is then reduced and stabilized with an intramedullary nail. After the intervention was prescribed neurotrophic therapy and 4 months after the trauma, improvements and clinical signs of recovery of radial nerve function can be noted, also instrumentally highlighted.

Conclusions

Several authors have reported the effectiveness of the exploration and revision of the radial nerve injured after a fracture of the humerus (6). In this case it was not possible to perform the audit of the radial nerve in urgent need, because of seriously bad clinical conditions of the patient. The second surgery done in stabilized clinical conditions has led to perform the inspection, the release and repositioning of the radial nerve displaced after the precipitation trauma and fracture of the humerus. Currently, the clinical is much improved as well functional recovery of the radial nerve. Being known that the neural structures after being damaged require a slow recovery, and comforted from the dif-

ferent experiences reported in the literature (7) we are carefully optimistic about the complete functional recovery of the injured radial nerve. Despite often in these cases is given a full recovery of the radial nerve without surgical intervention, we believe that, in the diaphyseal fractures of humerus with radial nerve deficits, surgical revision of compromised nerve should be a therapeutic option to be taken into consideration since functional satisfactory results.

References

1. De Franco MJ, Lawton JN. Radial Nerve Injuries Associated With Humeral Fractures; *The Journal of Hand Surgery* 2006; 31A(4).
2. Ring D, Chin K, Jupiter JB, MD. Radial nerve palsy associated with high-energy humeral shaft fractures. *The Journal of Hand Surgery* 2004; 29A(1).
3. Venouziou AI, Dailiana ZH, Varitimidis SE, Hantes ME, Gougoulas NK, Malizos KN. Radial nerve palsy associated with humeral shaft fracture. Is the energy of trauma a prognostic factor? *Injury Int J Care Injured*, 2011.
4. Ekholm R, Ponzer S, Tornkvist H, Adami J, Tidermark J. Primary radial nerve palsy in patients with acute humeral shaft fractures. *J Orthop Trauma* 2008; 22 (6).
5. Bishop J, Ring D. Management of radial nerve palsy associated with humeral shaft fracture: a decision analysis model. *JHS* 2009; 34A.
6. Noaman H, Khalifa AR, El-Deen MA, Shiha A. Early surgical exploration of radial nerve injury associated with fracture shaft humerus. *Microsurgery* 2008; 28 (8): 635-42.
7. Pollock FH, Drake D, Bovill EG, Day L, Trafton P.G. Treatment of Radial Neuropathy Associated with Fractures of the Humerus. *The Journal of Bone and Joint Surgery* 1981; 63-A (2).

Correspondence:

Roberto Valentini

Clinica Ortopedica e Traumatologica

Università degli Studi di Trieste

Azienda Ospedaliero Universitaria "Ospedali Riuniti" di Trieste

Tel +390403994054

E-mail: rvalentini@units.it