

Distal radius fractures: surgical treatment with internal fixation

R. Valentini, G. De Fabrizio, G. Piovan, S. Bolcic, S. Bernobi, G. Fancellu

Clinica Ortopedica e Traumatologica, Università degli Studi di Trieste

Abstract. *Aim of the study:* to evaluate the efficacy of plates and screws with angular stability in osteosynthesis of fractures of the distal radius. *Materials and methods:* we analyzed 52 patients undergone surgery for fracture of the distal radius at the Clinica Ortopedica dell'Università di Trieste; in half of the patients osteosynthesis was provided using Synthes' LCP plates, in the other half we utilized a multidirectional and angular stable plate ("Aptus Radius" by Medartis). Mean follow-up was 28 ± 10 months, patients were evaluated with DASH score (disability of arm shoulder and hand) and the modified Gartland Werley score. *Results:* there were no significant differences between the two groups in terms of joint function, motility, volar and radial mean inclination. *Conclusions:* based on clinical and radiological results using angular stability plates must be considered as the method of election in the treatment of fractures of the distal epiphysis of the radius; in particular, thanks to the broader technical capabilities that they allow, are particularly indicated in unstable fractures. (www.actabiomedica.it)

Key words: wrist, distal radius, fracture, internal fixation

Introduction

Wrist fractures represent one of the most frequent traumatic injuries that come to the observation orthopedists. Mostly affect women over 75 years old secondary to low-energy trauma, while more rare observation in young people, in which generally occur after high-energy trauma. It is well known that the distal epiphysis of the radius represents a region

very frequently affected by phenomena of bone reabsorption related to related to post-menopausal osteoporosis; it has been demonstrated the presence of a decreased bone density in 85% of women who incur in a fracture of the wrist and frank osteoporosis in 51%. The relative risk that a woman may suffer a fracture of the distal forearm was estimated in about 6% at age 80 and 9% at the age of 90 years (1-3).

Due to the gradual increase in the average of the population, which today leads an active life performing

various recreational sports and frequent outputs from their familiar context, the incidence of this lesion is likely to increase progressively. The orthopedic surgeon can choose among a wide range of possible therapeutic strategies in front of a wrist fracture; the same techniques include closed reduction, stabilization and plaster fixation and external or internal techniques.

Still today one of the more frequently used treatments for fractures of the distal radius is conservative, i.e. the reduction for external operations and the subsequent application of a plaster cast; however, if on one hand this type of therapeutic approach can be economical and devoid of common surgical complications, the results it produces are not always optimal, hesitating frequently in losses of reduction, deformity, stiffness with fibrosis by prolonged immobilization, functional limitations, very important algo-dystrophic syndromes and sometimes difficult to be solved.

In recent years, also in function of the high functional and aesthetic needs that patients have developed, more and more often is preferred to adopt a type of surgical treatment, in order to obtain anatomical reduction of the fragments, a stable summary, lower risk of developing immediate complications as joint stiffness and long-term complications as the secondary arthritic changes. Is true in this sense the saying that “the more stable is the reduction before and the more you will be able to mobilize the wrist “. But in addition to stability of the outbreak is very important to restore normal angular measurements of the radius; Already in 1951 Gartland and Werley reported that the restoration of the inclination about 11° inclination and radial 23° are important for a good functional recovery of the radio-carpal joint (4, 5).

Another study found that grip strength, range of movement and ability to perform normal daily activities were significantly worse in patients with dorsal angle $>12^\circ$ respect to those with dorsal angle $<10^\circ$ (6). Consequently the results of distal radial fractures treated non-operatively or by surgery are related to the stability radio-carpal and to carpal and radio-ulnar distal kinematics (7). Over the past twenty years we have seen the development of real surgical techniques for the reduction and for the synthesis of this type of fracture, such as external fixers dedicated and intramedullary positioned fixation with percutaneous technique. More recently it has widespread the use of a Opened surgical technique of Reduction and Internal Fixation (O.R.I.F.) with the aim of reconstruct the congruity of the articular surface and restore the right length of the radius, the inclination and the palmar tilt and thus allow an earlier mobilization (8). This type of procedure is also indicated in unstable fractures or those displaced extra and intra-articular of distal radius in adult for which it is necessary an accurate reconstruction of the articular cartilage surface and the reduction of each unstable bone fragment in (of) the fracture. Until a few years ago in backbone decomposition fractures of the wrist, was used a dorsal approach for the positioning of the osteosynthesis plate because it was mechanically more logical to check bone fragments and the fracture itself. For treatment of wrist fractures with an anterior dislocation fragment was used instead a system of osteosynthesis plates positioned in the front; front and

dorsal decomposition fractures needed then the association of a volar plate and a dorsal one, with the requirement of a double surgical access. The dorsal approach, as reflected in the literature, is more frequently cause of complications: although, in fact, reported results are satisfying, can be often observed complications such as loss of fracture reduction and extensors tendon lesions, very close to the means of synthesis, requiring reoperations and sometimes with final results not that much satisfying. The volar approach allows the covering of plate by the pronator quadratus muscle, the flexor tendons don't fit closely to the volar surface of the radius and therefore the positioning of plaque in this position does not determine any adhesion problems or iatrogenic injuries. The volar approach, even in fractures with backbone decomposition, has become possible thanks to the advent of plates with angular stability, which represent a sort of internal fixator such as to guarantee the stabilization of bone fragments making them integral with each them and the plate; new implants allow sufficient stability even if the means of synthesis is positioned on the opposite side to the decomposition (9, 10). A further technical improvement of angular stability plaques has been the production of plaques to associate with screws with angular stability that can be inserted into the hole without a predefined direction, but variable; with this option you do not have to work taking into account the shape and angle of the holes in the plate but you are free to choose the best angle to get the optimal tightness of the screw in the free fragment to be synthesized. Many are today technical solutions of the coupling screw-hole to guarantee however the variability of angular insertion of the screw into the hole. The goal is always to get a stable fixation after the best possible anatomical reduction to allow immediate mobilization and optimal recovery of the activities of daily living and sports activity; the results that can be read in the literature on the use of these new methods of synthesis are exciting, with functional recovery almost complete and the incidence of complications between 0% and 10% (11-13). It is important to remember the case of our patient that 30 days after surgery had begun, with our surprise, the sport of amateur cycling.

For these reasons, we aimed to perform the fixation of fractures of the distal radius across the volar access using two different types of plate that ensured

the advantages of angular stability by minimizing the possibility of mobilizing and expanding indications even in cases of severe comminution or osteoporosis.

In our department we have begun to make fixation with the dorsal and the volar plate over five years ago, thinking that the internal fixation there could have given a better result both from the point of view of the quality of the reduction and from clinical side with a simple login procedure with the use of stable angular plaques.

Aim of the study

The purpose of this study is to evaluate the results of osteosynthesis in fractures of the distal radio through the volar access with angular stability plates and screws, to test the clinical results of internal osteosynthesis obtained through two types of plates: the classic Synthes LCP with fixed holes and the Aptus Radius (Medartis) with different angle holes, both produced in titanium.

Material and Methods

In the period between January 2005 and December 2010 at the Orthopaedic Clinic of the University of Trieste we treated, with volar plates, 52 fractures of the joint of the wrist, type A, B and C, about the AO classification. Patients included in the study were 36 women and 16 men with an average age of 58 years (minimum of 22 years and maximum 82 years). The mean follow-up was 10 ± 28 months (minimum 5 months, maximum 39 months). Twenty-five patients were pensioners, four merchants, six housewives, nine workers, five employees, one doctor and two students. The methods of trauma were: 34 incidental drops, 6 falls from ladders, 12 falls from the bike or bicycle. The fractures were classified by the AO classification system and we reported 10 fractures in Group A (3 in 2.2, 4 in 3.2 and 3 in 3.3), 15 fractures in Group B (4 in 1.2, 5 in 2.2 and 6 in 3.3) and 27 fractures in Group C (3 in 1.1, 6 in 1.2, 8 in 1.3; 4 in 3.2 and 6 in 3.3). The surgery was performed after a mean of 3.4 days after trauma. In 26 patients we used a plaque with

angular stability and fixed holes produced by Synthes, and in other 26 patients palmar plate with multidirectional holes and variable angle, of system Aptus® Radius 2.5 (Medartis) that allows the application of the screws with multi-angle of 15° with variability in all directions. This technical solution allows to be able to search for the stabilization of fragments that otherwise could not be recovered from our screw if the hole was with fixed angle. The surgical exposure of the fracture was performed through a volar incision, according to the “Henry” access. It has never been used a dorsal approach or a combined approach. We never used the peg that are provided with plaque Aptus. For the reconstruction of the anatomical planes, we proceeded to the careful repositioning of pronator quadratus muscle over the means of synthesis so to ensure adequate coverage of the flexors tendons. At the end of surgery was applied an elastic bandage, and in cases of extreme comminution of fracture or in highly unstable fractures, we preferred to place a protection valve in Scotchcast for 10 days. The correct position of the plates and screws was checked with fluoroscopy.

Results

All patients were monitored with the DASH score (disabilities of the shoulder, of the arm and of the hand), score that considers the ability to use the upper limb during the normal life, and the score Gartland-Werley modified, that considers clinical outcomes (as residual deformity, a subjective assessment, and arthrosic complications, an objective assessment). All patients were monitored with a mean follow-up of 28 months (min 5, max 39 months).

The average motility of the wrist (Figure 1) was: 60° in flexion (with a range from 40° to 90°) in patients treated with plates at fixed holes and 61° (range 41° - 90°) in the patients treated with plates with variable stability screws; extension at 61° (range 25° - 90°) in those cases treated with plates at fixed holes, 62° for those with variable angle screws; 40° in radio-ulnar deviation for those fixed and 43° for those variables (with a range from 15° to 55°). Pronation of the forearm was 85° (70° - 90°) and 80° (range 50° - 90°) in supination, for both.

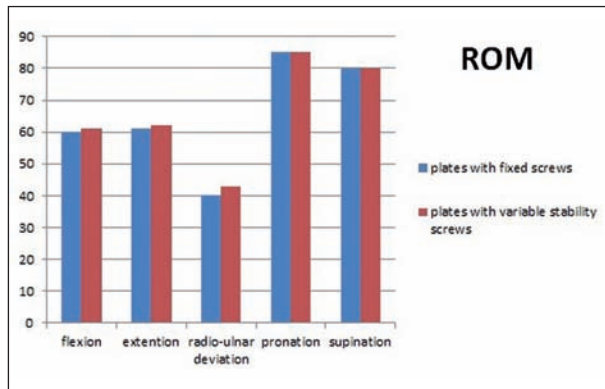


Figure 1. Comparison of medium postoperative ROM in the two different types of plates with angular stability

At the check-up the average volar inclination was of 8°, the radial inclination was 20° and the ulnar variance was 0.4 mm for both types of plates. The result of the score Gartland-Werley (Table 1) was excellent in 5 patients, good in 16, discreet in 4 and bad in 2 cases, with 84% of results excellent and good, obtained

Table 1. Results according to the Gartland and Werley score for the 2 plates used

Gartland – Wereley score		Result
fixed-holes plates	variable-holes plates	
2	2	Low
4	4	Medium
16	15	Good
5	6	Excellent

with the fixed holes plates (Figure 2) and excellent in 6 cases, good in 15, fair in 4 and poor in 2 cases in patients treated with multi-directional plate and screws (Figure 3).

So no difference according to the modified Gartland-Werley score has been noted towards the two types of plates. The average score DASH disability / symptom was 9.9 points. No patient complained of pain during pronation-supination and was not obbiettivabile any sign of instability in the distal radio-ular joint.

Discussion

The goal of surgery in fractures of distal radius is the same of all the articular fractures: reconstructing the normal articular surface and maintain mobility and function. Leung and other colleagues, in their randomized trial, that compares the stabilization with an external fixator with a volar plate, declare that the open reduction leads to better results (14, 15). After 24 months of follow-up, the results for the fixing unit were significantly better than those of external fixation according the Gartland-Werley score. Mehling and colleagues, using multidirectional plates and screws in their work concluded that the treatment of unstable fractures of the distal radius with this system ensures a stable internal fixation and allows a rapid functional

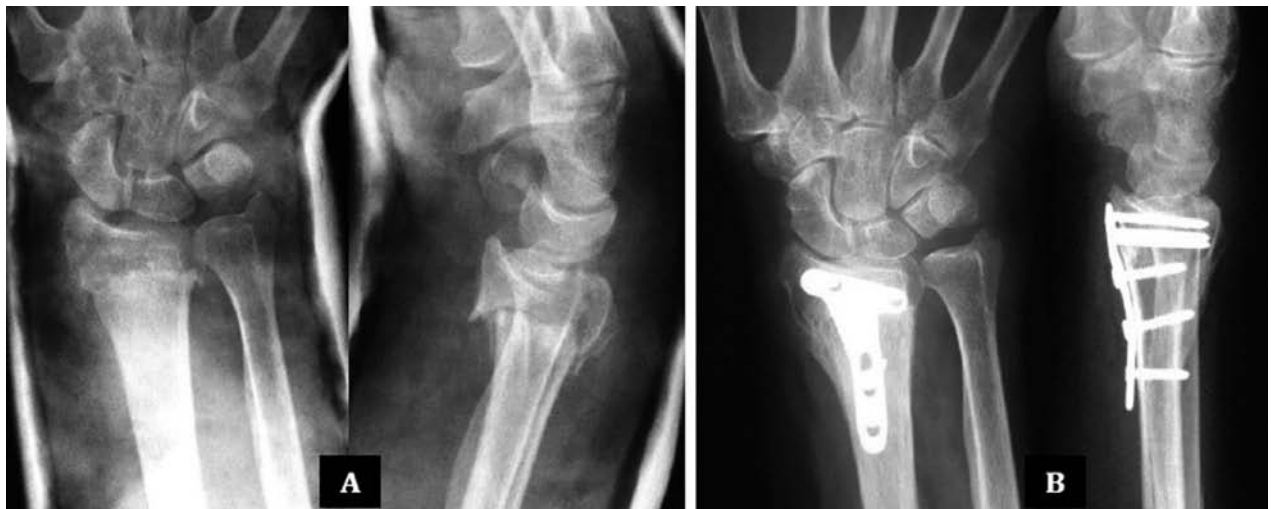

Figure 2. A: 56 years old woman with articular fracture of the distal radio. B: radiographic check 6 months after surgery: synthesis with angular stability plate Synthes LCP

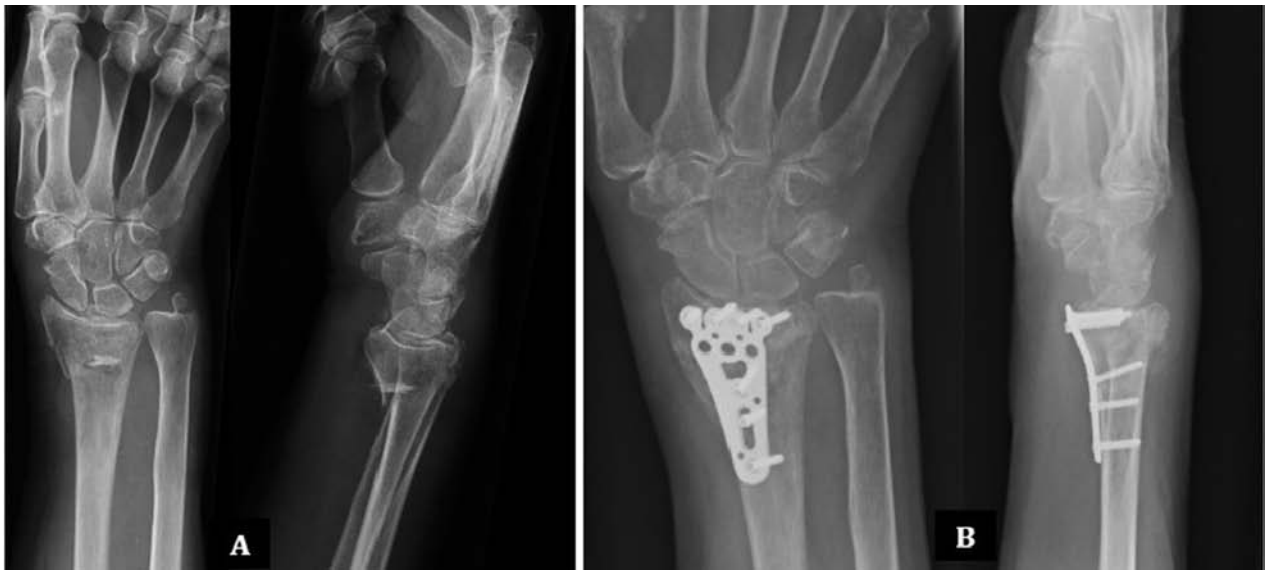

Figure 3. A: 65 years old woman with many fragments fracture of the distal radio. B: radiographic check 3 months after surgery: synthesis with angular stability plate Aptus Radius

recovery (16). Thanks to the fixation of the screw with multi-angle and two lines of cortical screws, characteristics in the plate with variable holes, you can get an optimum recovery of the articular surface. The fixing of articular central surface is guaranteed from the distal line, the dorsal subchondral support from the proximal line. implants with screws with angular stability have many advantages compared to previous systems without stability screws: distal screws, integral with the plate, allow, on one side, a stabilization of the implant against lateral movement and, on the other side, a greater resistance to the easing of the screws. Thus comes to be constituted a “shelf” support under the distal radial articular fractured surface.

According to our experience the design and the production of plates with the system of screws for multidirectional insertion has led to an improvement ensuring the stabilization of the fracture osteosynthesis of bone fragments otherwise unreachable with the screws in the direction obligated. The multi-direction is possible thanks to the particular conformation of the plate hole and screw heads, both characterized by three ridges that allow the locking of the heads in the hole of the plate with a variable direction. In fact, the Aptus Radius plates have these properties, with screws inserted at an angle of $\pm 15^\circ$ of rotation: this ensures an excellent and full angular stability. Clinical and

radiological results of osteosynthesis of distal radius fractures treated with plates with angular stability and possibility of insertion of screws in a multi-directional way are very interesting, but still similar to those of other plates stability. Surely the added value of systems with implant of the screws in a multi-directional way is the possibility to modify the insertion of any screw also in subsequent times, as in the case of initial malposition of the screw. A further characteristic of Aptus Radius plates is the possibility of insertion of a side screw for the synthesis of the radial styloid, thanks to the presence of an additional hole.

Conclusions

To sum, we believe that the use of angular-stability plates, positioned with volar access, on the basis of radiological and clinical results (subjective and objective) should be considered as the method of election in the treatment of all fractures of the distal epiphysis. Despite not having detected significant differences between the two types of plates with angular stability used for the treatment of wrist fractures in our study seemed that those with variable angle allow more technical possibilities, providing a stable synthesis of all the fragments, especially in those fractures that can be

defined as “unstable” for the degree of fragmentation, associated osteoporosis and the age of more than 75 years. Further studies seem to confirm this our impression, however, considering that the plates of Medartis are the most complete in the stabilization of fractures of the distal radius (17, 18). To remember that in each case, to obtain the best possible result, it is necessary that the reduction of the fracture and of little bone fragments occurs in a more anatomically possible way before performing the positioning of the plate and stabilization with screws. It is therefore considered that the osteosynthesis with angular stability plates and multi-directional screws is currently the “gold standard” for the treatment of meta-epiphyseal distal fractures of radius, allowing an anatomic reduction of the fracture and early mobilization of the joint.

References

- Cummings SR, Kelsey JL, Nevitt MC, O'Dowd KJ. Epidemiology of osteoporosis and osteoporotic fractures. *Epidemiol Rev* 1985; 7:178-208.
- Owen RA, Melton LJ 3rd, Johnson KA, Ilstrup DM, Riggs BL. Incidence of Colles' fracture in a North American community. *Am J Public Health* 1982; 72 (6):605-7.
- N, Verdonk R Anterior fracture displacement in Colles' fractures after Kapandji wiring in women over 59 years. *International Orthopaedics (SICOT)* 2007; 31:397-402.
- Penning D, Gausepohl T. External fixation of the wrist. *Injury* 1996; 27: 1-15.
- Luchetti R, Atzei A, Borelli PP. *Moderni Orientamenti nel Trattamento delle Fratture. Arto superiore ed arto inferiore. AIOD Sezione Italiana, OTC Sezione Italiana.* Springer Verlag Italia, Milano 2008 “Il Trattamento delle fratture del Polso con Sintesi Rigida”.
- Fernandez DL. Should anatomical reduction be pursued in distal radius fractures? *J Hand Surg [Br]* 2000; 25:523-7.
- Trumble T, Schmitt S, Vedder N. Factors affecting functional outcome of displaced intra-articular distal radius fractures. *J Hand Surg [Am]* 1994; 19:325-40.
- Ring D, Jupiter JB, Brennwald J, Buchler U, Hastings H. Prospective multicenter trial of plate for dorsal fixation of distal radius fractures. *J Hand Surg (Am)* 1997; 22:777-8.
- Leung F, Zhu L, Ho H, Lu WW, Chow SP. Palmar plate fixation of AO type C2 fracture of distal radius using a locking compression plate - a biomechanical study in a cadaveric model. *J Hand Surg [Br]* 2003; 28 (3):263-6.
- Ring D, Jupiter JB. Treatment of osteoporotic distal radius fractures. *Osteoporos Int* 2005; 16 (Suppl 2):S80-S84.
- Hunsaker FG, Cioffi DA, Amadio PC, Wright JG, Caughlin B. The American academy of orthopaedic surgeons outcomes instruments: normative values from the general population. *J Bone Joint Surg Am* 2002; 84 (2):208-15.
- Sakhaii M, Groenewold U, Klönz A, Reilmann H. Results after palmar plate-osteosynthesis with angularly stable Tplate in 100 distal radius fractures: a prospective study. *Unfallchirurg* 2003; 106 (4):272-80.
- Thielke KH, Wagner T, Bartsch S, Echtermeyer V. Angularly stable radius plate: progress in treatment of problematic distal radius fracture? *Chirurg* 2003; 74 (11):1057-63.
- Leung F, Tu YK, Chew WY, Chow SP. Comparison of external and percutaneous pin fixation with plate fixation for intra-articular distal radial fractures. A randomized study. *J Bone Joint Surg Am* 2008; 90 (1):16-22.
- Kwan K, Lau TW, Leung F. Operative treatment of distal radial fractures with locking plate system-a prospective study. *Int Orthop* 2011; 35 (3):389-94.
- Mehling I, Meier M, Schlör U, Krimmer H. Multidirectional palmar fixed-angle plate fixation for unstable distal radius fracture. *Handchir Mikrochir Plast Chir* 2007; 39 (1):29-33.
- Pichon H, Chergaoui A, Jager S, et al. Volar fixed angle plate LCP 3.5 for dorsally distal radius fracture. About 24 cases. *Rev Chir Orthop Reparatrice Appar Mot* 2008; 94 (2):152-9.
- Wright TW, Horodyski M, Smith DW. Functional outcome of unstable distal radius fractures: ORIF with a volar fixed-angle tine plate versus external fixation. *J Hand Surg [Am]* 2005; 30 (2):289-99.

Correspondence:

Roberto Valentini

Clinica Ortopedica e Traumatologica

Università degli Studi di Trieste

Azienda Ospedaliero Universitaria

“Ospedali Riuniti” di Trieste

Tel +390403994054

E-mail: rvalentini@units.it